

INTRODUCTION

THE TENNESSEE CRANIOFACIAL CENTER, part of the Erlanger Health System, is located in Chattanooga, Tennessee. The Center specializes in the evaluation and treatment of patients of all ages with craniofacial deformities. Its services cover a broad range of reconstructive operations for the treatment of deformities of the face and skull resulting from birth defects, tumors and trauma.

Dr. Larry A. Sargent, M.D. is the Medical Director of the Tennessee Craniofacial Center. He is a plastic and reconstructive surgeon specializing in craniofacial surgery and maxillofacial trauma. Before joining The Plastic Surgery Group, P.C., of Chattanooga, Dr. Sargent was Director of Craniofacial Surgery at Walter Reed Army Medical Center in Washington, D.C. He is a graduate of the Georgia Institute of Technology and Emory University School of Medicine. He completed his general surgery and plastic surgery training at The John Hopkins Hospital in Baltimore, Maryland and studied Craniofacial Surgery with Dr. Paul Tessier in Paris, France. Dr. Sargent is Professor and Chairman of the Department of Plastic Surgery at the University of Tennessee College of Medicine in Chattanooga, a Fellow of the American College of Surgeons, a Fellow of the American Academy of Pediatrics, and board certified in plastic surgery. He is an active member of the American Association of Plastic Surgeons, the American Society of Plastic and Reconstructive Surgeons, the American Society of Maxillofacial Surgeons, the American Association of Pediatric Plastic Surgeons, the American Cleft Palate-Craniofacial Association, the Plastic Surgery Research Council, and numerous regional societies.

The primary purpose of this book is to inform health care professionals, as well as parents, of the treatment that is available at the Tennessee Craniofacial Center for various types of craniofacial deformities. All patient examples shown in this book are the reconstructive work of Dr. Larry Sargent.

PREFACE

The Regional Craniofacial Center offers new hope and promise to many patients with facial deformities. The effective Craniofacial Center is one that has a dedicated, organized team of professionals of which each member has a genuine interest in evaluating and treating these types of deformities. The team approach remains our standard care for evaluation; however, the ultimate responsibility is with the Craniofacial Surgeon for choice of operation and the final success or failure dependent on his skill, experience and judgement. I feel, to continue to maintain this level of expertise, the Craniofacial Surgeon must devote the majority of his practice to the treatment of these types of problems. Adequate volumes of patients are necessary to maintain this expertise, which enhances safety and insures that optimum results are obtained. The specialized care and support facilities of a major medical center and children's hospital are also mandatory. I feel these are the criteria by which a center should be judged.



Dr. Larry A. Sargent

This book is organized like a monograph, using my patients to illustrate current surgical techniques that I use on a regular basis to treat various craniofacial deformities. It strongly reflects the comprehensive, coordinated treatment plan used at our center. In putting together this material, I had several goals in mind. First was to educate health professionals about the new and rapidly growing field of

Craniofacial Surgery. Second, was to provide a reference for patients and their families concerning treatments that are available and the type of results that might be expected. And finally, to reflect my own experience and philosophy as related to the treatment of these complex problems.

Providing informative material on craniofacial deformities, ultimately results in better patient care. As the primary care physician and the public become aware of what a center such as ours has to offer, expectations will and should continue to rise. It is not enough to correct a deformity; the ultimate goal should be to create an attractive face. This requires a thorough appreciation of facial aesthetics and the constant desire to strive toward perfection.

Craniofacial Surgery is a unique field in Plastic Surgery that at its best blends technical skill with artistic creativity. This type of facial reconstruction is often very hard and tiring work involving long operations, demanding a certain dedication from the surgeon. However, the treatment of these complex problems is both challenging and rewarding. Correcting a facial deformity can very often change a person's entire outlook on life, giving them a new self-esteem and a second chance. As this new field of surgery grows with the advances in technology and surgical techniques, there should always be that unfatigable desire that pushes one to continually strive for the best results possible for each patient. I feel this is and will continue to be my philosophy.

A handwritten signature in black ink that reads "Larry A. Sargent M.D." The signature is written in a cursive, flowing style.

Larry A. Sargent, M.D., F.A.C.S., F.A.A.P.
Medical Director, Tennessee Craniofacial Center
Professor and Chairman
Department of Plastic Surgery
University of Tennessee
Chattanooga, Tennessee

THE CRANIOFACIAL DEFORMITY

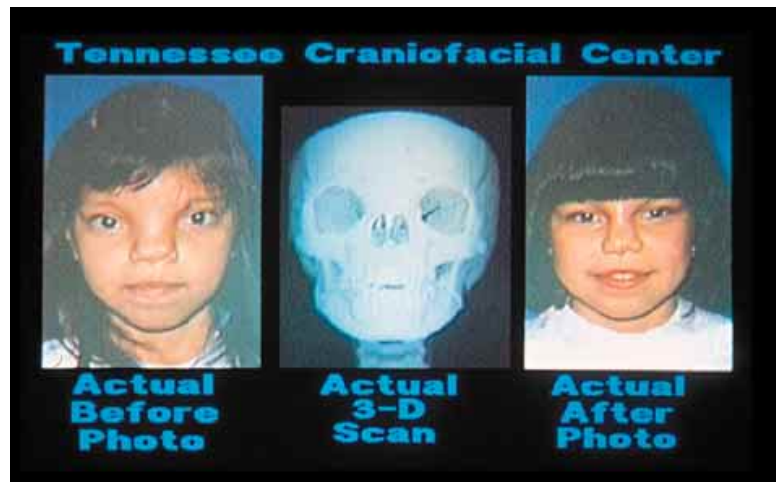D **agnosis:** Craniofacial deformities, or alterations in the natural form of the face or skull, can be congenital or acquired. For those patients born with craniofacial anomalies, the obstetrician or pediatrician is the initial point of contact for appropriate medical treatment. Referrals should be made to a craniofacial center as soon as it is acceptable for the child to be evaluated. Accurate diagnosis at an early age not only avoids unnecessary emotional distress for the parents and family, but it also minimizes potential future problems associated with the deformities by early correction. For those patients with acquired deformities as the result of trauma or tumor resection, referral to a craniofacial center may be desirable to help restore facial function and appearance.

Etiology: While the pattern of embryonic craniofacial development has been well defined through extensive research, very little is known about the etiology of many craniofacial anomalies. Some are known to be primarily genetic in nature, while others are thought to be caused by environmental factors. A combination of both environment and genetics may play a role in the etiology; however, most of the time the cause is unknown.

Craniofacial Team: The care of craniofacial patients requires the expertise of super-specialized professionals from many health care fields.



New advanced computer systems enable the surgeon to perform complex photographic and radiographic analysis that aid in treatment planning.



Computer images of patient with orbital hypertelorism.

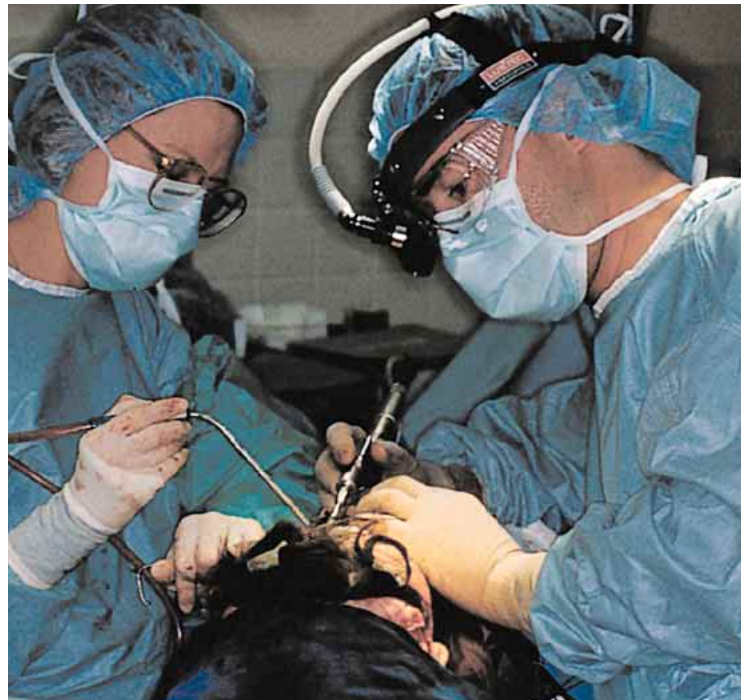Multidisciplinary teams have been established at regional centers to provide the comprehensive care necessary to adequately evaluate and treat craniofacial patients and their families. No single physician can possess the expertise to evaluate and treat all the abnormalities of these patients.

The benefits of the team approach are numerous. Members of the craniofacial team work together to ensure that the patient is evaluated and treated in a coordinated manner and that all of his needs, both physical and psychosocial, are met. The team combines the expertise of each specialist to provide a level of comprehensive care that cannot be provided by a single physician, no matter how reputable.

These multidisciplinary craniofacial teams are found at a few major medical centers across the U.S. where the resources are available to provide the safest and most advanced treatment for patients suffering from facial anomalies. Regionalization also ensures that each team has a large enough patient load to maintain the necessary expertise for proper treatment. The more procedures they perform together, the better the team becomes. Consequently, operative time is decreased, complications are minimized, and results are improved. Craniofacial procedures performed on an irregular or occasional basis invite disaster and are not in the best interest of the patient.

The craniofacial team is directed by the craniofacial surgeon, a plastic surgeon who has received additional training extensively in craniofacial techniques and whose practice is predominantly dedicated to the treatment of facial anomalies.

At the Tennessee Craniofacial Center, we adhere to Dr. Tessier's principles that, "Craniofacial surgery should be per-



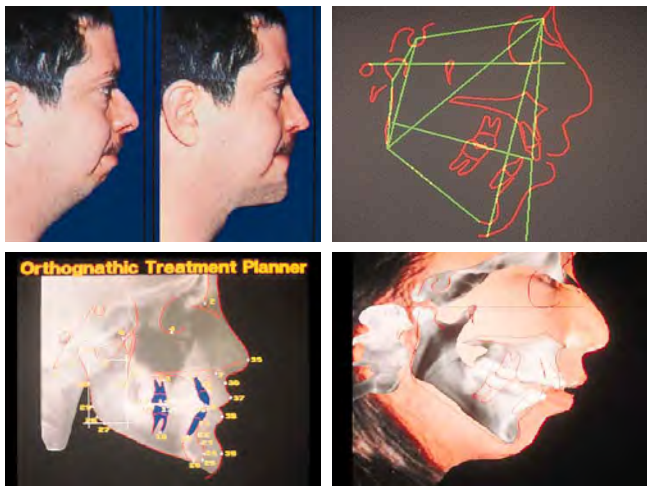
formed only if it is the main interest of that surgeon, and he has the support facilities of a major medical center."

Dr. Sargent is the medical director of the center and the leader of the team. Other disciplines represented on the team include:

- Neurosurgery
- Ophthalmology
- Pedodontics/Orthodontics
- Otolaryngology
- Anesthesiology
- Speech Pathology
- Pediatrics
- Audiology
- Psychology
- Social Service
- Genetics
- Nursing
- Prosthodontics
- Clinical Coordinator

Each patient referred to the Tennessee Craniofacial Center undergoes an evaluation by the principle members of the team, with additional team members called in depending upon the individual needs of that patient. A group conference is held following these evaluations to discuss each patient. The goal of the team is to diagnose the physical and psychosocial problems and formulate a coordinated, comprehensive treatment plan. This is followed by execution of the treatment plan at the appropriate time, longitudinal follow-up, and collection of data on the team's activities and results.

Surgical Plan Established: When Craniofacial Surgery is recommended as treatment for a specific anomaly, there are two distinct goals of this surgery. First, is the attempt to restore the patient to as near normal function as possible and to prevent future dysfunction. Secondly, surgery may be necessary to correct structural disfigurement in order to achieve optimal appearance. A patient suffering from a facial deformity may experience problems in dealing



Computer simulated images. Top left shows chin advancement with rhinoplasty.

with his disfigurement emotionally or socially. Often, improvements in appearance following craniofacial surgery can lead to increases in self-esteem, self-confidence and social acceptance. The psychological benefit of craniofacial surgery is an extremely important goal of the surgery.

Recent Advancements: A number of advances have been made in surgical technique and technology as applied to craniofacial surgery. Calvarial bone grafts for the most part have replaced rib and hip grafts. These outer table split grafts are available in an assortment of sizes and shapes with less painful donor sites and less resorption compared to rib or hip bone.

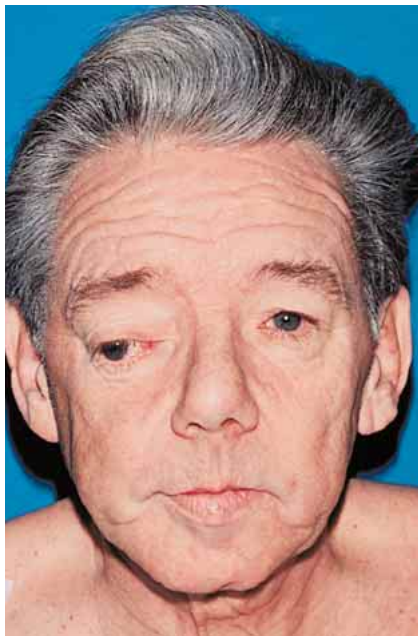Tremendous radiological advances have been made in the past ten years that have improved preoperative analysis of craniofacial deformities. The use of two- and three-dimensional CT scans has drastically enhanced our ability to analyze these complex deformities. Computer analysis of photographs and radiographs is also available and can provide further information for preoperative planning.

Another major advancement has been the application of rigid skeletal fixation to craniofacial surgery. The new techniques of rigid skeletal fixation combined with wide exposure have allowed the craniofacial surgeon to obtain much better stability and eliminate intermaxillary fixation in most cases. This technique offers significant advantages, particularly in children. It has improved our overall quality of results as well as decreasing morbidity.

Follow-Up Care: Treatment of craniofacial problems does not end with surgical restoration, but continues for many years. This follow-up should be conducted by the craniofacial team in order to maintain a continuity of care that assures the patient the best long term outcome. As a child grows and develops, asymmetries may result if areas of the face fail to develop equally; therefore, a child's growth and development must be routinely followed. Sometimes it may be necessary to repair these asymmetries surgically. Often, major craniofacial deformities require multiple, staged procedures performed at different ages. Once treatment is initiated, it is important that follow-up care continues.

ENOPHTHALMOS

Enophthalmos can be defined as the relative recession (backward or downward displacement) of the globe into the bony orbit. The three basic structures that determine globe position are the bony orbits, the ligament system and the orbital fat. Displacement of the orbital walls with enlargement of the bony orbit may be the major components in the production of enophthalmos in orbital fractures. Post-traumatic enophthalmos is frequently seen and is the result of disruption of the bony orbit and ligament system with displacement of the orbital soft tissue. This presents clinically as a sunken appearance to the eye with pseudoptosis and deepening of the supratarsal fold. Treatment involves reconstruction of the bony orbit with restoration of bony orbital volume and repositioning of the globe. The use of craniofacial techniques allows this to be accomplished with minimal complications.

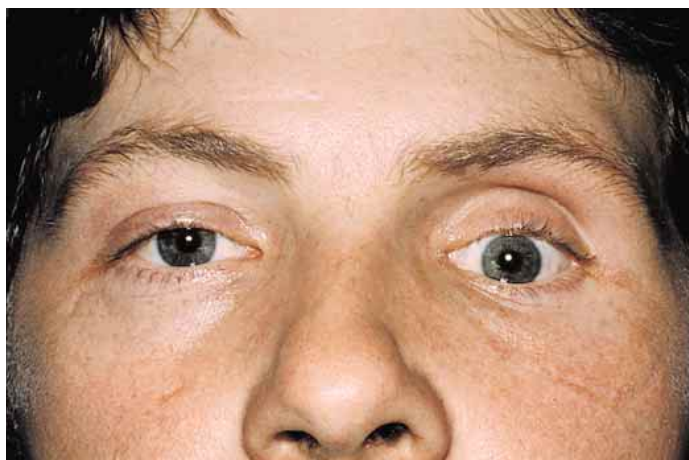

This patient has severe displacement of the right eye caused by tumor.

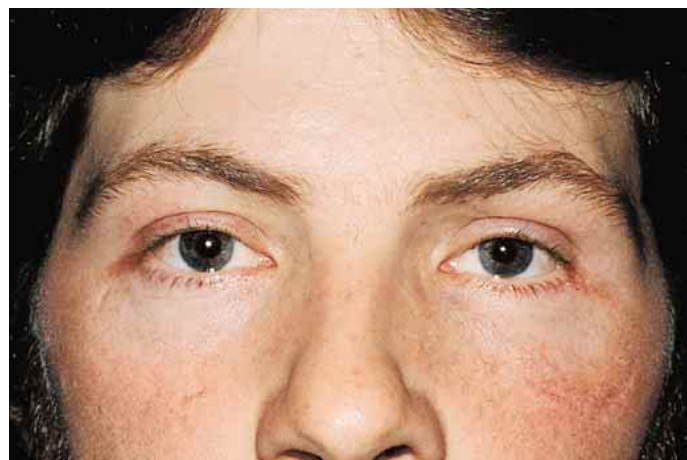

Postoperative result after tumor resection and orbital reconstruction with repositioning of the right eye.

Enophthalmos

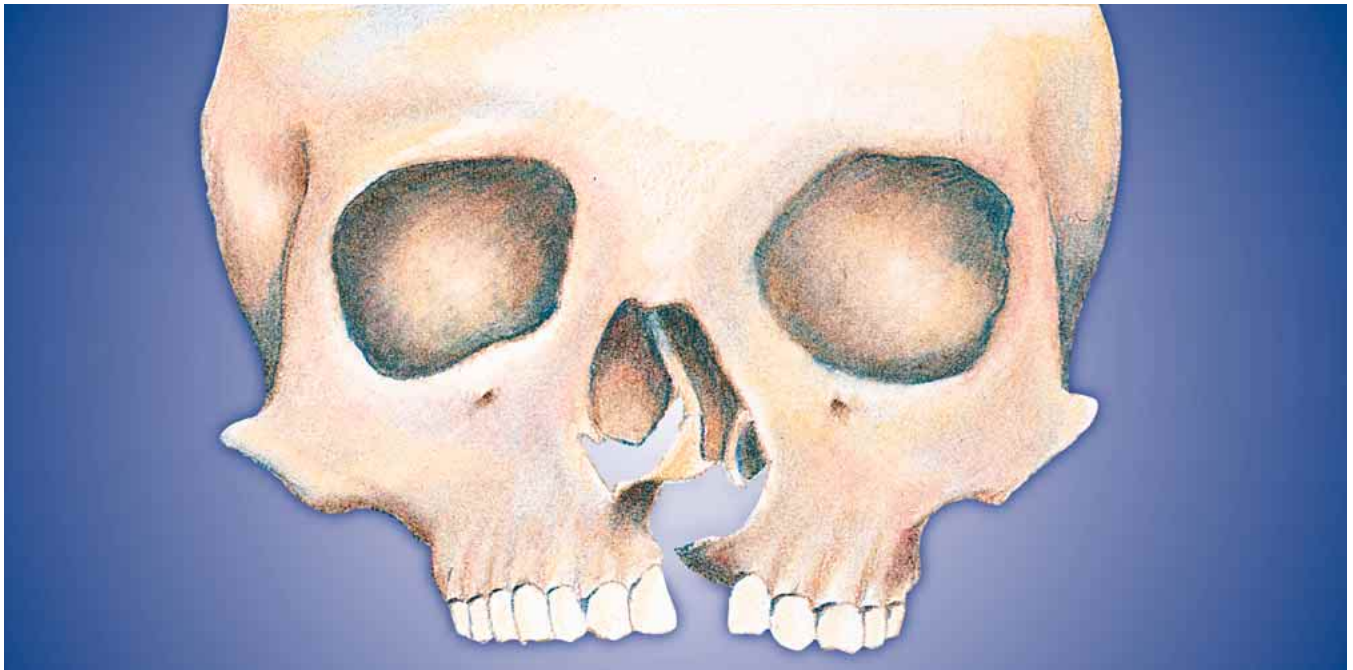


This patient has traumatic enophthalmos of the left orbit. Note sunken-in appearance of the left eye due to unrepaired orbital fracture.



Postoperative result after orbital reconstruction and repositioning of eye.

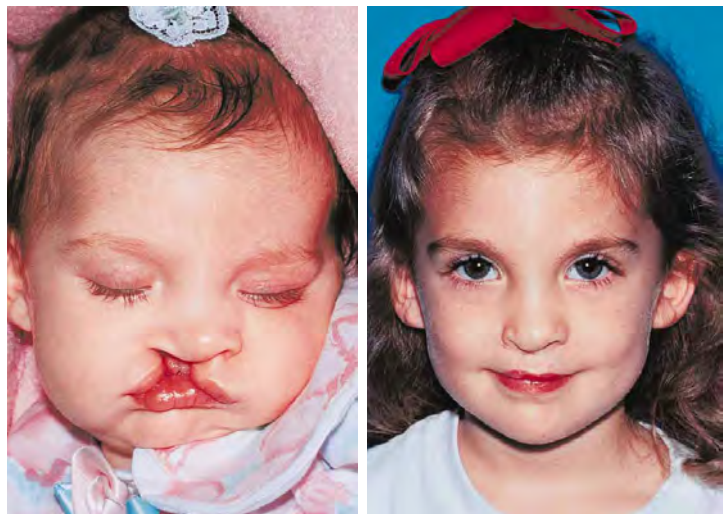Clefts of the Lip and Palate



CLEFTS OF THE LIP AND PALATE

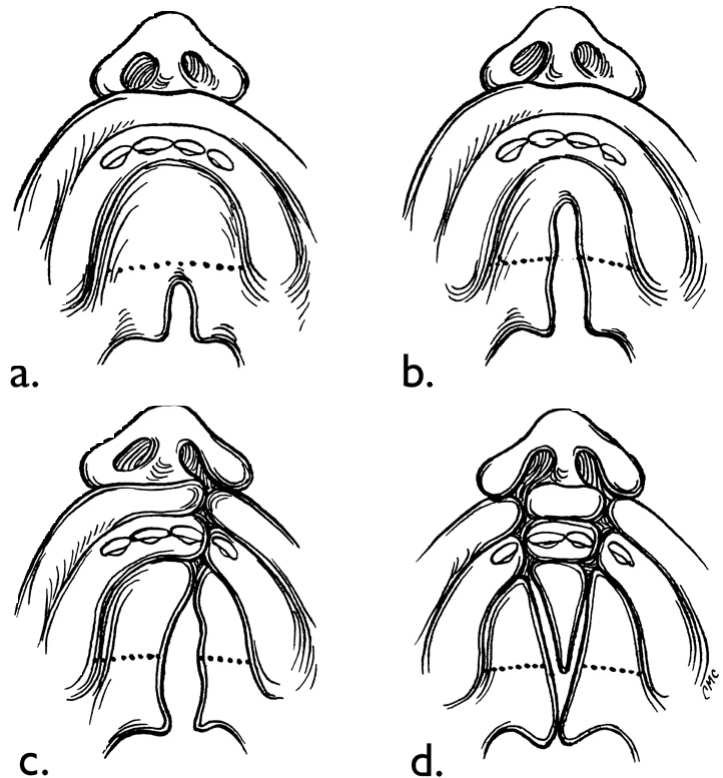
Each year approximately 227,500 or 7 percent of births in the United States are affected by birth defects of the head and face. The most common of these are clefts of the lip and palate which occur once in every 700 births. Clefts occur in infants of all races with a 2:1 male to female ratio. The incidence of clefts is highest in the Asian population and lowest in African Americans. Of all orofacial clefts, 21 percent present as cleft lip only (unilateral and bilateral), 46 percent present as cleft lip and palate, while the remaining 33 percent have cleft palate alone.

What is a cleft? A cleft is a division or separation of parts of the lip or roof of the mouth that is formed during the early months of development of the unborn child. All of the parts of the lip or roof of the mouth are present; they simply failed to fuse in a normal way. Surgical intervention is necessary to align the parts and join them. Often the bones of upper jaw (maxilla) and/or the upper gum are affected. A cleft lip can be incomplete with a variable degree of notching of the lip, or complete, extending through the lip and into the nose.



Preoperative

Postoperative



Variations in clefts of the palate.

A). Cleft of soft palate only. **B).** Incomplete cleft of soft and hard palate. **C).** Complete unilateral cleft palate. **D).** Complete bilateral cleft palate.

Clefts of the palate can vary in severity. Some may involve just the uvula and the soft palate. These are incomplete clefts of the palate. Others extend the length of the palate and are complete clefts. They may involve one side of the palate (unilateral) or both sides (bilateral).

Etiology: The exact cause of lip and palatal clefting is not known, but most experts feel that it is due to both genetic and environmental factors. Clefts are associated with abnormalities in the genes which may be a result of inheritance or from a spontaneous mutation during fetal development. We recommend genetics counseling to discuss causes of the cleft and the recurrence risk factors.

Team Assessment: Children born with clefts should be carefully assessed by the craniofacial team in order to detect potentially serious abnormalities that can be associated with clefting. There are over 150 syndromes that include cleft lip or palate in their differential diagnosis. Generally, clefting is the only congenital abnormality that the child has, but nearly 15 percent of all cleft lip or palate patients present clinically with multiple problems.

The team concept allows a systematic, comprehensive treatment plan to be developed and allows the team members to work together to identify problems before they become significant. The most common specialties involved in the care of a child with a cleft are: plastic surgery, otolaryngology, dentistry, audiology, speech pathology, genetics and pediatrics. Once a complete assessment of the child with a cleft has been performed, a plan for treatment can be outlined.

FEEDING AN INFANT WITH A CLEFT

Feeding an infant is important not only in providing nourishment, it also provides an intimacy and closeness for both the parent and the child. Infants with a cleft of the lip or of the soft palate seldom have problems with feeding either by bottle or breast.

In babies with clefts of the hard palate, the opening in the roof of the mouth often causes difficulty in creating adequate pressure on the nipple, thus creating an inability to suck well enough to get adequate nourishment. Feeding the infant takes patience and practice. At our center we recommend the use of a soft squeezable plastic bottle like Mead Johnson with an orthodontic nipple such as Nuk. You can increase the flow by gently squeezing or putting pressure on the bottle. It is important to feed the infant before he/she becomes too hungry. Position the infant in an upright position with the head tilted back slightly. This position allows the milk to flow down into the throat and less into the nose. Infants with clefts do swallow more air and need to be burped more frequently. At first, it may take extra time, but this will steadily decrease. Feeding time of the newborn varies from 20-30 minutes. When feeding takes longer than 45 minutes, the infant may be burning up calories necessary to gain weight. If this occurs the feeding consultant should be contacted to help with the feeding technique.

Breast feeding the newborn with a cleft of the hard palate is often unsuccessful. Generally the infant cannot produce enough negative pressure to obtain ample breast milk to provide adequate nourishment. Using a breast pump to extract the milk and feeding the infant breast milk from a squeezable bottle is recommended.

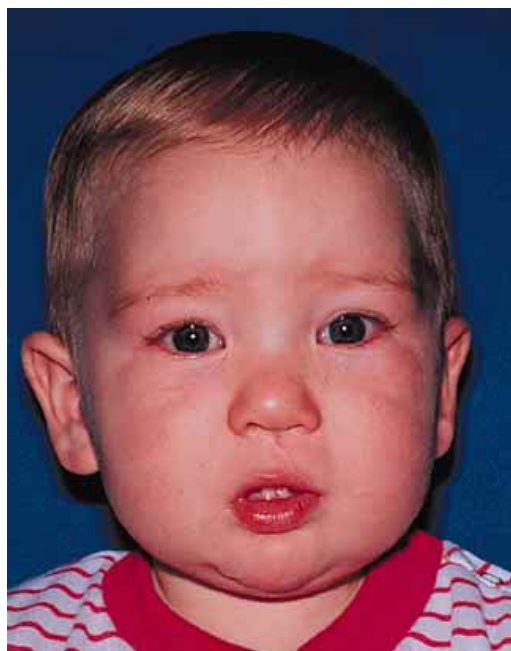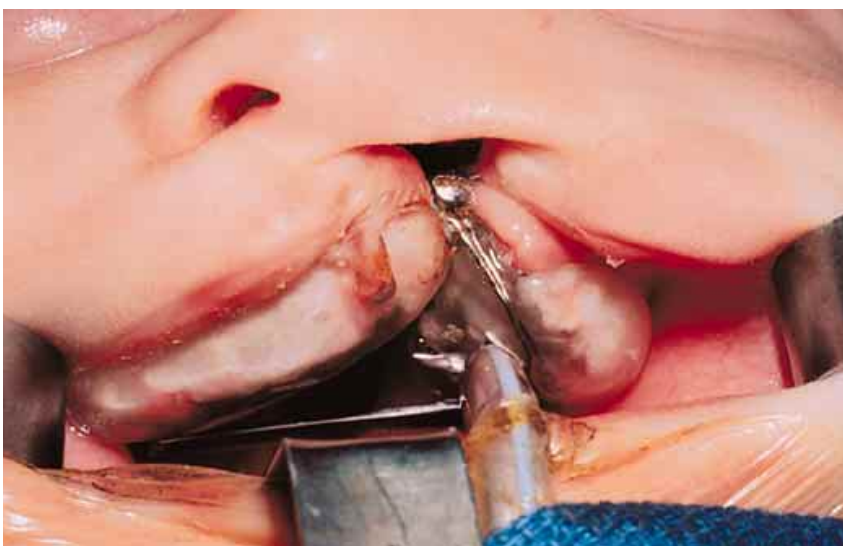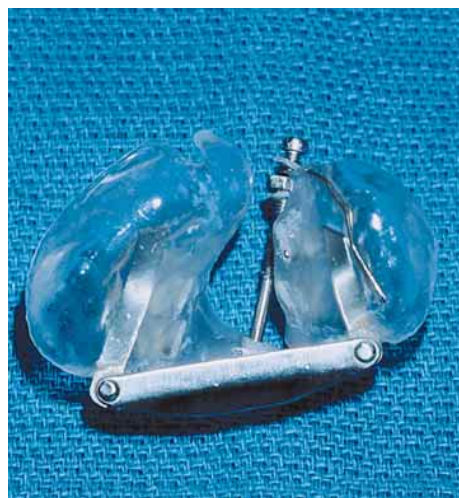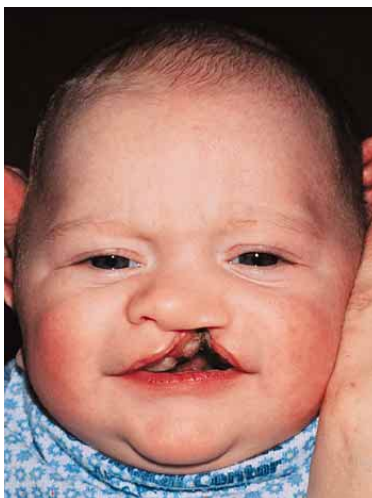SURGERY

Cleft Lip Repair - The objective in repairing the lip is to close the cleft to create a pleasing face that will develop normally with minimal scarring. Closure of the lip is performed by the plastic surgeon when the baby is approximately 3 months of age and weighs at least 10 pounds. When there is involvement of the alveolus and palate, an orthodontic appliance may be placed in the maxillary segments as the first procedure. This is performed by the team dentist as an outpatient surgical procedure. The appliance is used to align the alveolus so that it can be repaired (gingivoperiosteoplasty) at the time of the lip repair or lip adhesion. This improves nasal support on the cleft side and creates a tunnel that should develop bone, closing the cleft. If the alveolus is not closed in infancy, then the alveolar ridges will be orthodontically aligned and a bone graft performed to stabilize the maxilla (5-10 years of age). Correction of the nasal deformity is usually performed at the time of lip repair. Additional procedures may be necessary to enhance the appearance of either the lip or nose.

Photos to the right:

A unilateral cleft lip is shown. A custom fitted Latham appliance has been fabricated and placed to rotate alveolar segments together. Postoperative result is shown after repair of alveolar cleft and lip.

Unilateral Cleft Lip with Custom Latham



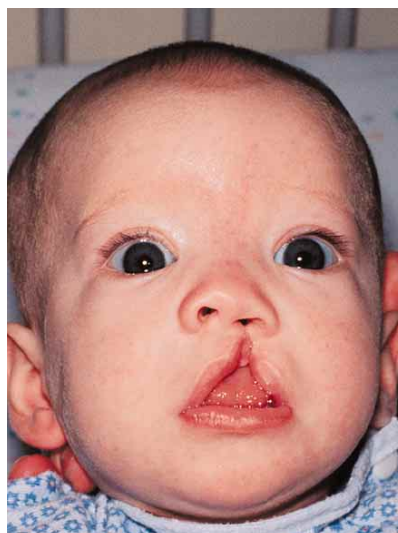
UNILATERAL CLEFT LIP REPAIR

A unilateral cleft lip results from failure of the union of the maxillary and median nasal processes, thus creating a split or cleft in the lip on either the left or right side. It may be just a notching of the lip or extend completely through the lip into the nose and palate. A number of procedures have been described to repair the unilateral cleft lip. The procedure used at our Center is the Millard rotation advancement technique. The procedure is designed to reconstruct the lip, muscle, oral mucosa, and to reposition the nose. It is performed under general anesthesia with surgery lasting 2-3 hours and a hospital stay of 2-4 days. Special considerations are necessary for feeding and positioning the infant postoperatively. The baby's elbows are restrained from bending to prevent him/her from disrupting the nose or lip. Positioning the child in an infant seat keeps him/her from rolling over and injuring the lip or nose. Pacifiers and nipples are not allowed. The baby is fed with a special syringe feeder with a soft tube. It takes approximately 3 weeks for the wound to gain enough strength to discontinue the above precautions. The lip scar is initially red and swollen, but it begins to mature and improve in appearance in six-twelve months.

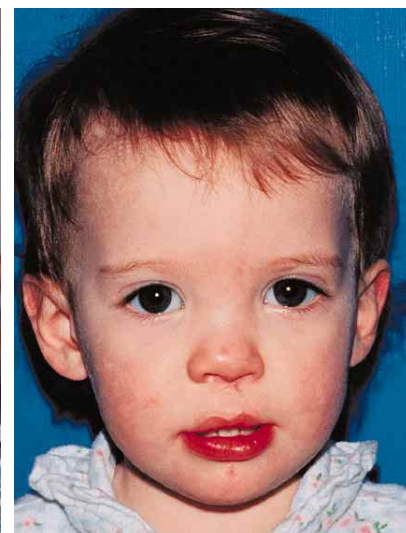Photos to the right:

Photos of infants who underwent repair of unilateral cleft lip with rotation advancement technique.

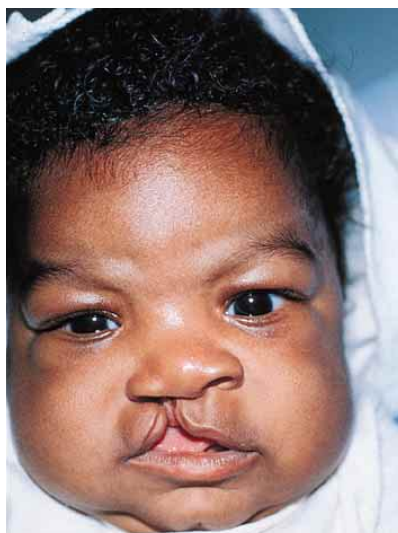Unilateral Cleft Lip



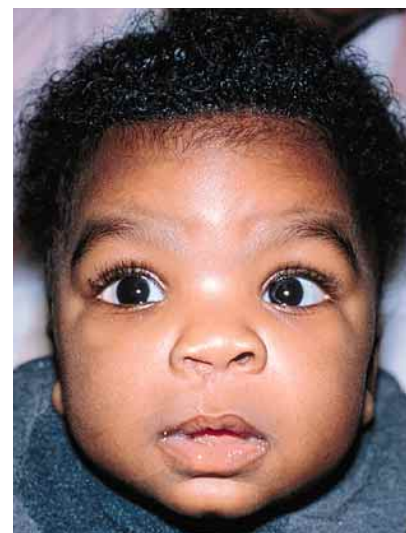Preoperative



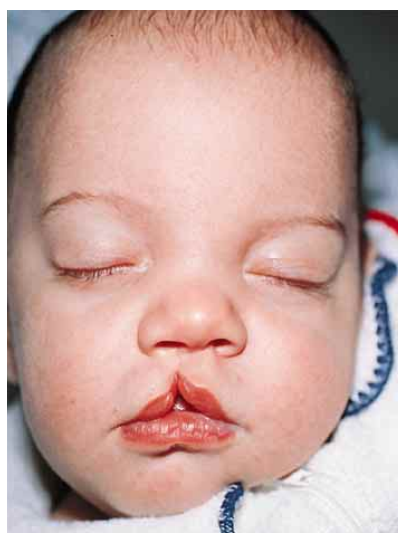Postoperative



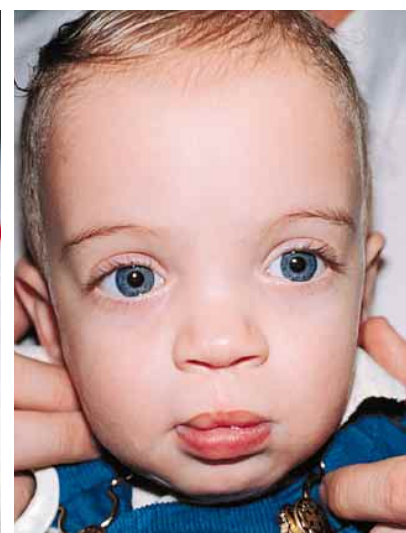Preoperative



Postoperative



Preoperative

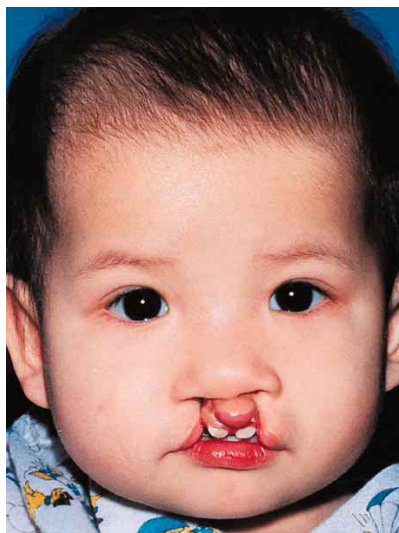

Postoperative

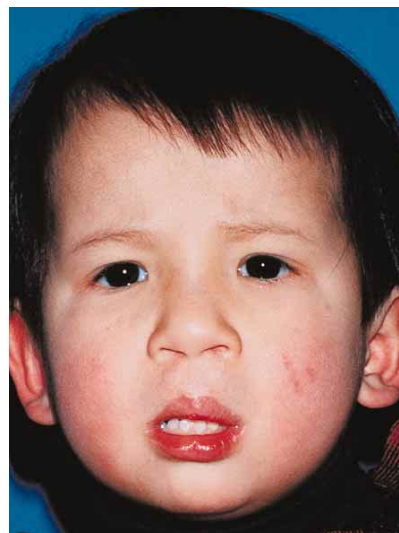BILATERAL CLEFT LIP

The bilateral cleft lip involves separation of the lip along philtral lines, isolating the central segment (prolabium). Fifteen percent of children born with cleft lips have bilateral clefts. The associated nasal deformity is usually more severe than the unilateral cleft due to a very short columella and flaring of both nostrils. Surgical correction of the bilateral cleft lip is usually performed in one procedure at three months of age; however, the procedure may be staged, closing one cleft at a time. Rotation of the nostrils to a more normal position is performed in the first procedure. A second procedure is performed by 2-3 years of age to lengthen the columella. Patients with complete bilateral cleft lips frequently require additional procedures to enhance the appearance of the lip and nose. Performed under general anesthesia, the operation generally requires 2-3 hours. A hospital stay of 2-4 days should be expected. Feeding, positioning and elbow restraints are the same as those for repair of the unilateral cleft lip.

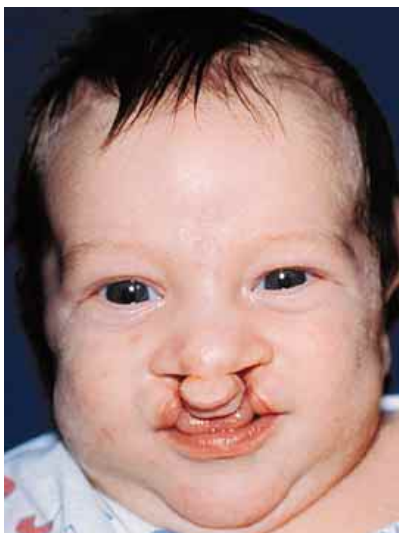Bilateral Cleft Lip



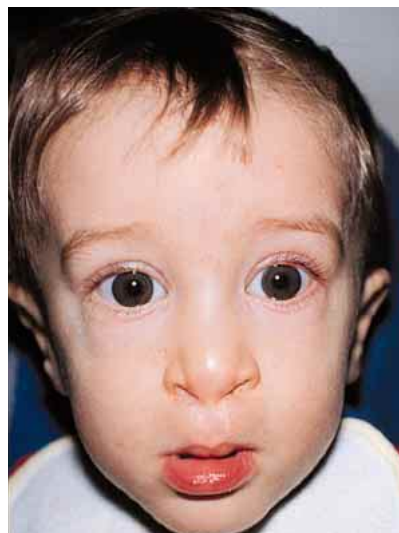Preoperative



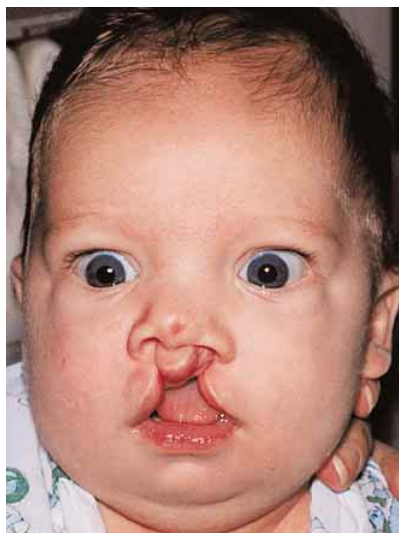Postoperative



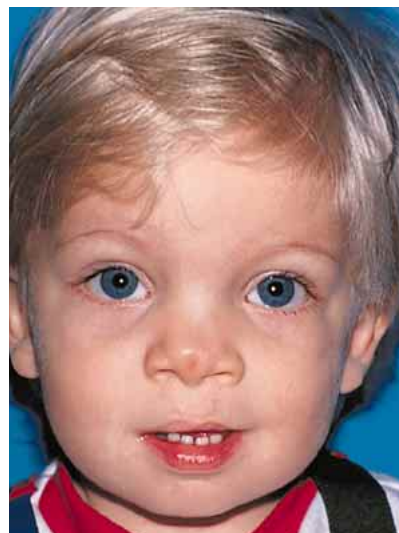Preoperative



Postoperative



Preoperative



Postoperative

Photos to the right:

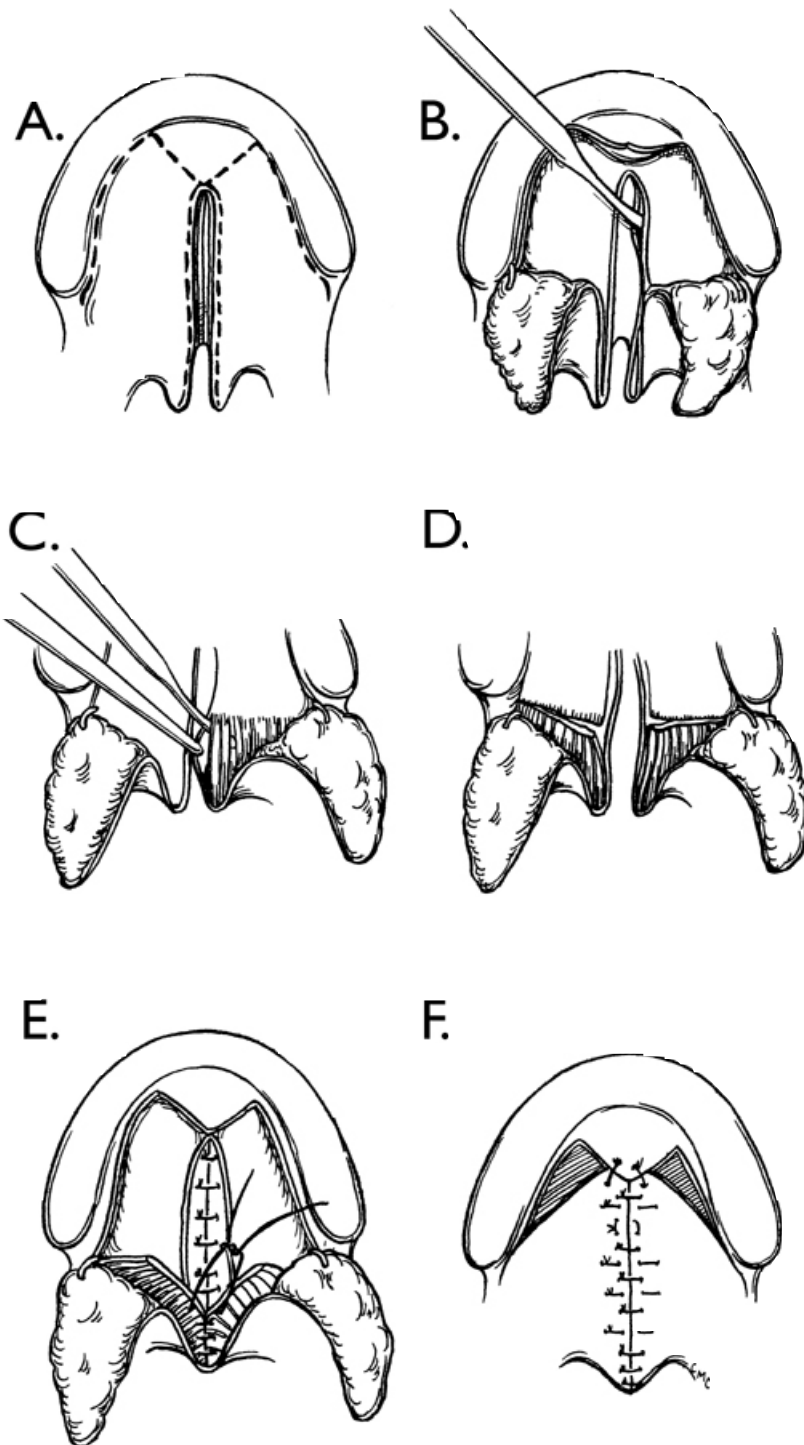
Photos of infants who underwent one stage repair of bilateral cleft lip.

CLEFT PALATE REPAIR

The objective of cleft palate surgery is to close the palate to restore normal function to eating and drinking and to enhance the development of normal speech.

Clefts of the palate can occur as isolated deformities or in combination with a cleft of the lip. Cleft palates result from failure of fusion of the embryonic facial processes resulting in a fissure through the palate. This may be complete (extending through the hard and soft palates) or any degree of incomplete (partial cleft). The palate forms the roof of the oral cavity and the floor of the nose; thus, a cleft causes a free communication between these two cavities. As a result, treatment of palatal clefts is complex because of potential problems with feeding, speech, middle ear infections, occlusion and jaw alignment.

Surgical treatment of the cleft palate is best accomplished in one surgical procedure before the child reaches 12-14 months of age. The cleft palate is surgically closed by elevating two muscoperiosteal flaps. The levator muscles are elevated, redirected and repaired; and a three layer closure of nasal mucosa, muscle and oral mucosa accomplished. Surgery under general anesthesia usually lasts about 2 hours. Special precautions as those after the repair of the cleft lip are necessary for 2-3 weeks. We prefer that the child be weaned from the bottle and pacifier prior to the palatal repair. No hard or crunchy foods are allowed for 3 weeks post operatively.



Cleft Palate Repair:

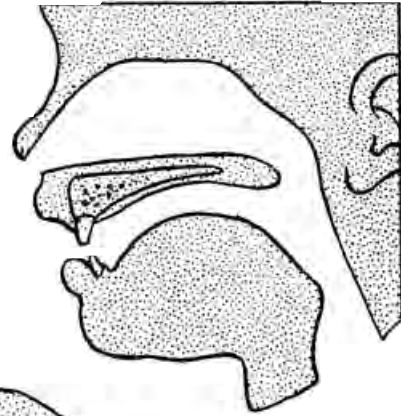
Closure of cleft palate with pushback palatoplasty. A). Two mucoperiosteal flaps are outlined. B). Flaps are elevated off the hard palate. C,D). The abnormal levator muscle insertion to the hard palate is identified and cut free. E). The nasal lining is closed as a separate layer and the levator muscle reapproximated. F). The palatal mucoperiosteal flaps are closed in a V-Y fashion.

PHARYNGEAL FLAP

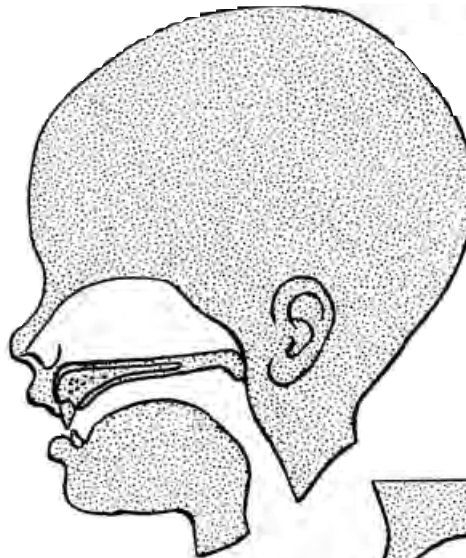
Approximately 70-80 percent of all cleft palate patients will develop velopharyngeal competence after palate closure and thus the potential for normal speech. The remaining 20-30 percent will require speech therapy and/or an additional surgical procedure called a pharyngeal flap. To correct persistent hypernasal speech, this procedure involves raising a flap of tissue from the posterior pharynx and inserting it into the soft palate. This flap is indicated when the repaired palate is too short or the muscles do not function properly, causing a persistent hypernasal speech. The procedure is performed usually after the age of 4-5 when speech and velopharyngeal competence can be thoroughly assessed and before the child begins school.

LATE CLEFT TREATMENT

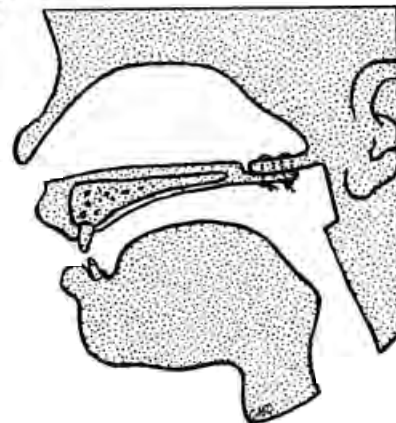
The Craniofacial Center can also help those individuals that have grown up without access to a comprehensive, coordinated team approach. For adults with speech problems, the previously mentioned pharyngeal flap, combined with an intensive regimen of speech therapy, can produce significant improvements. Orthognathic surgery is available to patients with deformities of the jaws to improve their appearance as well as to correct dental occlusion. For soft tissue revision of a severely tightened or notched upper lip, an Abbe flap is the surgical option. This procedure is usually indicated in bilateral cleft patients who have a short or deficient columella and a tightened upper lip. This operation



Inadequate Closure



Adequate Closure



Corrected Closure

Pharyngeal Flap:

The pharyngeal flap procedure for hypernasal speech. A superiorly based flap of tissue is raised from the posterior pharynx and sutured to the soft palate thereby decreasing the amount of air through the nose. Lateral ports or holes are left so that the nose will not be obstructed.

can add fullness to the upper lip as well as lengthen the columella. A number of additional surgical therapies, similar to the ones described, are available to patients who desire further improvements.

HEARING

Children with cleft palate have a higher incidence of hearing problems. The Eustachian tube connects the middle ear space to the back of the throat. It normally opens and shuts to relieve pressure that builds up behind the ear drum. If the Eustachian tube does not open, then the pressure increases until mucus or “fluid” accumulates behind the eardrum. The muscles responsible for opening the Eustachian tube do not function as well in children with cleft palates resulting in more frequent problems with fluid, otitis media and ear infections which can be very painful. Because of this problem, it is important to have the infant’s hearing tested during the first few months. If hearing is impaired by fluid buildup or unequal pressure, it may be necessary for the otolaryngologist to place pressure equalizing (PE) tubes. Tubes are often placed at the time of the lip or palate surgery. It is crucial that children with cleft palates have regular hearing tests to monitor middle ear problems that could alter the development of normal hearing as well as speech. As the child grows, the frequency of ear infections and fluid in the ears seem to decrease.

SPEECH

Speech development in children with cleft lip only should be normal. The unrepaired cleft palate causes speech to sound hypernasal because air passes through the nose while talking. Most speech sounds require the nose to be closed off from the mouth. Cleft palate surgery usually remedies the problem, but speech therapy is still recommended. Approximately 20-30 percent of cleft palate

patients will have velopharyngeal incompetence or hypernasal speech after surgery, and may require a pharyngeal flap to correct it around the age of 4-5 years.

DENTAL

Clefts of the palate generally have an effect on dental development. In the area of the cleft, teeth often erupt in a crooked position with extra teeth or missing teeth being common in the cleft area. Radiographs are often taken to determine the exact position of the teeth. Dental problems have an effect on speech, chewing, appearance and frequently require orthodontic treatment. Early orthodontic intervention may require a palatal expansion device with further alignment of the dental arches. Later treatment after the primary teeth have erupted can begin at 10-12 years of age. Orthognathic surgery may be indicated if a malocclusion develops due to abnormal growth of the maxilla.

PIERRE ROBIN SYNDROME

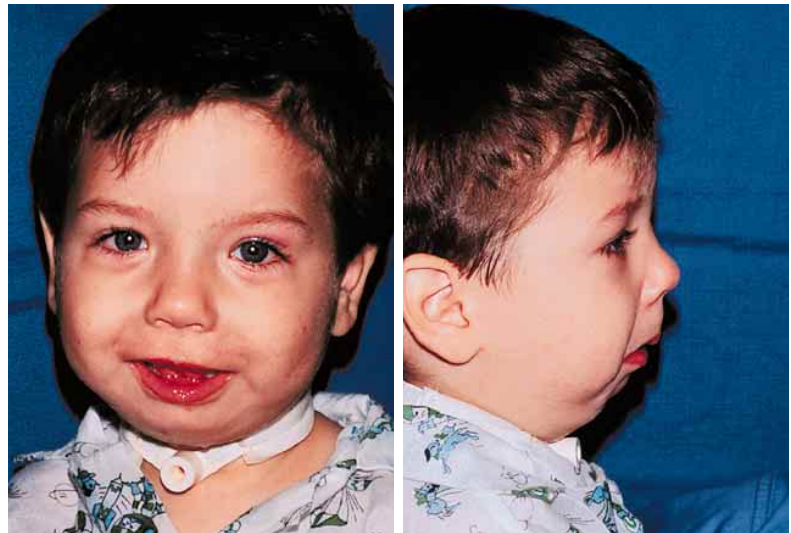This syndrome was described in 1923 by Pierre Robin in which he described airway obstruction associated with glossoptosis and hypoplasia of the mandible. Today this syndrome is characterized by retrognathia or micrognathia, glossoptosis, and airway obstruction. An incomplete cleft of the palate is associated with the syndrome in approximately 50% of these patients.

In patients with micrognathia (small jaw) or retrognathia, the chin is posteriorly displaced causing the tongue to fall backward toward the posterior pharyngeal wall. This results in obstruction of the airway on inspiration. Crying or straining by these children can often keep the airway open. However, when the child relaxes or falls asleep, airway obstruction occurs. Due to these respiratory problems, feeding may become very difficult. This can lead to

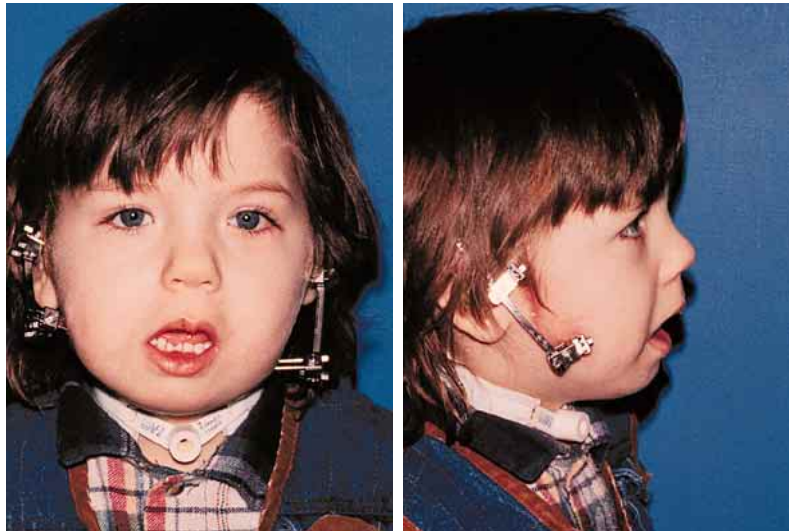a sequence of events: glossoptosis, airway obstruction, crying or straining with increased energy expenditure and decreased oral intake. This vicious cycle of events if untreated can lead to exhaustion, cardiac failure, and ultimately death.

Treatment of this syndrome can be divided into conservative therapy versus surgical intervention. The majority of these patients can be managed by placing the infant in the prone position until adequate growth of the jaw occurs. This causes the jaw and the tongue to fall forward opening the airway. If this type of treatment fails the infant should then be considered for a tongue-lip adhesion (a procedure to pull the tongue forward) or a tracheostomy.

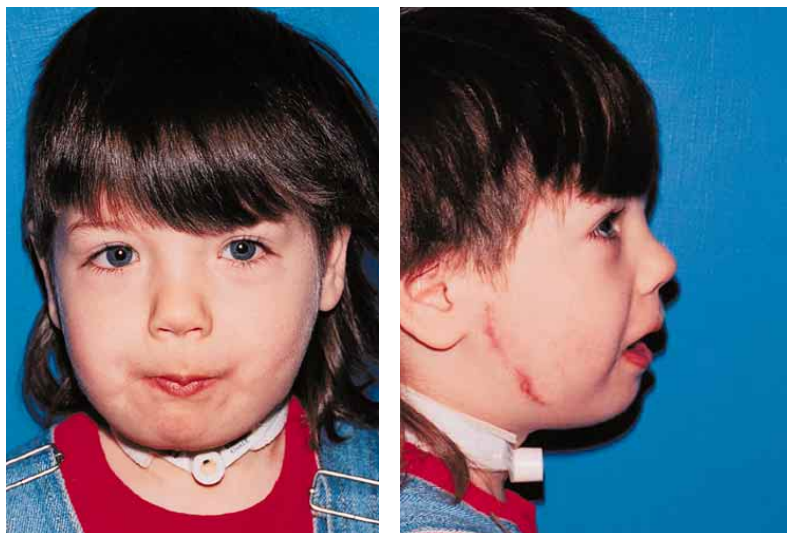In children with severe underdevelopment of the lower jaw, a new technique called mandibular bone expansion is now available. This technique also called distraction osteogenesis involves placement of an expansion device that is turned daily to slowly lengthen the jaw. An external incision is required to make a surgical cut through the jaw bone with placement of pins that are secured to the expansion device. Once the amount of expansion of the bone has been obtained (4-5 weeks) the device is then kept in place until the bone gap heals with new bone formation (8 weeks). This technique can be performed at a very early age which is a significant advantage over the traditional technique of lower jaw lengthening.



Two year old with Pierre Robin and severe airway obstruction requiring tracheostomy.

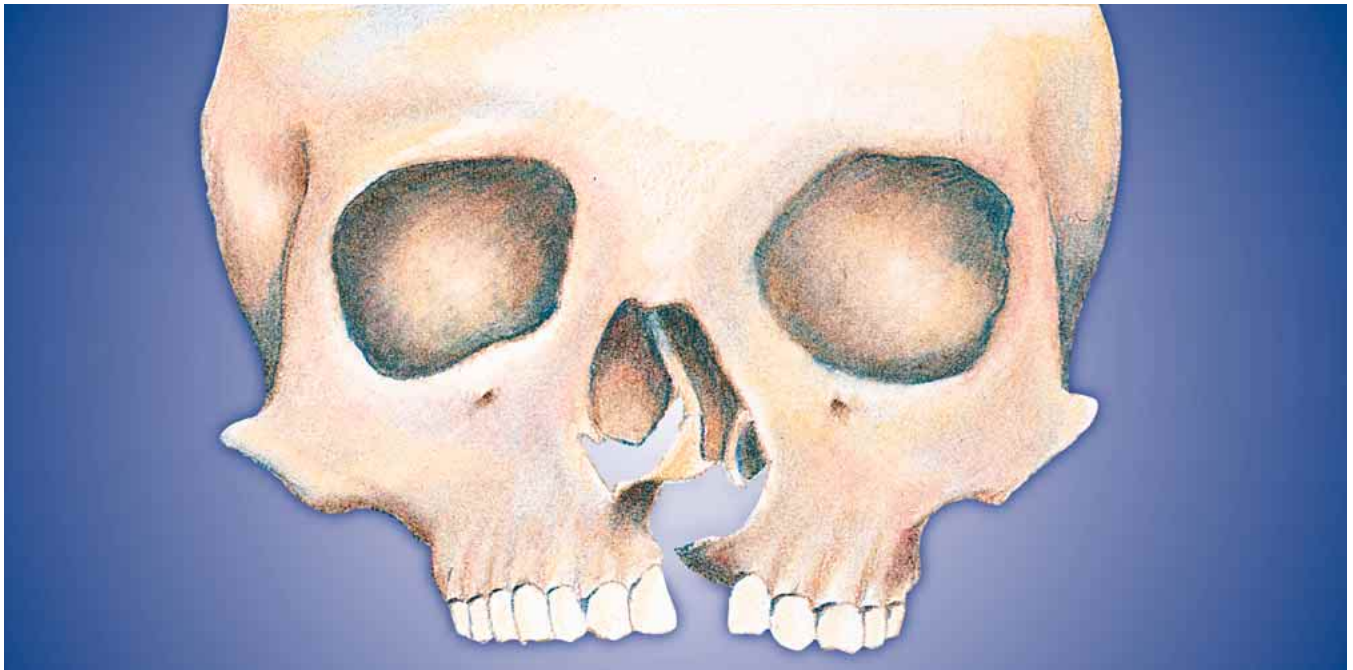


Bilateral mandibular lengthening devices surgically placed with lengthening in progress.



Results after removal of lengthening devices. Patient now ready for removal/closure of tracheostomy.

Clefts of the Lip and Palate



CLEFTS OF THE LIP AND PALATE

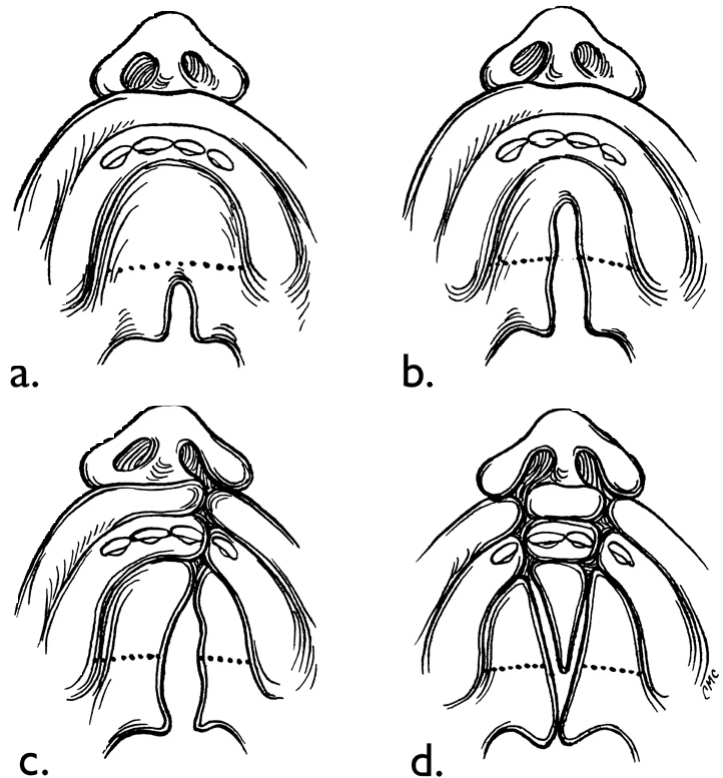
Each year approximately 227,500 or 7 percent of births in the United States are affected by birth defects of the head and face. The most common of these are clefts of the lip and palate which occur once in every 700 births. Clefts occur in infants of all races with a 2:1 male to female ratio. The incidence of clefts is highest in the Asian population and lowest in African Americans. Of all orofacial clefts, 21 percent present as cleft lip only (unilateral and bilateral), 46 percent present as cleft lip and palate, while the remaining 33 percent have cleft palate alone.

What is a cleft? A cleft is a division or separation of parts of the lip or roof of the mouth that is formed during the early months of development of the unborn child. All of the parts of the lip or roof of the mouth are present; they simply failed to fuse in a normal way. Surgical intervention is necessary to align the parts and join them. Often the bones of upper jaw (maxilla) and/or the upper gum are affected. A cleft lip can be incomplete with a variable degree of notching of the lip, or complete, extending through the lip and into the nose.



Preoperative

Postoperative



Variations in clefts of the palate.

A). Cleft of soft palate only. **B).** Incomplete cleft of soft and hard palate. **C).** Complete unilateral cleft palate. **D).** Complete bilateral cleft palate.

Clefts of the palate can vary in severity. Some may involve just the uvula and the soft palate. These are incomplete clefts of the palate. Others extend the length of the palate and are complete clefts. They may involve one side of the palate (unilateral) or both sides (bilateral).

Etiology: The exact cause of lip and palatal clefting is not known, but most experts feel that it is due to both genetic and environmental factors. Clefts are associated with abnormalities in the genes which may be a result of inheritance or from a spontaneous mutation during fetal development. We recommend genetics counseling to discuss causes of the cleft and the recurrence risk factors.

Team Assessment: Children born with clefts should be carefully assessed by the craniofacial team in order to detect potentially serious abnormalities that can be associated with clefting. There are over 150 syndromes that include cleft lip or palate in their differential diagnosis. Generally, clefting is the only congenital abnormality that the child has, but nearly 15 percent of all cleft lip or palate patients present clinically with multiple problems.

The team concept allows a systematic, comprehensive treatment plan to be developed and allows the team members to work together to identify problems before they become significant. The most common specialties involved in the care of a child with a cleft are: plastic surgery, otolaryngology, dentistry, audiology, speech pathology, genetics and pediatrics. Once a complete assessment of the child with a cleft has been performed, a plan for treatment can be outlined.

FEEDING AN INFANT WITH A CLEFT

Feeding an infant is important not only in providing nourishment, it also provides an intimacy and closeness for both the parent and the child. Infants with a cleft of the lip or of the soft palate seldom have problems with feeding either by bottle or breast.

In babies with clefts of the hard palate, the opening in the roof of the mouth often causes difficulty in creating adequate pressure on the nipple, thus creating an inability to suck well enough to get adequate nourishment. Feeding the infant takes patience and practice. At our center we recommend the use of a soft squeezable plastic bottle like Mead Johnson with an orthodontic nipple such as Nuk. You can increase the flow by gently squeezing or putting pressure on the bottle. It is important to feed the infant before he/she becomes too hungry. Position the infant in an upright position with the head tilted back slightly. This position allows the milk to flow down into the throat and less into the nose. Infants with clefts do swallow more air and need to be burped more frequently. At first, it may take extra time, but this will steadily decrease. Feeding time of the newborn varies from 20-30 minutes. When feeding takes longer than 45 minutes, the infant may be burning up calories necessary to gain weight. If this occurs the feeding consultant should be contacted to help with the feeding technique.

Breast feeding the newborn with a cleft of the hard palate is often unsuccessful. Generally the infant cannot produce enough negative pressure to obtain ample breast milk to provide adequate nourishment. Using a breast pump to extract the milk and feeding the infant breast milk from a squeezable bottle is recommended.

SURGERY

Cleft Lip Repair - The objective in repairing the lip is to close the cleft to create a pleasing face that will develop normally with minimal scarring. Closure of the lip is performed by the plastic surgeon when the baby is approximately 3 months of age and weighs at least 10 pounds. When there is involvement of the alveolus and palate, an orthodontic appliance may be placed in the maxillary segments as the first procedure. This is performed by the team dentist as an outpatient surgical procedure. The appliance is used to align the alveolus so that it can be repaired (gingivoperiosteoplasty) at the time of the lip repair or lip adhesion. This improves nasal support on the cleft side and creates a tunnel that should develop bone, closing the cleft. If the alveolus is not closed in infancy, then the alveolar ridges will be orthodontically aligned and a bone graft performed to stabilize the maxilla (5-10 years of age). Correction of the nasal deformity is usually performed at the time of lip repair. Additional procedures may be necessary to enhance the appearance of either the lip or nose.

Photos to the right:

A unilateral cleft lip is shown. A custom fitted Latham appliance has been fabricated and placed to rotate alveolar segments together. Postoperative result is shown after repair of alveolar cleft and lip.

Unilateral Cleft Lip with Custom Latham



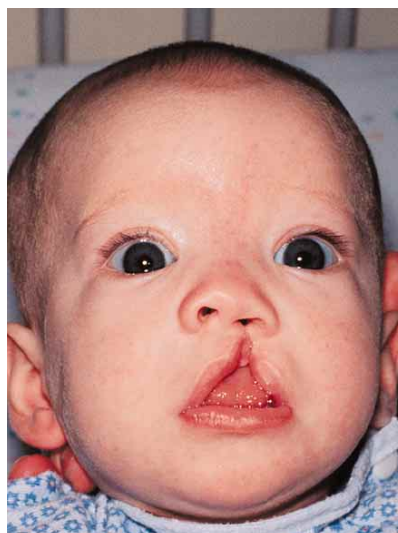
UNILATERAL CLEFT LIP REPAIR

A unilateral cleft lip results from failure of the union of the maxillary and median nasal processes, thus creating a split or cleft in the lip on either the left or right side. It may be just a notching of the lip or extend completely through the lip into the nose and palate. A number of procedures have been described to repair the unilateral cleft lip. The procedure used at our Center is the Millard rotation advancement technique. The procedure is designed to reconstruct the lip, muscle, oral mucosa, and to reposition the nose. It is performed under general anesthesia with surgery lasting 2-3 hours and a hospital stay of 2-4 days. Special considerations are necessary for feeding and positioning the infant postoperatively. The baby's elbows are restrained from bending to prevent him/her from disrupting the nose or lip. Positioning the child in an infant seat keeps him/her from rolling over and injuring the lip or nose. Pacifiers and nipples are not allowed. The baby is fed with a special syringe feeder with a soft tube. It takes approximately 3 weeks for the wound to gain enough strength to discontinue the above precautions. The lip scar is initially red and swollen, but it begins to mature and improve in appearance in six-twelve months.

Photos to the right:

Photos of infants who underwent repair of unilateral cleft lip with rotation advancement technique.

Unilateral Cleft Lip



Preoperative



Postoperative



Preoperative



Postoperative



Preoperative

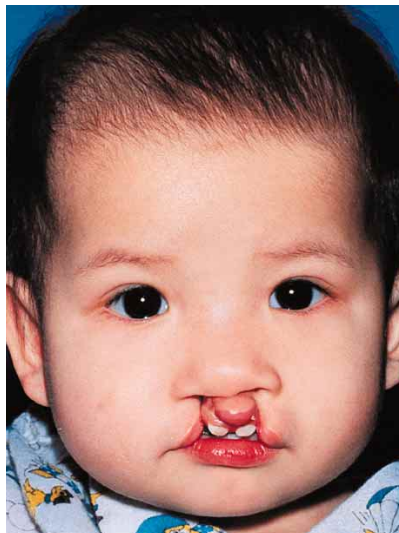

Postoperative

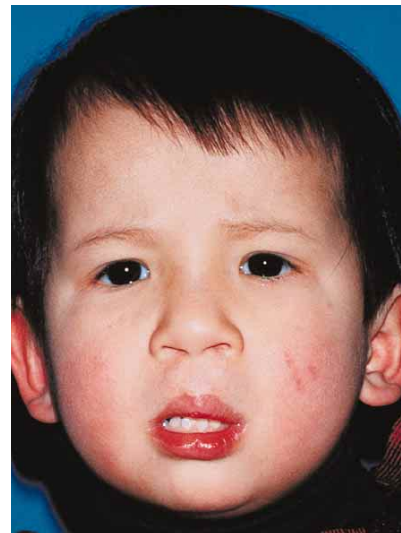BILATERAL CLEFT LIP

The bilateral cleft lip involves separation of the lip along philtral lines, isolating the central segment (prolabium). Fifteen percent of children born with cleft lips have bilateral clefts. The associated nasal deformity is usually more severe than the unilateral cleft due to a very short columella and flaring of both nostrils. Surgical correction of the bilateral cleft lip is usually performed in one procedure at three months of age; however, the procedure may be staged, closing one cleft at a time. Rotation of the nostrils to a more normal position is performed in the first procedure. A second procedure is performed by 2-3 years of age to lengthen the columella. Patients with complete bilateral cleft lips frequently require additional procedures to enhance the appearance of the lip and nose. Performed under general anesthesia, the operation generally requires 2-3 hours. A hospital stay of 2-4 days should be expected. Feeding, positioning and elbow restraints are the same as those for repair of the unilateral cleft lip.

Bilateral Cleft Lip



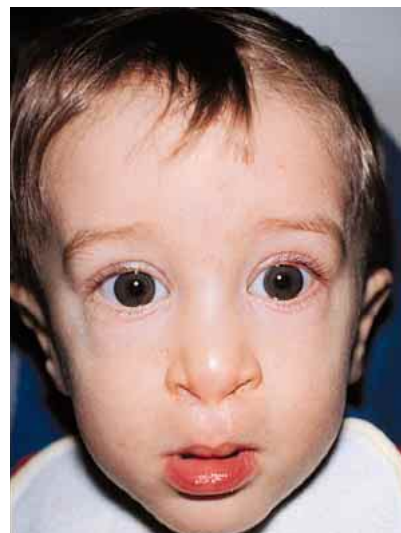Preoperative



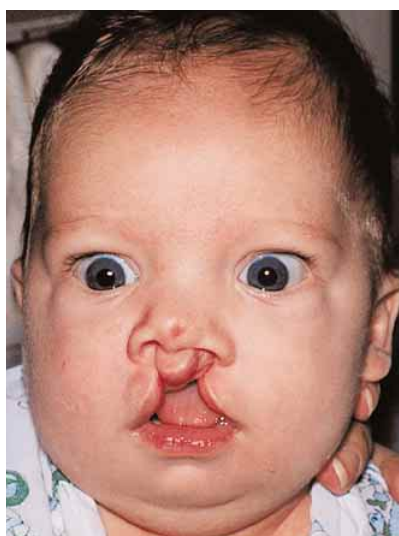Postoperative



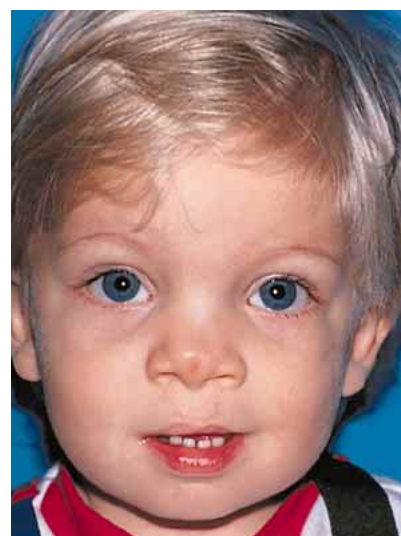Preoperative



Postoperative



Preoperative



Postoperative

Photos to the right:

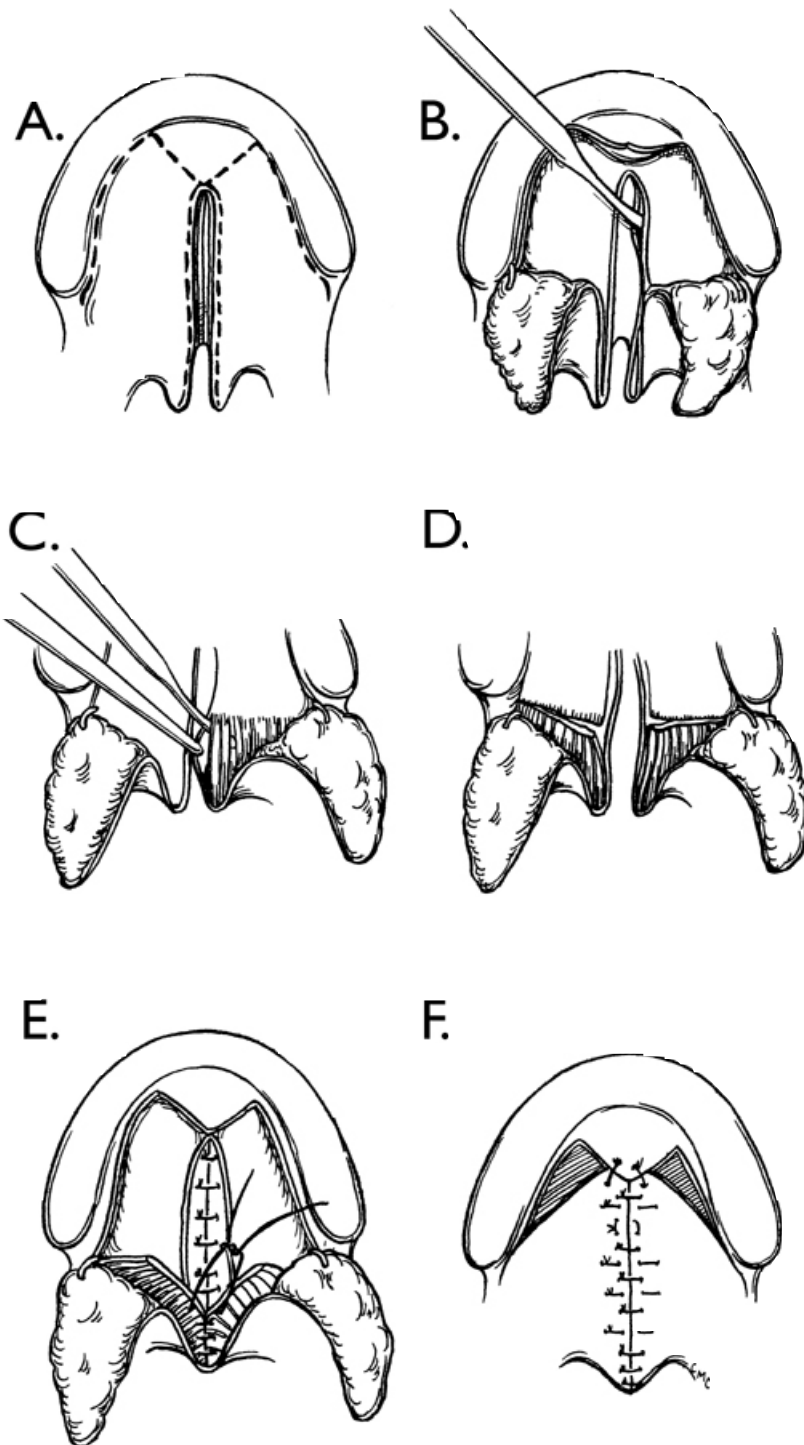
Photos of infants who underwent one stage repair of bilateral cleft lip.

CLEFT PALATE REPAIR

The objective of cleft palate surgery is to close the palate to restore normal function to eating and drinking and to enhance the development of normal speech.

Clefts of the palate can occur as isolated deformities or in combination with a cleft of the lip. Cleft palates result from failure of fusion of the embryonic facial processes resulting in a fissure through the palate. This may be complete (extending through the hard and soft palates) or any degree of incomplete (partial cleft). The palate forms the roof of the oral cavity and the floor of the nose; thus, a cleft causes a free communication between these two cavities. As a result, treatment of palatal clefts is complex because of potential problems with feeding, speech, middle ear infections, occlusion and jaw alignment.

Surgical treatment of the cleft palate is best accomplished in one surgical procedure before the child reaches 12-14 months of age. The cleft palate is surgically closed by elevating two muscoperiosteal flaps. The levator muscles are elevated, redirected and repaired; and a three layer closure of nasal mucosa, muscle and oral mucosa accomplished. Surgery under general anesthesia usually lasts about 2 hours. Special precautions as those after the repair of the cleft lip are necessary for 2-3 weeks. We prefer that the child be weaned from the bottle and pacifier prior to the palatal repair. No hard or crunchy foods are allowed for 3 weeks post operatively.



Cleft Palate Repair:

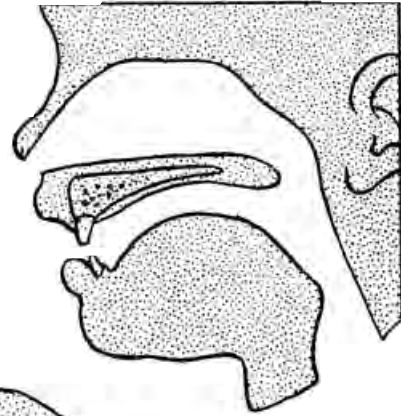
Closure of cleft palate with pushback palatoplasty. A). Two muscoperiosteal flaps are outlined. B). Flaps are elevated off the hard palate. C,D). The abnormal levator muscle insertion to the hard palate is identified and cut free. E). The nasal lining is closed as a separate layer and the levator muscle reapproximated. F). The palatal mucoperiosteal flaps are closed in a V-Y fashion.

PHARYNGEAL FLAP

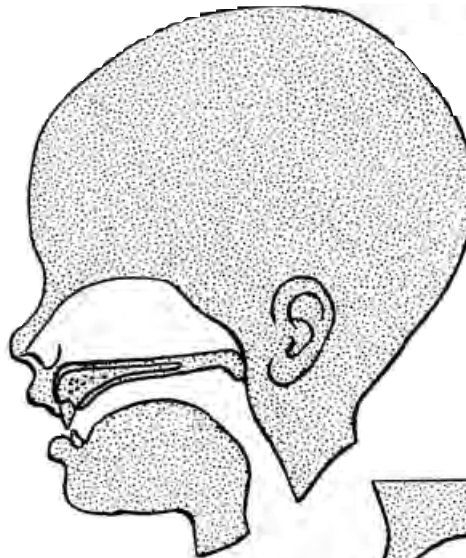
Approximately 70-80 percent of all cleft palate patients will develop velopharyngeal competence after palate closure and thus the potential for normal speech. The remaining 20-30 percent will require speech therapy and/or an additional surgical procedure called a pharyngeal flap. To correct persistent hypernasal speech, this procedure involves raising a flap of tissue from the posterior pharynx and inserting it into the soft palate. This flap is indicated when the repaired palate is too short or the muscles do not function properly, causing a persistent hypernasal speech. The procedure is performed usually after the age of 4-5 when speech and velopharyngeal competence can be thoroughly assessed and before the child begins school.

LATE CLEFT TREATMENT

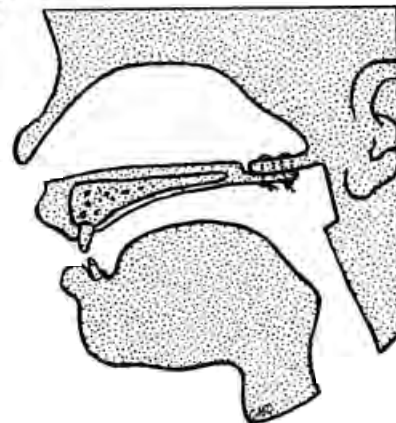
The Craniofacial Center can also help those individuals that have grown up without access to a comprehensive, coordinated team approach. For adults with speech problems, the previously mentioned pharyngeal flap, combined with an intensive regimen of speech therapy, can produce significant improvements. Orthognathic surgery is available to patients with deformities of the jaws to improve their appearance as well as to correct dental occlusion. For soft tissue revision of a severely tightened or notched upper lip, an Abbe flap is the surgical option. This procedure is usually indicated in bilateral cleft patients who have a short or deficient columella and a tightened upper lip. This operation



Inadequate Closure



Adequate Closure



Corrected Closure

Pharyngeal Flap:

The pharyngeal flap procedure for hypernasal speech. A superiorly based flap of tissue is raised from the posterior pharynx and sutured to the soft palate thereby decreasing the amount of air through the nose. Lateral ports or holes are left so that the nose will not be obstructed.

can add fullness to the upper lip as well as lengthen the columella. A number of additional surgical therapies, similar to the ones described, are available to patients who desire further improvements.

HEARING

Children with cleft palate have a higher incidence of hearing problems. The Eustachian tube connects the middle ear space to the back of the throat. It normally opens and shuts to relieve pressure that builds up behind the ear drum. If the Eustachian tube does not open, then the pressure increases until mucus or “fluid” accumulates behind the eardrum. The muscles responsible for opening the Eustachian tube do not function as well in children with cleft palates resulting in more frequent problems with fluid, otitis media and ear infections which can be very painful. Because of this problem, it is important to have the infant’s hearing tested during the first few months. If hearing is impaired by fluid buildup or unequal pressure, it may be necessary for the otolaryngologist to place pressure equalizing (PE) tubes. Tubes are often placed at the time of the lip or palate surgery. It is crucial that children with cleft palates have regular hearing tests to monitor middle ear problems that could alter the development of normal hearing as well as speech. As the child grows, the frequency of ear infections and fluid in the ears seem to decrease.

SPEECH

Speech development in children with cleft lip only should be normal. The unrepaired cleft palate causes speech to sound hypernasal because air passes through the nose while talking. Most speech sounds require the nose to be closed off from the mouth. Cleft palate surgery usually remedies the problem, but speech therapy is still recommended. Approximately 20-30 percent of cleft palate

patients will have velopharyngeal incompetence or hypernasal speech after surgery, and may require a pharyngeal flap to correct it around the age of 4-5 years.

DENTAL

Clefts of the palate generally have an effect on dental development. In the area of the cleft, teeth often erupt in a crooked position with extra teeth or missing teeth being common in the cleft area. Radiographs are often taken to determine the exact position of the teeth. Dental problems have an effect on speech, chewing, appearance and frequently require orthodontic treatment. Early orthodontic intervention may require a palatal expansion device with further alignment of the dental arches. Later treatment after the primary teeth have erupted can begin at 10-12 years of age. Orthognathic surgery may be indicated if a malocclusion develops due to abnormal growth of the maxilla.

PIERRE ROBIN SYNDROME

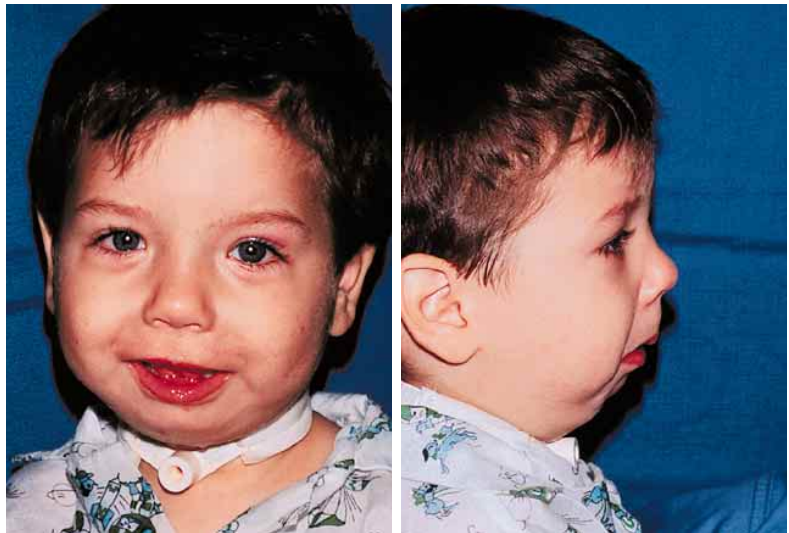This syndrome was described in 1923 by Pierre Robin in which he described airway obstruction associated with glossoptosis and hypoplasia of the mandible. Today this syndrome is characterized by retrognathia or micrognathia, glossoptosis, and airway obstruction. An incomplete cleft of the palate is associated with the syndrome in approximately 50% of these patients.

In patients with micrognathia (small jaw) or retrognathia, the chin is posteriorly displaced causing the tongue to fall backward toward the posterior pharyngeal wall. This results in obstruction of the airway on inspiration. Crying or straining by these children can often keep the airway open. However, when the child relaxes or falls asleep, airway obstruction occurs. Due to these respiratory problems, feeding may become very difficult. This can lead to

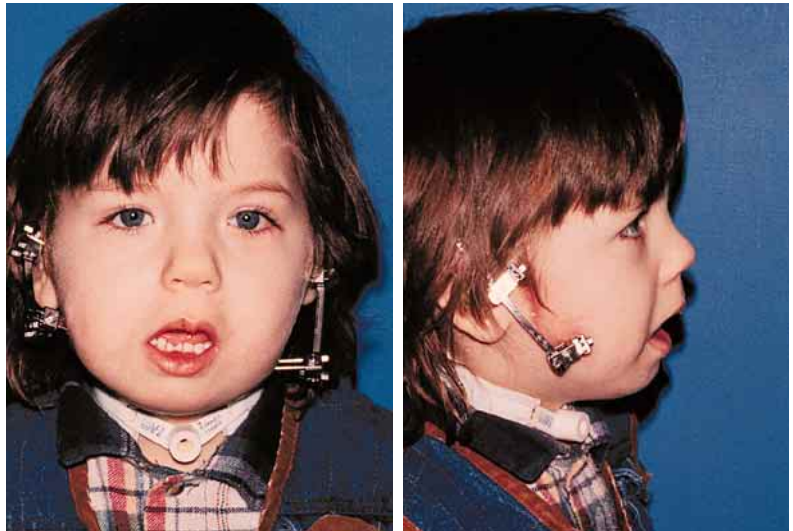a sequence of events: glossoptosis, airway obstruction, crying or straining with increased energy expenditure and decreased oral intake. This vicious cycle of events if untreated can lead to exhaustion, cardiac failure, and ultimately death.

Treatment of this syndrome can be divided into conservative therapy versus surgical intervention. The majority of these patients can be managed by placing the infant in the prone position until adequate growth of the jaw occurs. This causes the jaw and the tongue to fall forward opening the airway. If this type of treatment fails the infant should then be considered for a tongue-lip adhesion (a procedure to pull the tongue forward) or a tracheostomy.

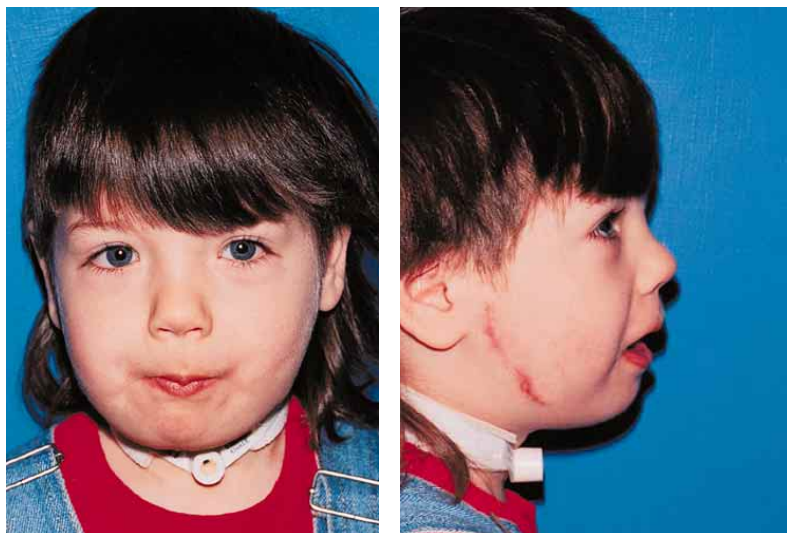In children with severe underdevelopment of the lower jaw, a new technique called mandibular bone expansion is now available. This technique also called distraction osteogenesis involves placement of an expansion device that is turned daily to slowly lengthen the jaw. An external incision is required to make a surgical cut through the jaw bone with placement of pins that are secured to the expansion device. Once the amount of expansion of the bone has been obtained (4-5 weeks) the device is then kept in place until the bone gap heals with new bone formation (8 weeks). This technique can be performed at a very early age which is a significant advantage over the traditional technique of lower jaw lengthening.



Two year old with Pierre Robin and severe airway obstruction requiring tracheostomy.



Bilateral mandibular lengthening devices surgically placed with lengthening in progress.



Results after removal of lengthening devices. Patient now ready for removal/closure of tracheostomy.

can add fullness to the upper lip as well as lengthen the columella. A number of additional surgical therapies, similar to the ones described, are available to patients who desire further improvements.

HEARING

Children with cleft palate have a higher incidence of hearing problems. The Eustachian tube connects the middle ear space to the back of the throat. It normally opens and shuts to relieve pressure that builds up behind the ear drum. If the Eustachian tube does not open, then the pressure increases until mucus or “fluid” accumulates behind the eardrum. The muscles responsible for opening the Eustachian tube do not function as well in children with cleft palates resulting in more frequent problems with fluid, otitis media and ear infections which can be very painful. Because of this problem, it is important to have the infant’s hearing tested during the first few months. If hearing is impaired by fluid buildup or unequal pressure, it may be necessary for the otolaryngologist to place pressure equalizing (PE) tubes. Tubes are often placed at the time of the lip or palate surgery. It is crucial that children with cleft palates have regular hearing tests to monitor middle ear problems that could alter the development of normal hearing as well as speech. As the child grows, the frequency of ear infections and fluid in the ears seem to decrease.

SPEECH

Speech development in children with cleft lip only should be normal. The unrepaired cleft palate causes speech to sound hypernasal because air passes through the nose while talking. Most speech sounds require the nose to be closed off from the mouth. Cleft palate surgery usually remedies the problem, but speech therapy is still recommended. Approximately 20-30 percent of cleft palate

patients will have velopharyngeal incompetence or hypernasal speech after surgery, and may require a pharyngeal flap to correct it around the age of 4-5 years.

DENTAL

Clefts of the palate generally have an effect on dental development. In the area of the cleft, teeth often erupt in a crooked position with extra teeth or missing teeth being common in the cleft area. Radiographs are often taken to determine the exact position of the teeth. Dental problems have an effect on speech, chewing, appearance and frequently require orthodontic treatment. Early orthodontic intervention may require a palatal expansion device with further alignment of the dental arches. Later treatment after the primary teeth have erupted can begin at 10-12 years of age. Orthognathic surgery may be indicated if a malocclusion develops due to abnormal growth of the maxilla.

PIERRE ROBIN SYNDROME

This syndrome was described in 1923 by Pierre Robin in which he described airway obstruction associated with glossoptosis and hypoplasia of the mandible. Today this syndrome is characterized by retrognathia or micrognathia, glossoptosis, and airway obstruction. An incomplete cleft of the palate is associated with the syndrome in approximately 50% of these patients.

In patients with micrognathia (small jaw) or retrognathia, the chin is posteriorly displaced causing the tongue to fall backward toward the posterior pharyngeal wall. This results in obstruction of the airway on inspiration. Crying or straining by these children can often keep the airway open. However, when the child relaxes or falls asleep, airway obstruction occurs. Due to these respiratory problems, feeding may become very difficult. This can lead to

a sequence of events: glossoptosis, airway obstruction, crying or straining with increased energy expenditure and decreased oral intake. This vicious cycle of events if untreated can lead to exhaustion, cardiac failure, and ultimately death.

Treatment of this syndrome can be divided into conservative therapy versus surgical intervention. The majority of these patients can be managed by placing the infant in the prone position until adequate growth of the jaw occurs. This causes the jaw and the tongue to fall forward opening the airway. If this type of treatment fails the infant should then be considered for a tongue-lip adhesion (a procedure to pull the tongue forward) or a tracheostomy.

In children with severe underdevelopment of the lower jaw, a new technique called mandibular bone expansion is now available. This technique also called distraction osteogenesis involves placement of an expansion device that is turned daily to slowly lengthen the jaw. An external incision is required to make a surgical cut through the jaw bone with placement of pins that are secured to the expansion device. Once the amount of expansion of the bone has been obtained (4-5 weeks) the device is then kept in place until the bone gap heals with new bone formation (8 weeks). This technique can be performed at a very early age which is a significant advantage over the traditional technique of lower jaw lengthening.



Two year old with Pierre Robin and severe airway obstruction requiring tracheostomy.

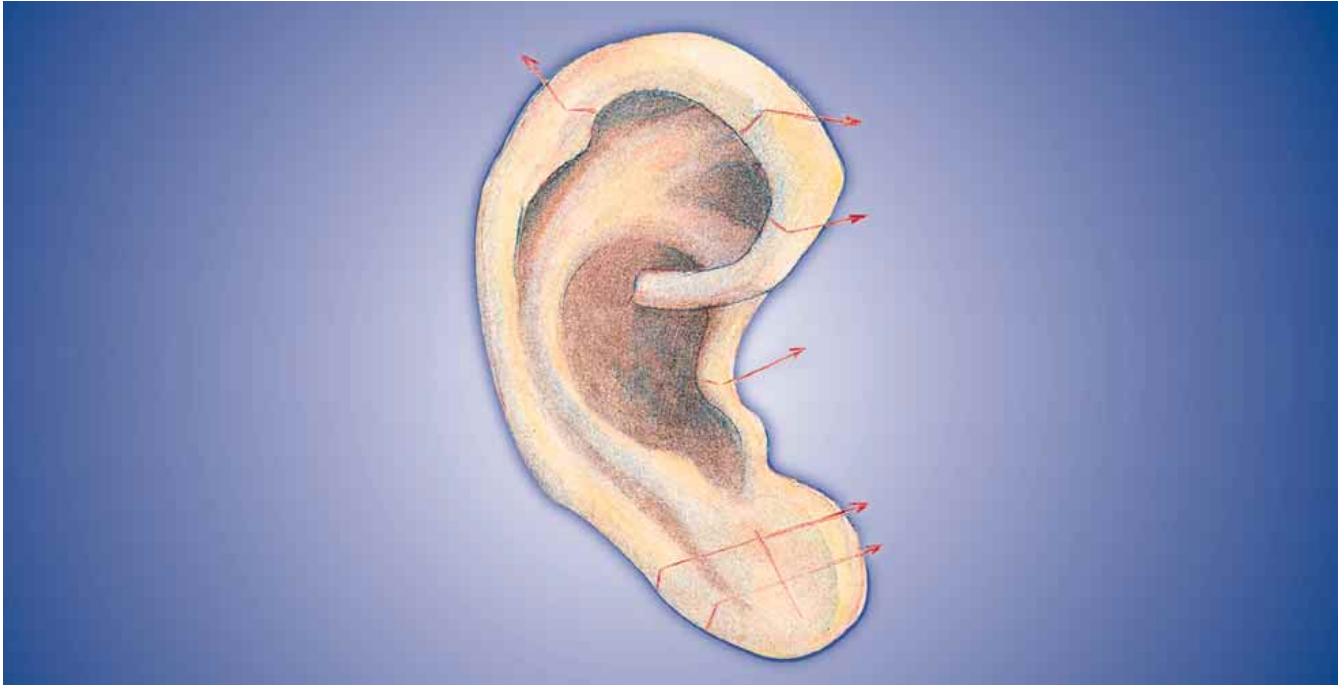


Bilateral mandibular lengthening devices surgically placed with lengthening in progress.



Results after removal of lengthening devices. Patient now ready for removal/closure of tracheostomy.

Ear Reconstruction



EAR RECONSTRUCTION

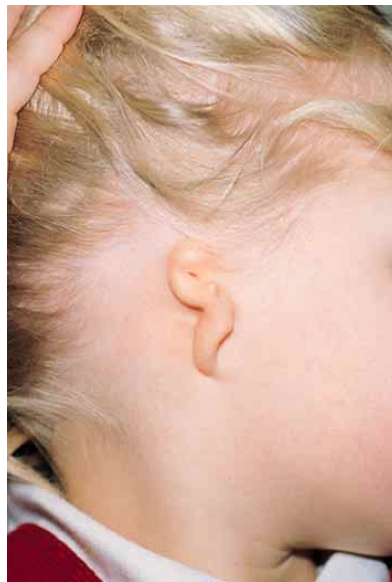Reconstruction of the ear is one of the most challenging problems facing a reconstructive surgeon as it demands precise technique combined with artistic creativity. Microtia is a congenital deformity of the external ear where the auricle (the external ear) is severely deformed. There may be a spectrum of external ear deformities with various degrees of involvement of the middle and inner ear. This type of ear deformity is commonly seen in patients with hemifacial microsomia and Treacher-Collins syndrome.

Psychological effects of an ear deformity play a significant role in timing of reconstruction. Most surgeons prefer to initiate treatment when the patient is between 5 and 7 years of age since this early intervention will reduce anxiety as a result of peer pressure. This also allows for sufficient rib growth to provide the quantity of cartilage needed by the surgeon for adequate framework fabrication. Surgery at this time can give a more consistent result than earlier intervention due to the fact that the child has had a chance to grow, thus making it easier for the surgeon to balance the size and shape of the reconstructed ear to the child's normal ear.

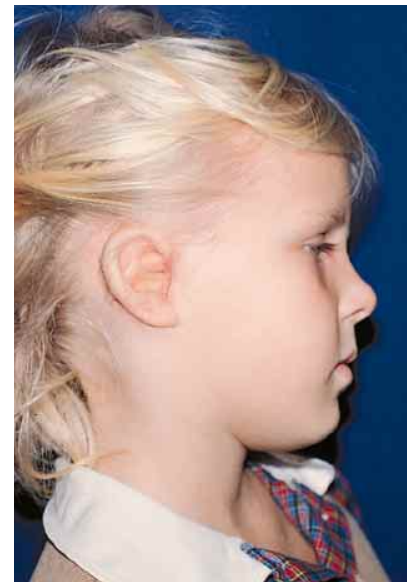
MICROTIA

The treatment of microtia involves surgical reconstruction of the external ear framework. Ear

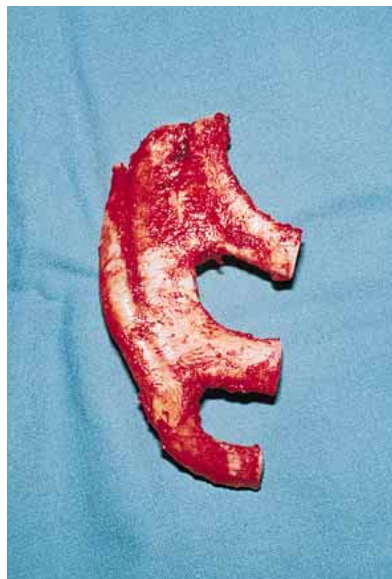
Microtia



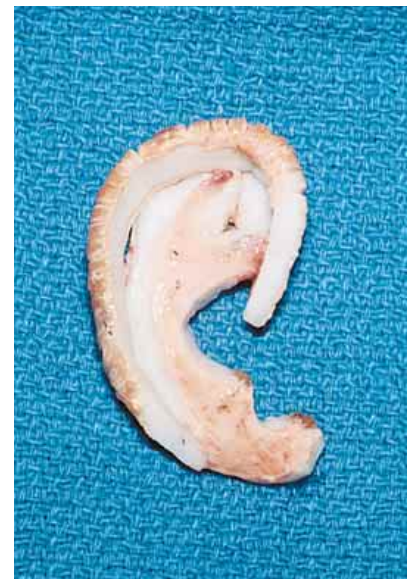Preoperative



Postoperative



Costal cartilage harvested from left chest wall.



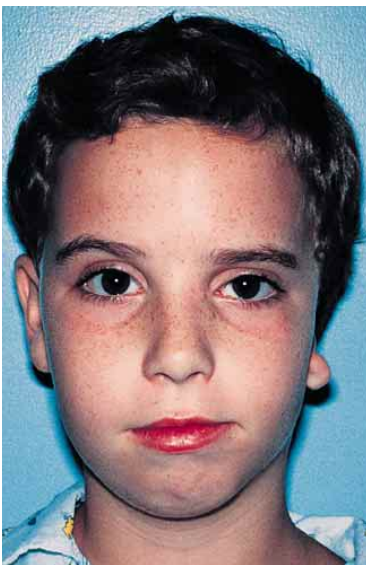Cartilage carved into ear framework.

reconstruction requires a carefully planned, staged reconstruction that involves 3-4 operative procedures. The first procedure involves the construction of the cartilage framework for the ear. Under general anesthesia, donor cartilage for the frame is obtained en bloc from the

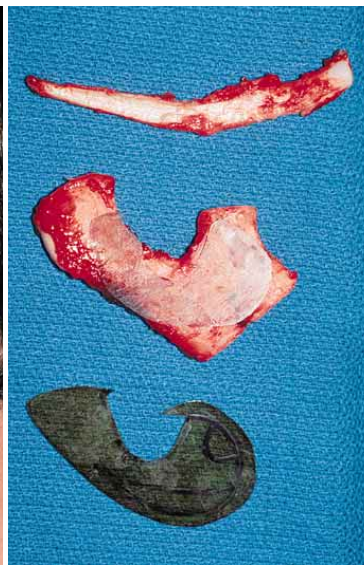
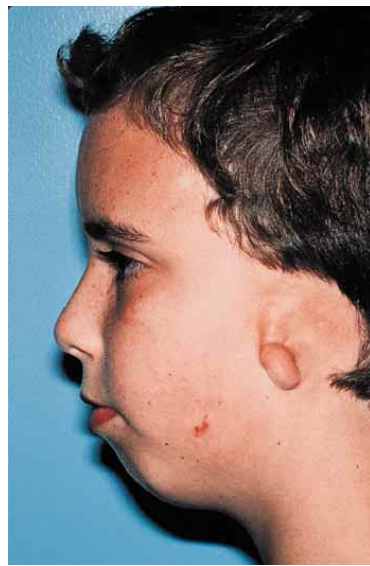rib area contralateral to the ear being reconstructed to take full advantage of the cartilage's natural curvature. Working from pre-surgical templates that have been drawn as well as from photographs, the surgeon then carves the cartilage into its new shape and carefully positions the graft into position. The overlying skin then redrapes to the newly carved cartilage framework. Subsequent operations are required to rotate the lobule and to elevate the framework into its final position.

It is of significance to note that if there is normal hearing in one ear, surgery to improve hearing in the abnormal ear is not recommended. Almost 90% of all patients with microtia have only unilateral involvement and quickly adjust to this condition following birth. Potential gains from working on the middle ear are outweighed by the inherent risks of the surgery itself. Therefore, middle ear surgery should be performed only on the true bilateral microtia patient or the patient with significant hearing loss in both ears.

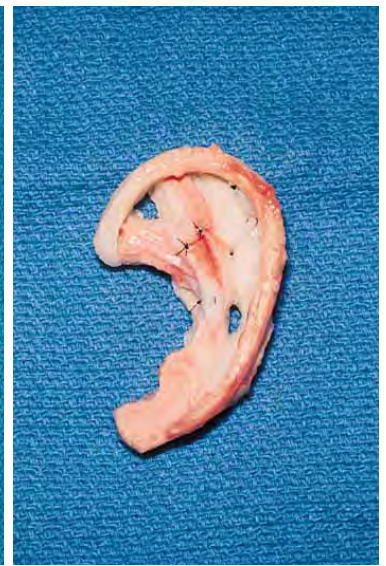Microtia



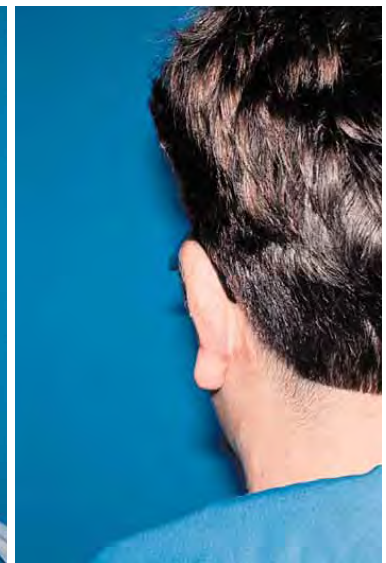
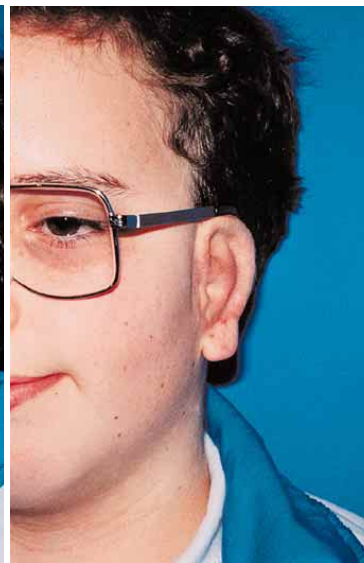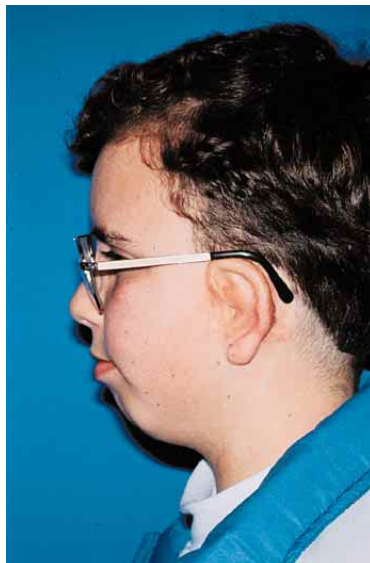Nine year old with left microtia.



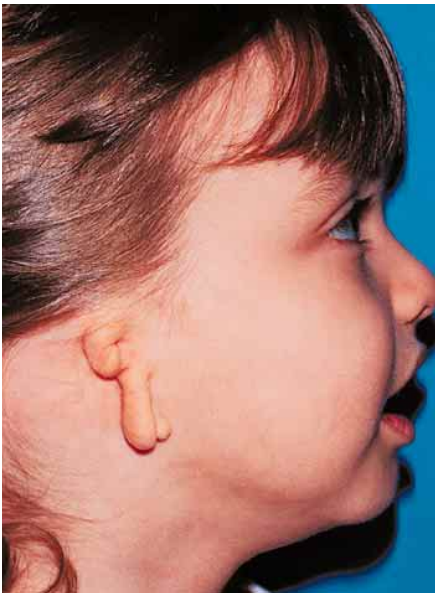Costal cartilage harvested from chest wall.



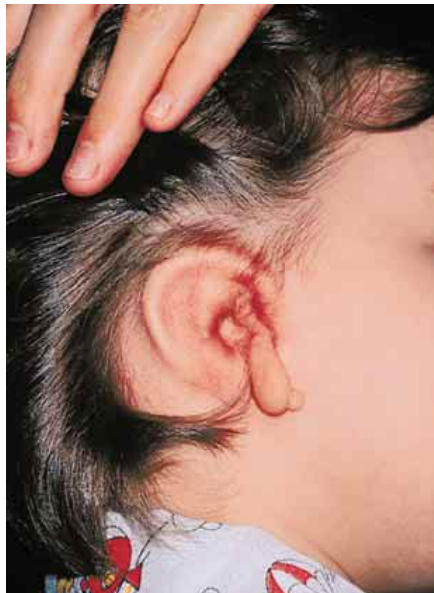Cartilage carved into ear framework.



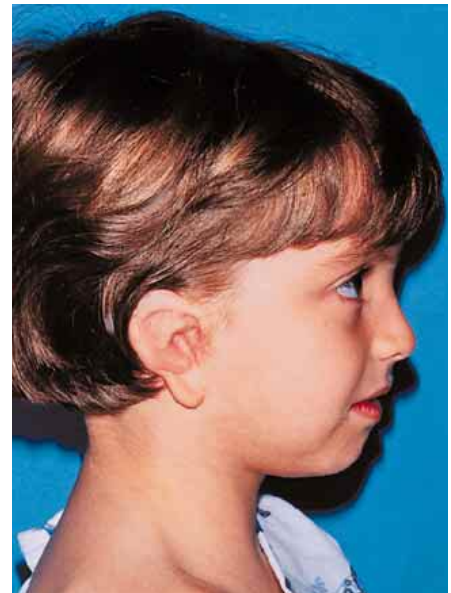Postoperative result after staged ear reconstruction.



Four year old born with right microtia.



Appearance of ear after first stage reconstruction.

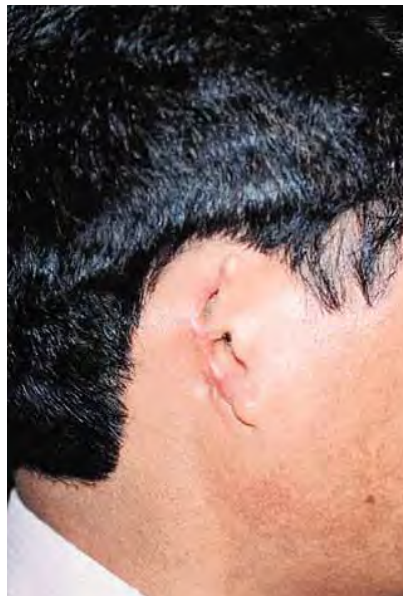

Postoperative result after staged reconstruction.

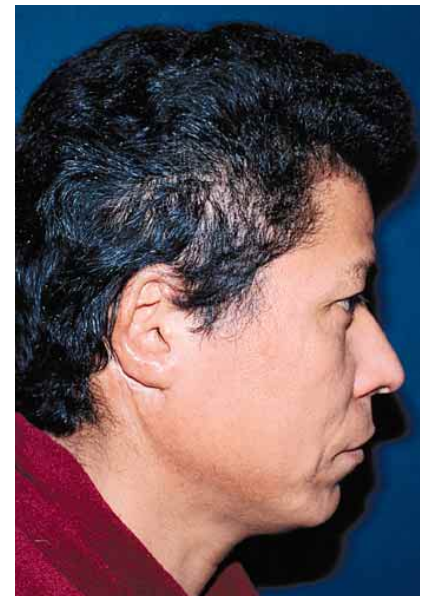TRAUMATIC EAR DEFORMITIES

The traumatic amputation of an ear is another circumstance in which this type of staged cartilage reconstruction can be effectively used. The amount of ear loss determines the types and stages of reconstruction needed. If only a small part of the ear is lost from trauma or tumor resection, then helical or rim advancement flaps may be used to reconstruct this portion. If larger sections are lost then a staged reconstruction is necessary. Effective ear reconstruction is dependent upon meticulous surgical technique and careful preoperative planning.

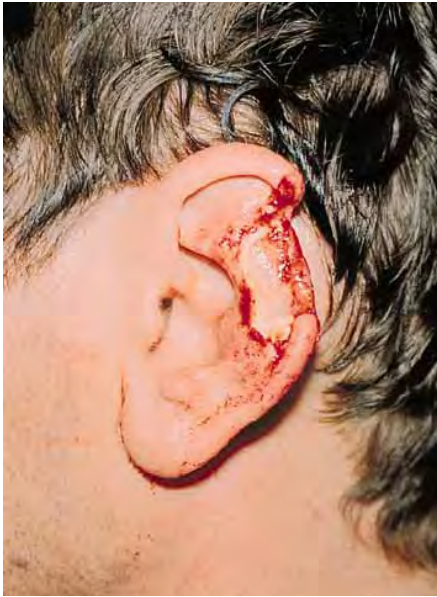Reconstruction of traumatic ear deformity



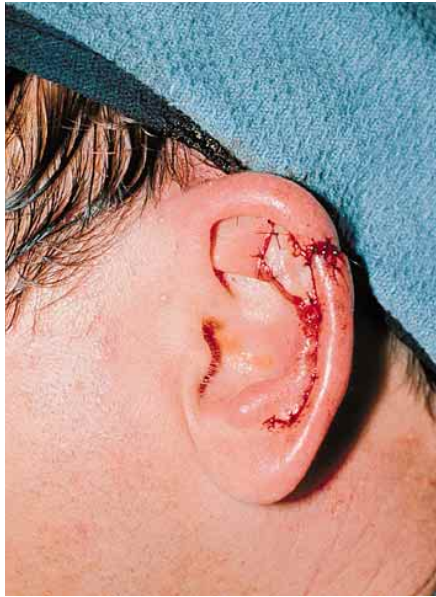Preoperative



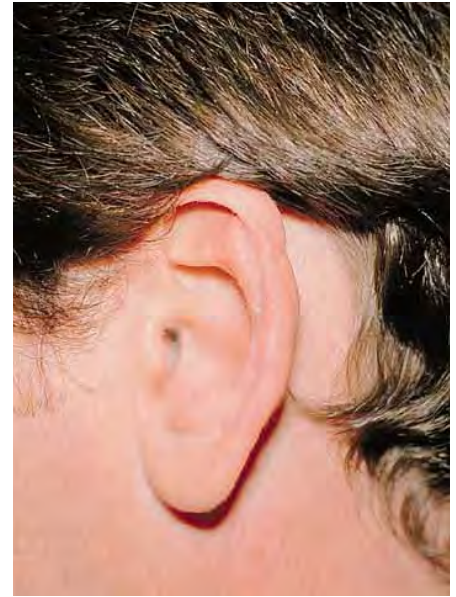
Postoperative



Human bite to ear with loss of middle third.



Helical rim flap reconstruction.

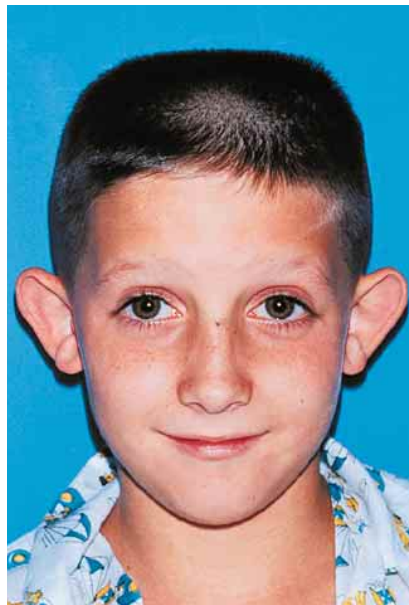

Postoperative result.

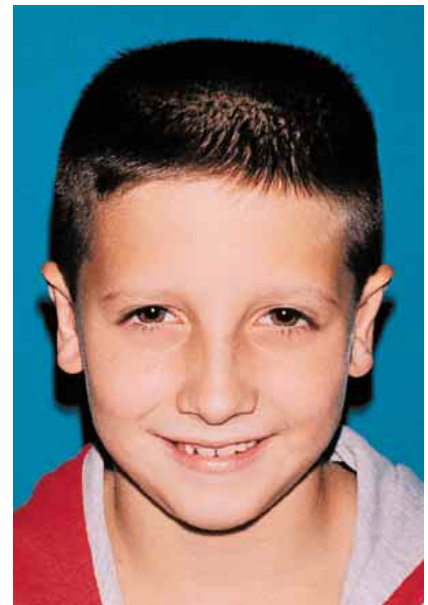OTOPLASTY

Another congenital deformity of the ears is called prominent or protruding ears. The ear's prominence is due to lack of development of the antihelical fold. The primary reason to correct this deformity is to eliminate the psychological trauma that this condition can cause. Peer ridicule can be severe with this particular deformity. The operation designed to correct this problem involves recreating the antihelical fold curling or setting the ears back closer to the head. With experience, consistently good results can be obtained.

Protruding Ears

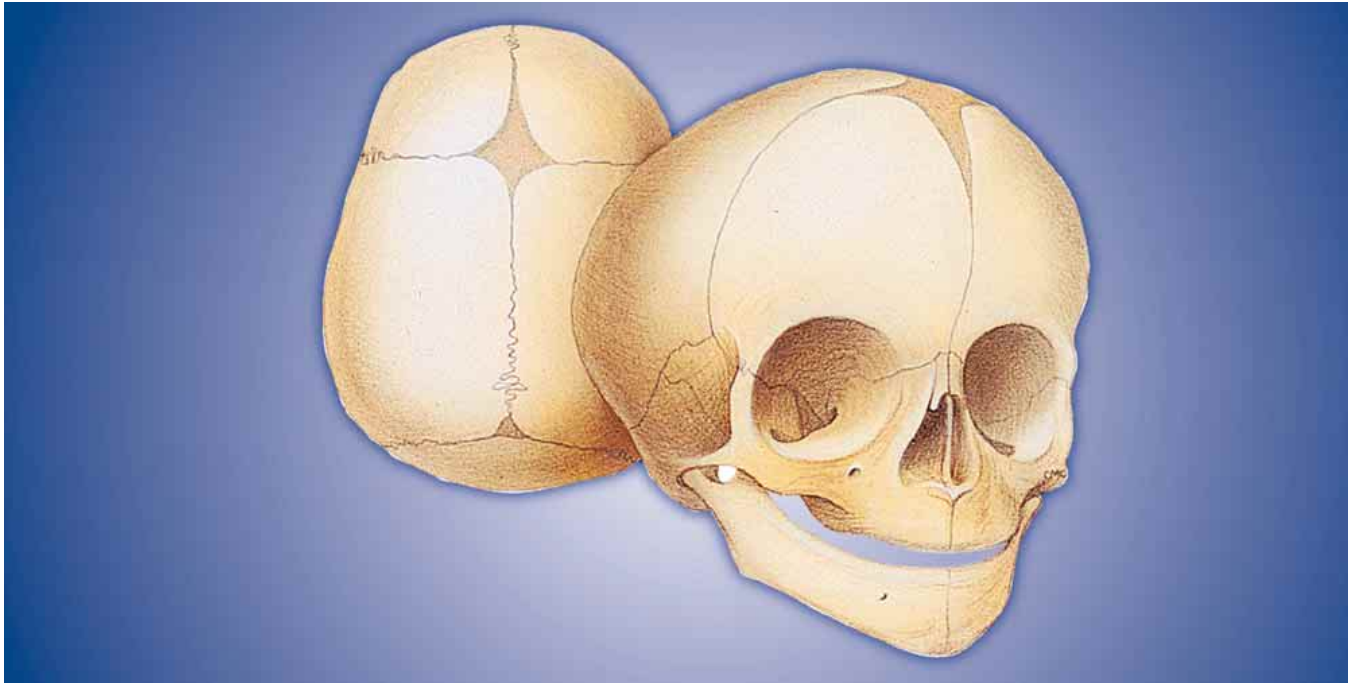


Eight year old with bilateral protruding ears.

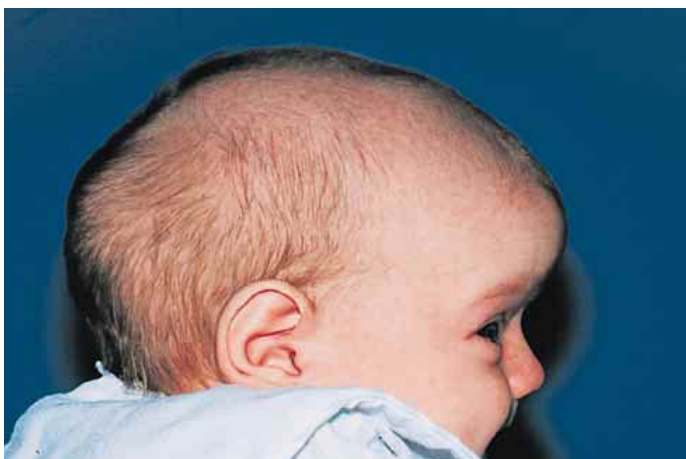

Postoperative result after otoplasty.

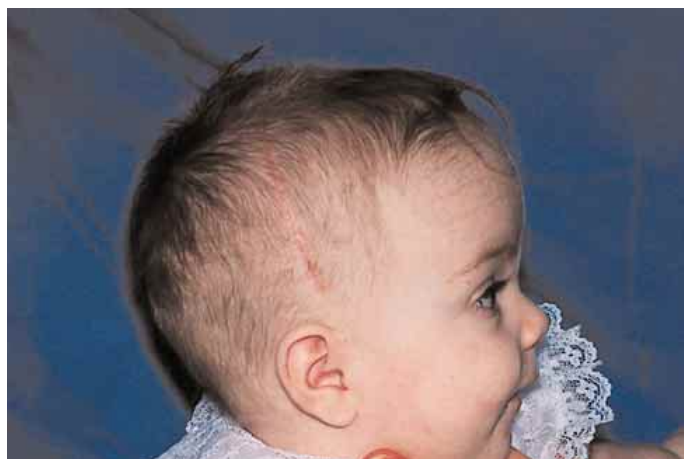Craniosynostosis



CRANIOSYNOSTOSIS



Preoperative

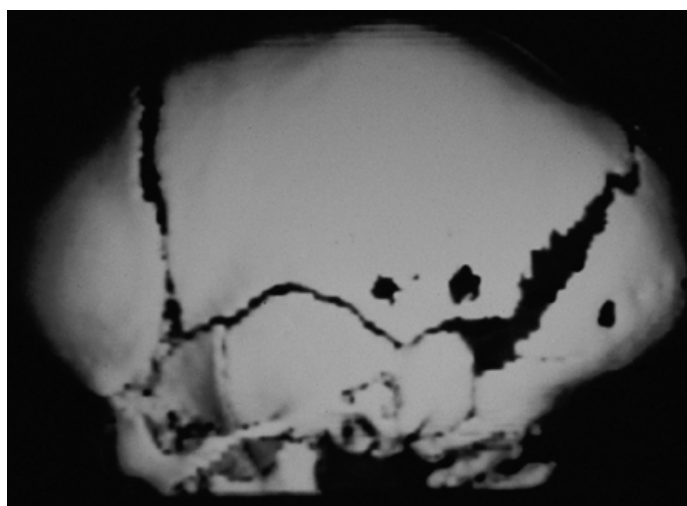


Postoperative

Craniosynostosis can be defined as the premature closing of one or more of the normally present bony gaps between the different bones of the skull. These linear areas where the bones have not yet healed together are called cranial sutures. They intersect in certain areas of the skull forming “soft spots” or fontanelles. The cranial suture lines or non-ossified zones accommodate the brain’s growth and expansion during the first years of life. The brain increases in volume about 2-1/2 to 3 times the first two years of life with these non-ossified areas of bone remaining open for a variable length of time and then closing in a predictable manner. Premature synostosis or closure of the suture will stop the growth of the skull in the direction perpendicular to that suture; however, growth will continue in the direction parallel to the suture. The result is that synostosis of a particular suture will alter the shape of the skull in a predictable manner with recognizable patterns. With multiple suture involvement, increased intracranial pressure can occur since the skull cannot sufficiently expand to accommodate normal brain growth. In moderate craniosynostosis with only one suture involved increased intracranial pres-

sure has been found to be present in approximately 13-23% of patients.

The surgical treatment of craniosynostosis has been transformed by the development and applications of craniofacial techniques to reshape the skull and upper face in the infant. Functionally, the goal in treatment is to release the fused sutures to prevent any problems associated with increased intracranial pressure as well as creating the potential for normal growth. Cosmetically, the goal is to obtain normal shape of the skull and face, thus minimizing psychosocial problems.



3-D Scan of Sagittal Synostosis

Approximately one infant in every one thousand births will have a premature closure of a cranial suture associated with a skull deformity. Infants born with abnormal skull shapes should be suspected of having craniosynostosis. However, abnormal skull shapes at birth may be related to fetal head position or birth trauma; this type of deformity will usually correct itself in several months. True craniosynostosis will not improve with time and usually worsens with growth. On examination palpation of the abnormal portion of the head often reveals a ridge in the area of the fused suture. Once craniosynostosis is suspected, the diagnosis can be verified with plain skull radiographs and CT scans. We routinely obtain CT scans with three-dimensional reconstructions to confirm the diagnosis, rule out other intracranial abnormalities, and to fully assess the deformity. The 3-D scans can very clearly show the skull shape and help in pre-operative planning. Isolated craniosynostosis must be distinguished from a syndrome that has as one of its components craniosynostosis. The specific diagnosis is an important starting point in treatment planning.

Etiology: While the pattern of embryonic craniofacial development has been well defined through extensive research, very little is known about the etiology of many craniofacial anomalies. There is strong evidence for a genetic role in the occurrence of some craniosynostosis. An inherited tendency or family history has been reported in many cases in the literature, however, most cases of isolated craniosynostosis are usually sporadic in occurrence with no known etiology.

Team Evaluation: Patients with craniosynostosis need to be evaluated and treated at a recognized craniofacial center with a team approach. We have a multidisciplinary team at our center to provide the comprehensive care necessary to adequately evaluate and treat craniofacial patients and their families. Members of the craniofacial team work

together to insure that the patients are evaluated and treated in a coordinated manner and that all their needs, both physical and psychosocial, are met. The team combines the expertise of each specialist to provide a level of comprehensive care that cannot be provided by a single physician. The primary physician or pediatrician plays a key role in early diagnosis and referral so that a successful treatment is accomplished.

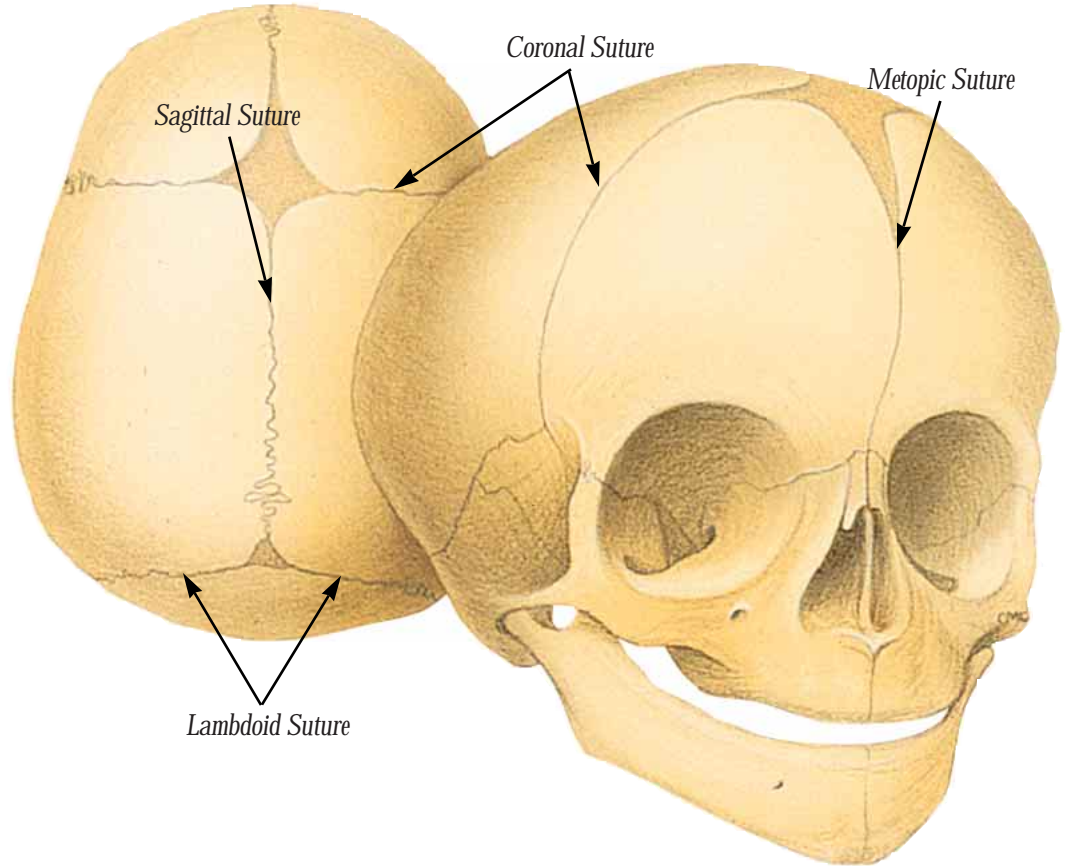
Surgical Treatment: Tremendous advancements have been made in the treatment of infants with isolated craniosynostosis due to the application of craniofacial surgery principles. Past treatments such as strip craniectomies which remove only the fused suture have resulted in unpredictable results. These procedures have often resulted in skull and facial deformities that are difficult to correct in the older child. Current surgical treatment involves a team approach with a combined expertise of a neurosurgeon and craniofacial surgeon. The goal of surgery is to establish normal contour of the brow, forehead and skull; and to allow the brain to grow and expand in a normal manner with release of synostosis. The timing of surgical correction depends on the age at diagnosis and referral. In our experience we feel that the best results are obtained when infants undergo surgical repair between 4 and 8 months of age. This period has several advantages:

- (1) remodeling is easier because the bone is very malleable;
- (2) rapid brain growth benefits bone remodeling;
- (3) bone defects heal rapidly.

Early correction also prevents further deformity caused by unreleased, fused sutures. Therefore, early diagnosis and referral to a craniofacial center is crucial. We advocate extensive release of the fused suture, total reshaping of the brow, superior orbits, and skull as necessary between 4 and 8 months of age. Older patients will require

modification of this plan due to the presence of more rigid bone and slower cranial growth. In addition, older patients may require reconstruction of secondary facial deformities.

In the event that intraoperative or post-operative blood transfusions are needed, the parents are asked to provide designated donor blood. In addition, aspirin and other medications that might prolong the blood clotting time are to be avoided.



Multiple suture lines shown in infant skull.

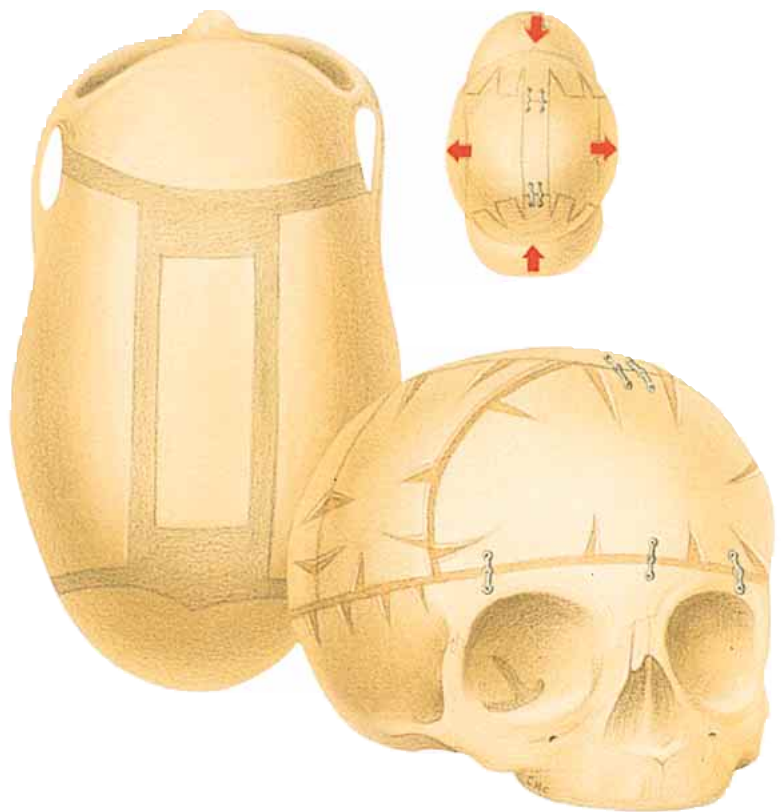
TERMINOLOGY OF CRANIOSYNOSTOSIS

FUSED SUTURE	NAME	DESCRIPTION
Sagittal	Scaphocephaly	Boat Skull
Metopic	Trigonocephaly	Triangular Skull
Unilateral Coronal	Plagiocephaly	Asymmetric Skull
Bicoronal	Brachycephaly	Short Skull
Lambdoid	Plagiocephaly	Asymmetric Skull

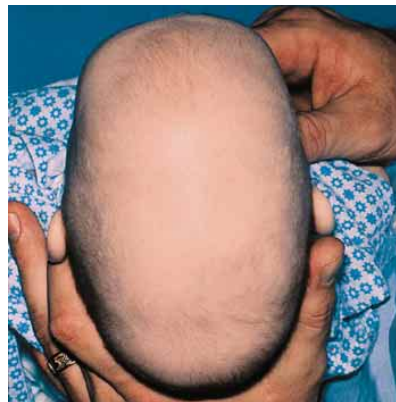SAGITTAL SYNOSTOSIS

Premature closure of the sagittal suture, the longitudinal suture on the top of the head, stops growth laterally producing a narrow head. There is a compensatory growth in the antero-posterior direction with elongation of the skull and a bulging of the front and back of the head. This particular deformity is called scaphocephaly due to the skull's boat shaped appearance. Synostosis of the sagittal suture is the most frequent type of single suture craniosynostosis. It makes up 50-60% of all patients within North America with craniosynostosis. The particular infants with sagittal synostosis characteristically have normal intelligence.

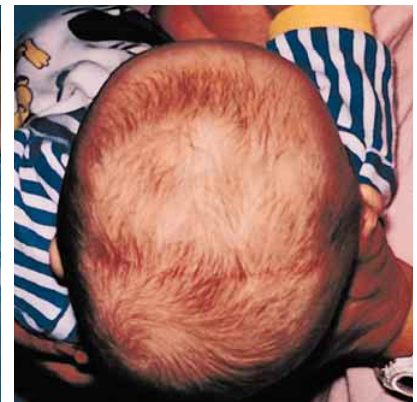In sagittal synostosis or scaphocephaly we most frequently perform total skull reshaping. In this type of synostosis the forehead and back of the skull are usually bulging, over-projected, and the width of the skull too narrow. The front, back and lateral bone plates are removed and then reshaped to a more normal contour. The forehead is tilted back (as well as the occiput) and the entire anteroposterior dimension of the skull is shortened. The reshaped bones are secured in position with wires and/or microplates. Certain gaps between the bones are left unsecured to avoid restriction of growth. The dura, or outer covering of the brain, may be plicated in the frontal region to decrease the prominence. Barrel stave cuts are made in the lateral bone at the base of the skull to allow more projection of the skull laterally, increasing the transverse width. This type of procedure gives a more definitive and immediate improvement in skull shape.



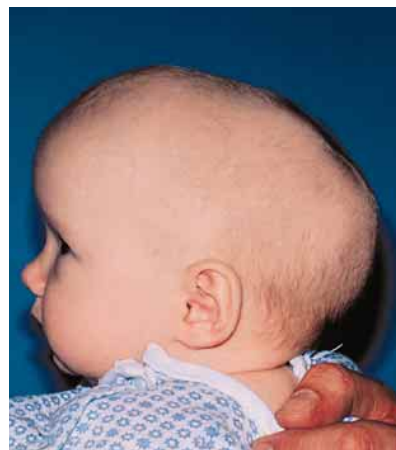Scaphocephaly



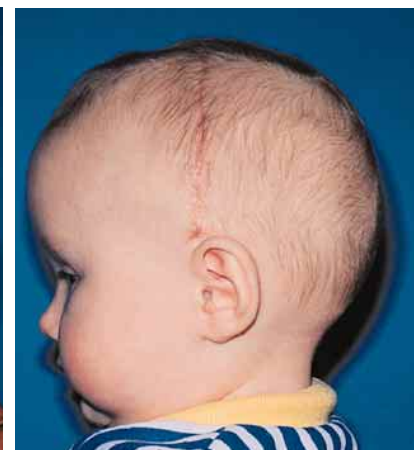Preoperative



Postoperative



Preoperative

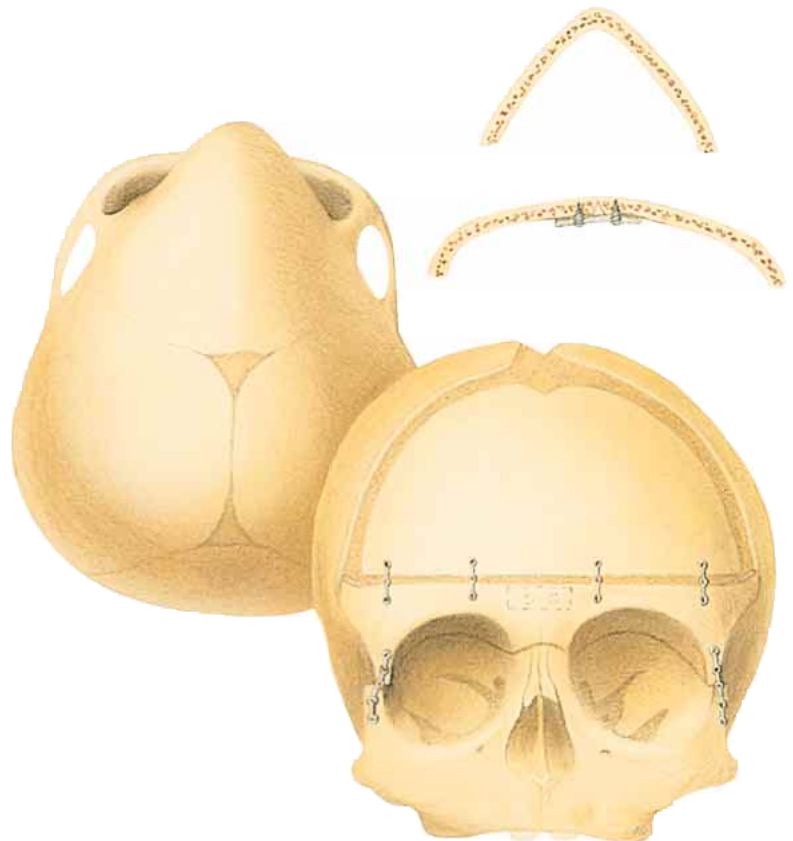

Postoperative

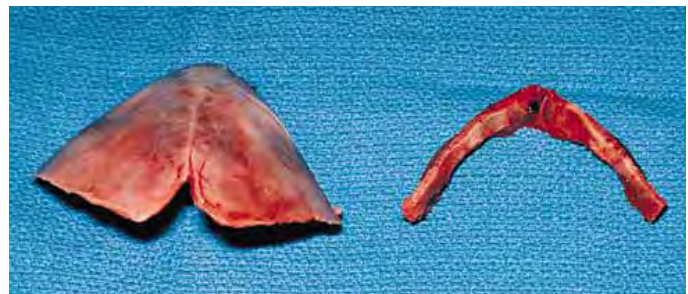METOPIC SYNOSTOSIS

The metopic suture runs down the midline of the forehead. Premature fusion of this suture results in a triangular shaped forehead called trigonocephaly. A bony ridge is usually palpable that extends from the bridge of the nose to the upper part of the forehead. This premature fusion produces a prominent midline keel with lateral recession of the brows. From the frontal view these patients typically have the appearance of hypotelorism or decreased distance between the eyes.

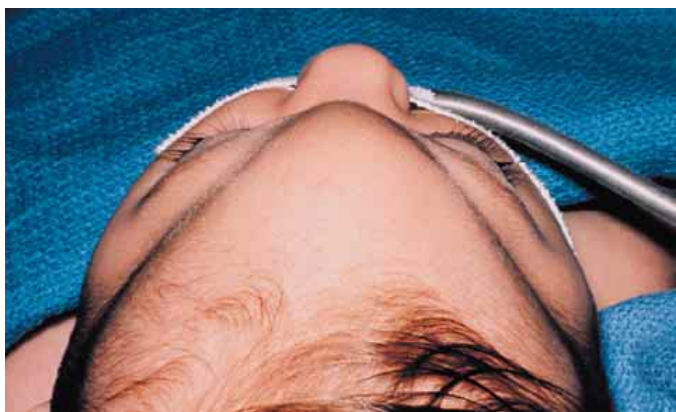
The incidence of metopic synostosis in most cases of craniosynostosis is between 5-10%. This deformity is usually obvious at birth, but the severity of the anomaly may vary. We prefer to correct these deformities between 4 and 8 months of age. Our current surgical treatment consists of frontal bone remodeling and supralateral orbital advancement. The triangular or keel-shaped forehead is removed and recontoured to the appropriate shape or bone may be taken from another area of the skull to replace this bone. The entire bony supraorbital bar is removed and reshaped with supralateral orbital advancement to restore the normal brow contour. Microplates are used to secure the frontal bar to the facial bones and maintain the normal contour.



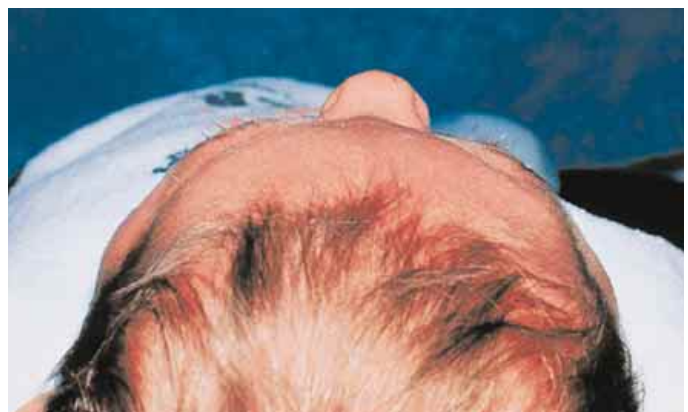Trigonocephaly



Intraoperative photograph of triangular shaped forehead (left) and brow (right).



Preoperative

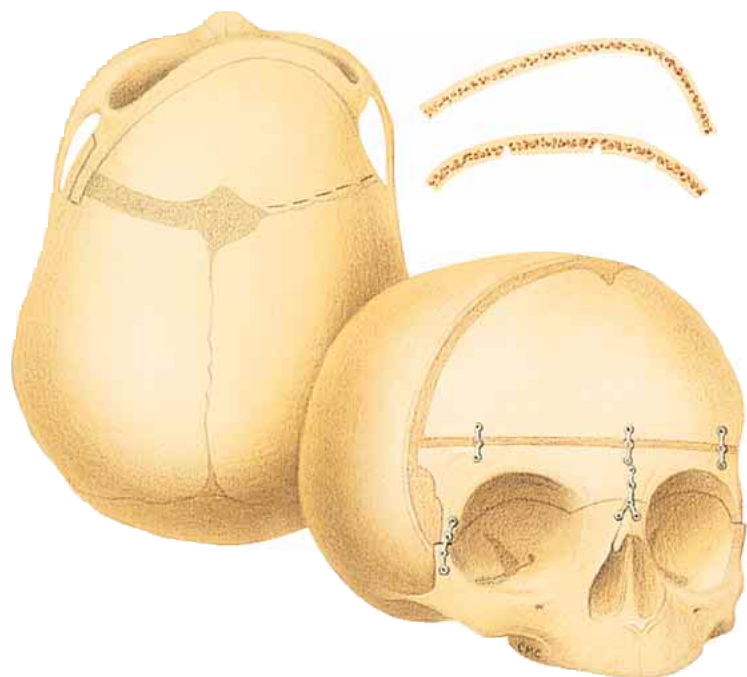


Postoperative

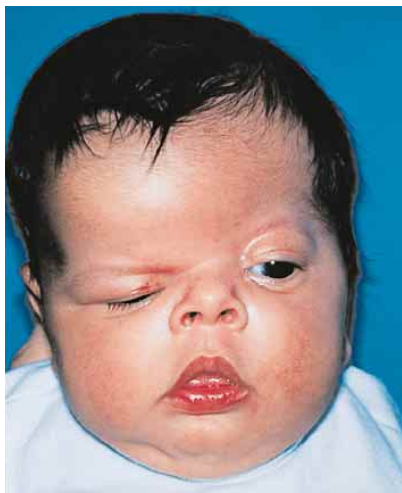UNILATERAL CORONAL SYNOSTOSIS

Premature fusion of one of the coronal sutures results in an asymmetric forehead and brow. On the affected side the forehead is flattened and recessed with the brow and supraorbital rim both elevated and recessed. The contralateral forehead may exhibit compensatory bulging or bossing. This ultimately results in a very asymmetric malformation called plagiocephaly. Technically, plagiocephaly refers to any type of asymmetric skull deformity. However, many authors have used this synonymously with unilateral coronal synostosis.

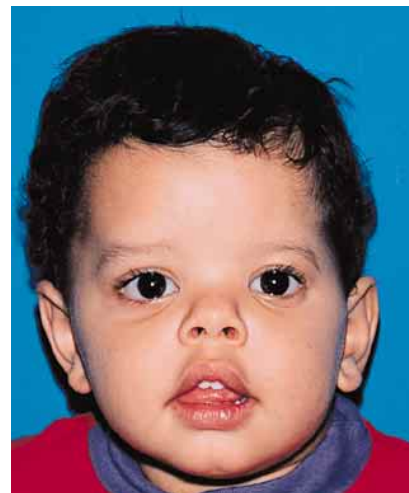The incidence of unilateral coronal synostosis in most series of craniosynostosis is between 10-20%. If untreated, this type of synostosis may result in a severe deformity of the forehead, orbit, and nose that persists or worsens with growth. We feel the best treatment for plagiocephaly should involve a bilateral approach with remodeling of the entire forehead and brow between the ages of 4 and 8 months. Our current surgical treatment consists of extended bicoronal craniectomies with bilateral frontal bone reconstruction. The supraorbital bar is completely removed, reshaped, and straightened. The supraorbital bar is advanced and lowered as necessary on the affected side and rigidly fixed in position to the face. The reconstructed forehead is then secured to the supraorbital bar. We feel that the bilateral approach obtains a more symmetric forehead and brow than the unilateral approach.



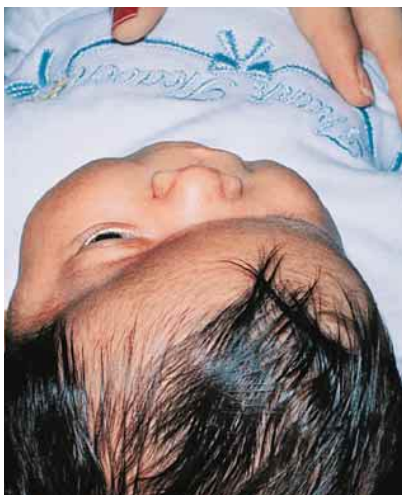Plagiocephaly



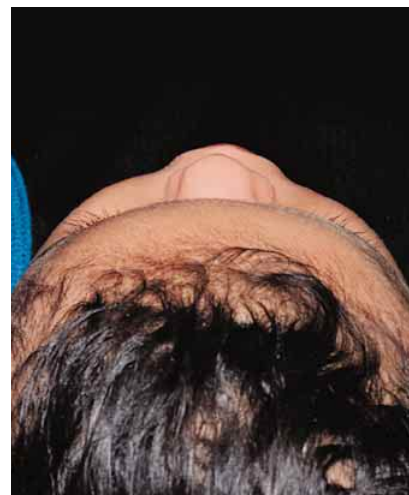Preoperative



Postoperative



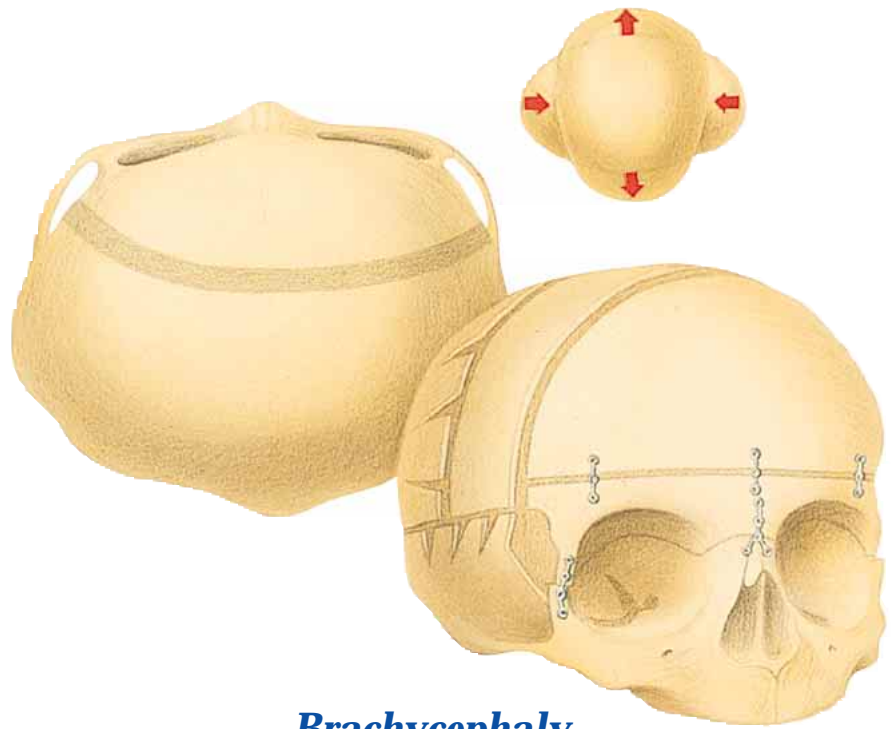
Preoperative



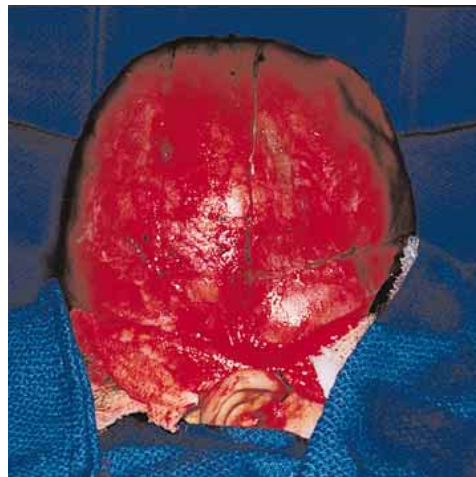
Postoperative

BICORONAL SYNOSTOSIS

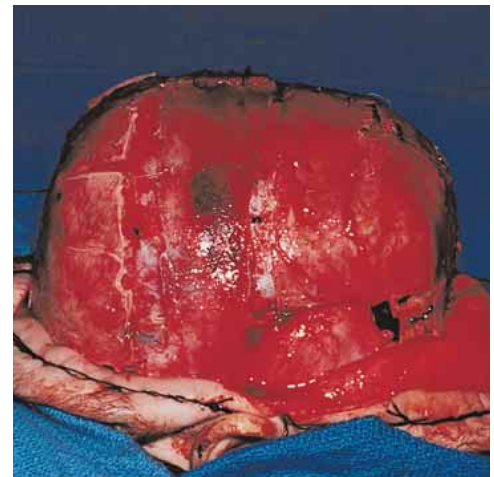Bicoronal suture fusion results in a flat retruded forehead with increased height to the skull. This condition is also called brachycephaly due to the short anteroposterior diameter. As a result of this shortening there is a compensatory bulging of the transverse diameter or width of the skull. The brow is usually recessed and elevated with the deformity being symmetric. The incidence of bicoronal synostosis or brachycephaly is between 10-20% in most series of craniosynostosis. This may occur as an isolated occurrence or part of a more complex syndrome with facial retrusion such as Apert's or Crouzon's. Surgical treatment consists of extended bicoronal craniectomies with reconstruction of the forehead. The supraorbital bar or brow is reshaped and advanced forward with the forehead. The reconstructed forehead and brow are rigidly fixed to the nose and lateral orbits with microplates. If there is excessive height to the skull then total calvarial remodeling is also performed, decreasing the height of the skull.



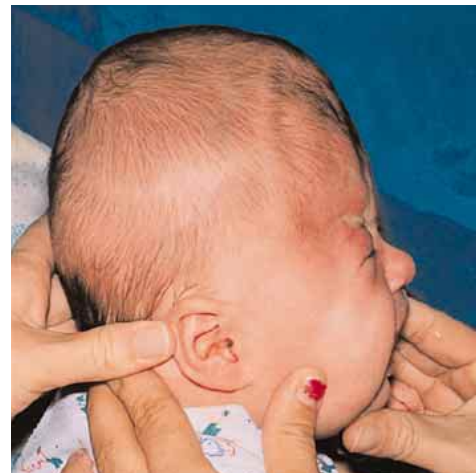Brachycephaly



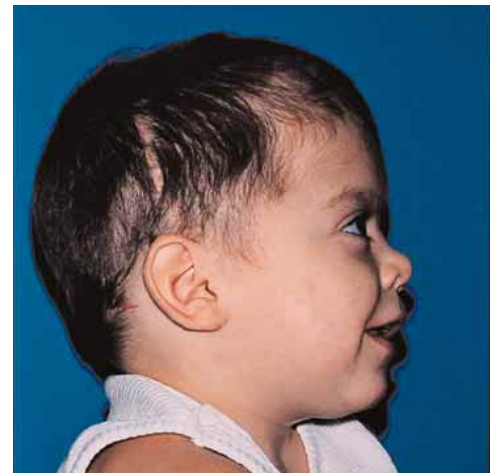Intraoperative lateral view of skull before remodeling.



Intraoperative lateral view of skull after remodeling.



Preoperative

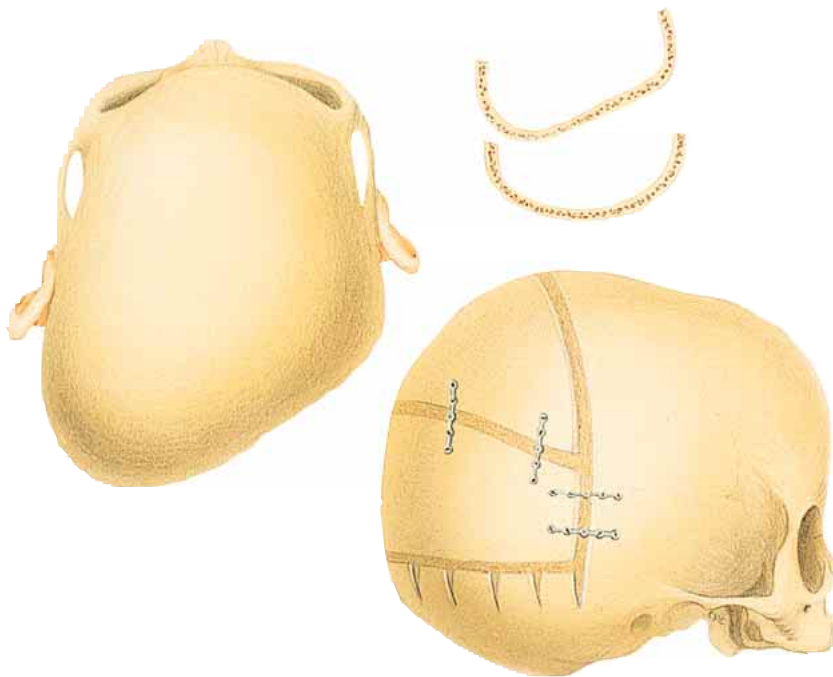


Postoperative

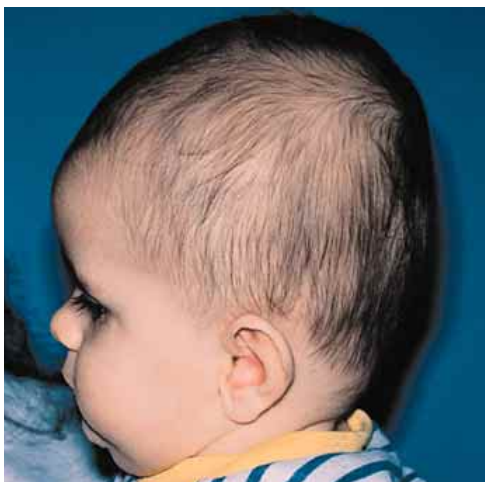POSTERIOR PLAGIOCEPHALY

There has been a significant increase in the past several years of infants referred for evaluation of occipital deformities. This increase in occurrence of posterior skull deformities appears to be related to the 1992 recommendation for supine sleep positioning by The American Academy of Pediatrics to avoid Sudden Infant Death Syndrome. Occiput deformities can be divided into lambdoid synostosis and deformational or positional plagiocephaly.

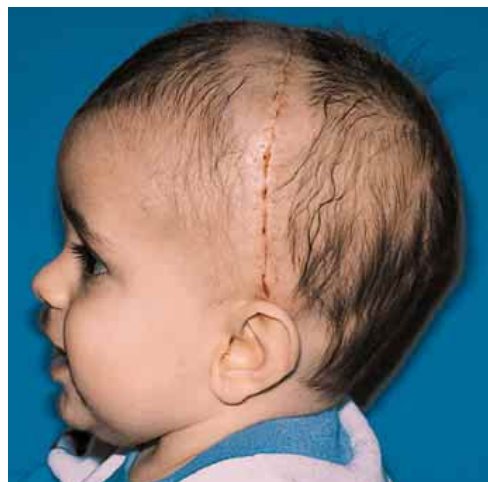The lambdoid suture is a paired structure that transverses in a symmetric



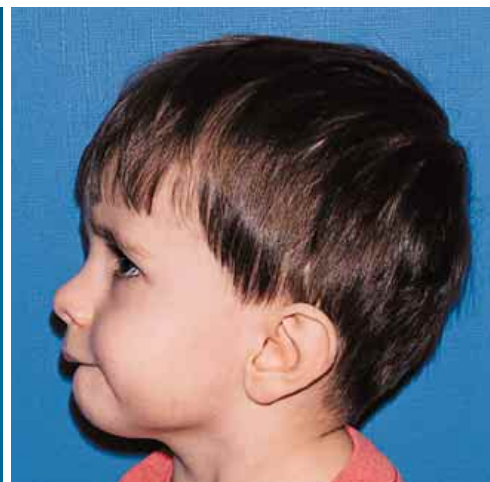Posterior Plagiocephaly



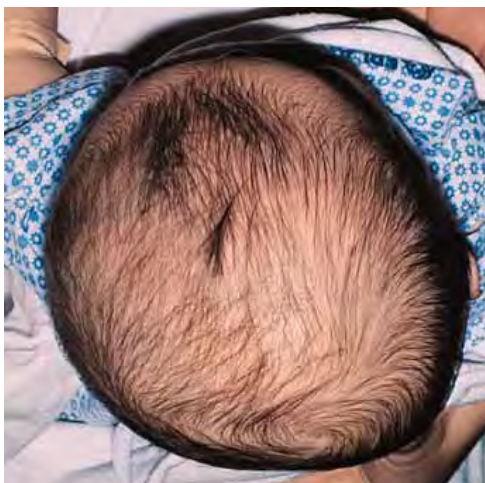Preoperative photo showing left posterior skull flattening.



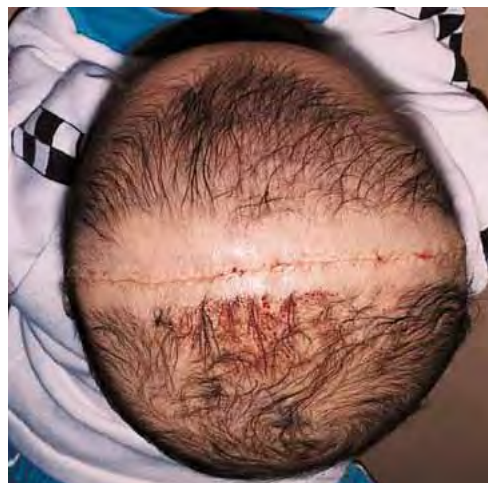Postoperative result after posterior skull remodeling.



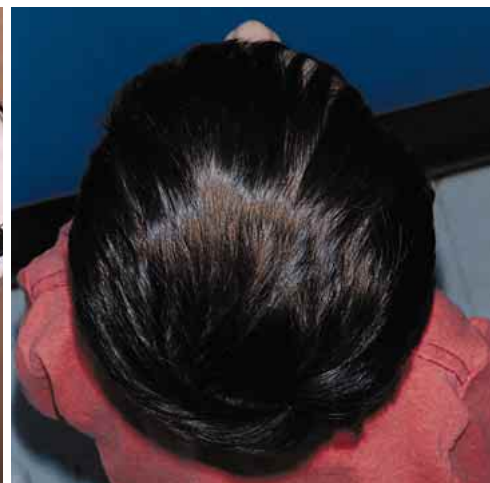Postoperative result after posterior skull remodeling.



Preoperative



Postoperative



Postoperative

fashion across the posterior aspect of the skull. Premature fusion or synostosis of this suture is rare but may be unilateral or bilateral.

Characteristically in unilateral synostosis the posterior skull is flattened on the involved side. Displacement of the ear with compensatory skull changes may be present in severe cases. Bilateral synostosis is characterized by extensive flattening across the posterior skull and increased vertical growth to accommodate brain enlargement. In mild cases the deformity can be covered by hair and surgical repair may not be indicated. When there is significant flattening or asymmetry, we recommend release of the fused sutures and posterior skull remodeling. Surgical treatment consists of extensive posterior skull craniectomies with remodeling of both sides of the occiput and posterior advancement of the affected side. Rigid fixation with microplates is used to hold the reconstructed bones in position and maintain the contour until healing takes place.

Occipital plagiocephaly without synostosis must be distinguished from lambdoid synostosis. Most patients referred to our center for posterior skull deformities are deformational or positional plagiocephaly. In these infants, the skull becomes misshaped from repeated pressure on the same position, without the premature fusion of the lambdoid suture. Positional plagiocephaly usually improves without surgery. Once the child's sleep patterns change and he spends more time awake, the brain's normal growth forces help to reshape the posterior skull. Some centers recommend a custom fitted helmet to mold the head back into position over a period of several months. However, in cases where the posterior skull deformity progresses or is severe, we recommend surgical remodeling as described, even though a true synostosis may not be present.

CRANIOFACIAL DYSOTOSIS

Craniofacial dysotosis (Crouzon's and Apert's diseases) are characterized by craniostenosis with cranial dysmorphia and facial deformities (hence, the term craniofacial dysotosis).

APERT SYNDROME

Apert syndrome or acrocephalosyndactyly syndromes are rare conditions. In 1906, Apert described the skull, facial, and hand deformities of several patients characteristic of this syndrome that now bears his name. The incidence of infants born with Apert syndrome is one for every 100,000 to 160,000 live births. Many of the infants born with this syndrome show a sporadic transmission, which means that a family may have a child with Apert's when no other members of the family are affected. The recurrent risk of having another child with Apert's for two unaffected parents is negligible. However, if the parent is affected there is a 50% chance of each offspring having Apert syndrome with both males and females affected equally.

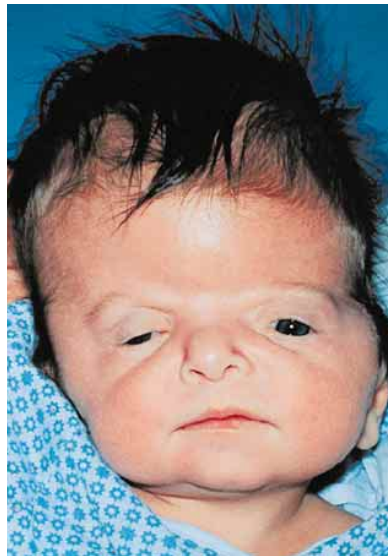Clinical Features: Patients with Apert syndrome have very distinct facial and extremity features. Abnormal skull shape is due to craniosynostosis or premature fusion of the sutures or soft spots. The skull usually demonstrates a short anteroposterior diameter (brachycephaly) and may be excessively tall (turriccephalic) or abnormally wide (euryprosopia). The forehead is generally always retruded, but this may not be obvious due to the hypoplasia of the midface. The orbits or bony sockets which contain the eyes are very shallow causing a bulging or proptosis. The orbits are usually rotated downward and lateral causing a downward shape to the lateral corners of the eyes. There may be a moderate increased distance between the eyes (hypertelorism) with muscle imbalance.

The middle of the face in Apert's is both retruded and very hypoplastic. This causes the central midface to have a characteristic sunken-

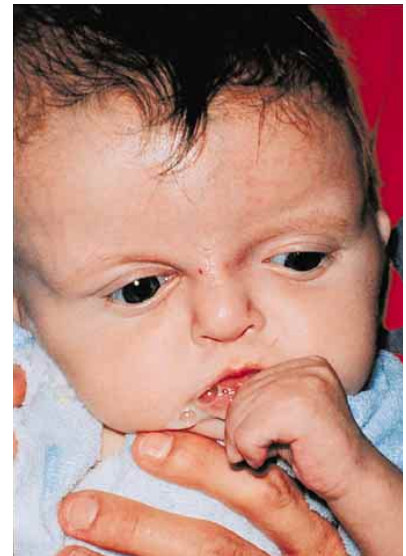
in appearance with the nose being thick and beaked. The upper jaw or maxilla characteristically shows a narrow arch with an open bite and dental crowding. The maxilla is significantly retruded compared to the mandible with the teeth of the lower jaw projecting in front of the upper teeth. Other possible clinical features include moderate hearing loss, speech impairment, acne, and decreased mental capability in some individuals. Intellectual potential may be difficult to evaluate due to communication problems. Some patients with Apert syndrome may have normal intelligence. All patients with Apert syndrome demonstrate a unique hand malformation. This is characterized by a complex syndactyly or fusion of the skin, soft tissue, and bones of the fingers. Both hands are affected equally, as are the feet. This unusual variation of syndactyly can be used to identify Apert's from other similar syndromes.

Treatment: The treatment of patients with Apert syndrome is not uniform due to significant variations in the facial anomalies, age of patients when first seen, and previous operations. Our primary concern of the infant born with this syndrome is: compression of the brain, breathing problems, protruding eyes with corneal exposure, and lack of facial growth. The surgical plan must be flexible and individualized to the patient. Multiple stages or operations at different ages are usually necessary.

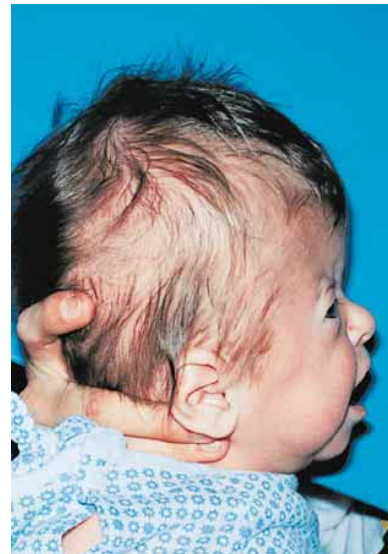When we see these patients as infants, the first stage is treatment of the craniosynostosis with total



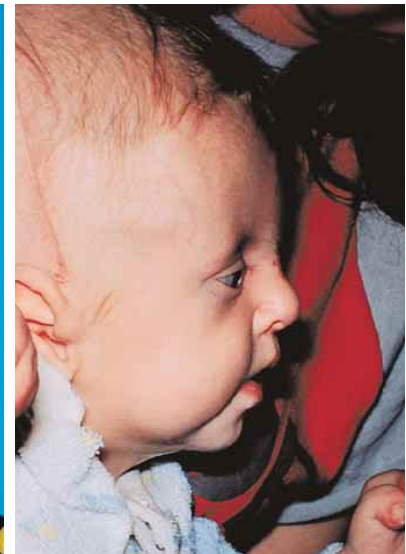Preoperative photo of infant with Apert syndrome.



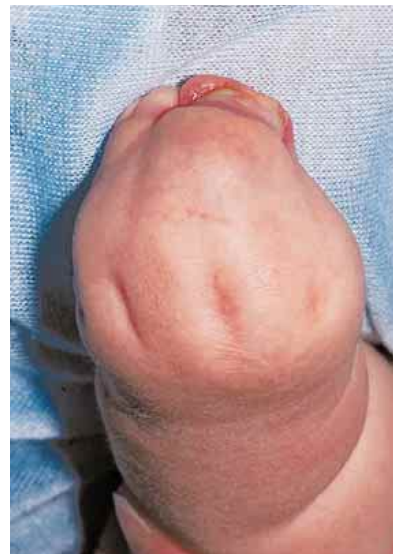Postoperative result after forehead and brow advancement.



Preoperative



Postoperative



Characteristic appearance of complex syndactyly of hand.

calvarial reshaping. We prefer to do this procedure at four to six months of age. A frontal-orbital advancement is performed which increases the intracranial space and size of both orbits. Total skull reshaping helps correct the tower skull problem which is not addressed by frontal-orbital advancement alone. A ventriculo-peritoneal shunt may be needed for treatment of a hydrocephalus. This is performed prior to skull remodeling. Occasionally a repeat craniotomy is needed to further reshape the calvarial vault and advance the orbits. The next stage of the reconstruction is midfacial advancement. We usually perform this procedure between the ages of four to six years old prior to starting school. If necessary, an intra/extracranial advancement of the entire face and forehead (monobloc) can be performed with correction of mild

hypertelorism or lateral rotation of the orbits. This procedure, as described by Tessier, is called a facial bipartition and corrects several deformities at once. It effectively widens the maxilla and derotates the orbits, and narrows the upper face. In milder cases an extracranial LeFort III advancement may be used.

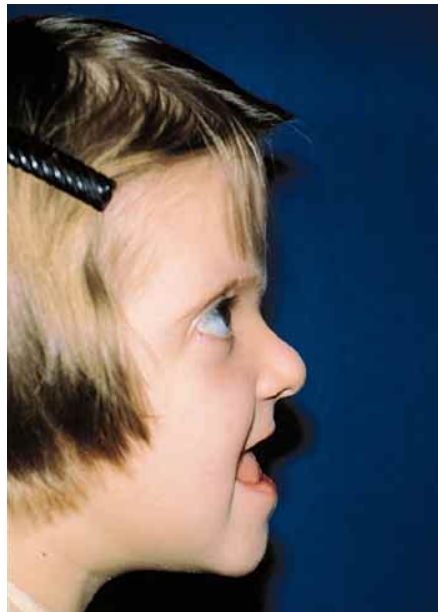The final steps in the reconstruction are maxillary/mandibular osteotomies to complete the correction of any further dental discrepancies. These procedures are usually performed after eruption of permanent dentition and completion of growth (teen years). Additional procedures such as rhinoplasty, genioplasty and eyelid surgery may be beneficial. Surgical separation of the fingers is usually started in the first year of life and completed by three to four years of age.

The patient with Apert syndrome represents a complex combination of multiple deformities. Our goal is to treat not only the function and physical problems but the psychosocial issues as

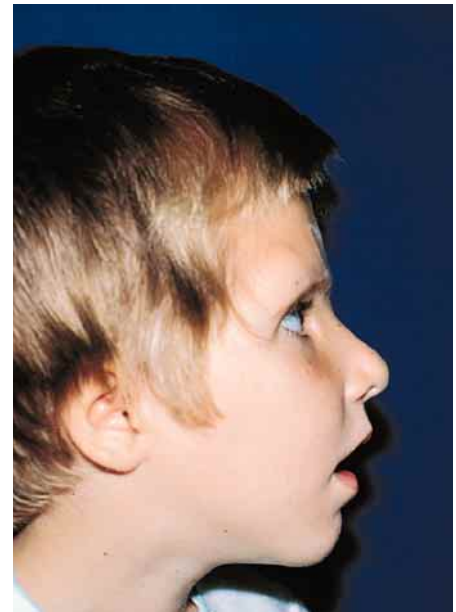Apert Syndrome



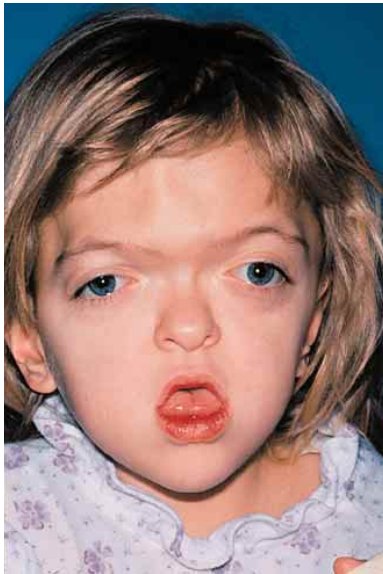This little girl has the characteristic facial appearance of Apert Syndrome which is also associated with complex syndactyly.



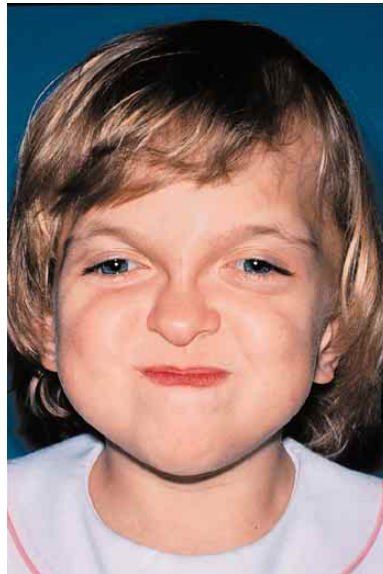Preoperative



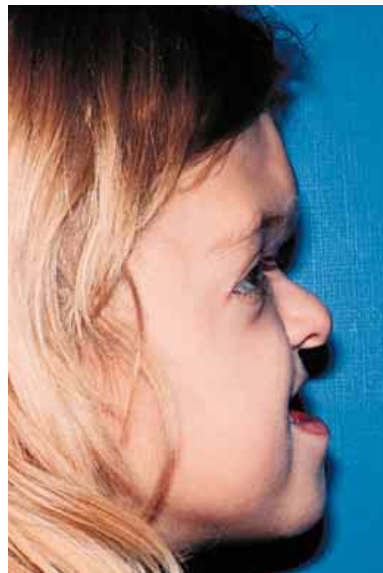Postoperative result after facial advancement.



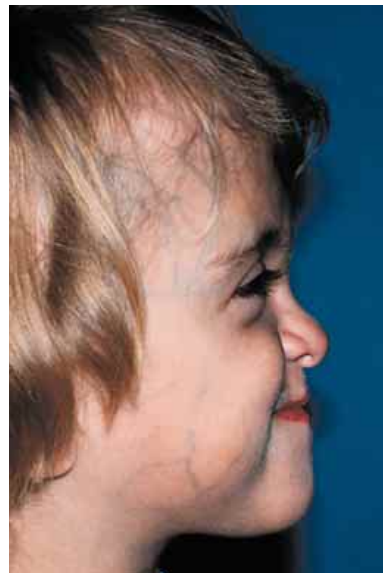Four year old girl with Apert syndrome.



Postoperative result after monobloc facial advancement with facial bipartition (medial rotation of orbits).



Preoperative



Postoperative

well. We feel these individuals are best evaluated and treated by a craniofacial center that utilizes the multidisciplinary team approach providing a coordinated, comprehensive, long-term treatment plan with careful monitoring of growth and development.

CROUZON SYNDROME

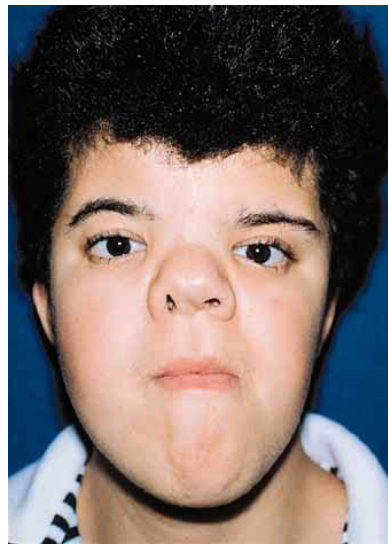This syndrome was originally described in 1912 by a French neurosurgeon. He described four essential characteristics: exorbitism, retromaxillism, inframaxillism and paradoxical retrogenia. The incidence of this syndrome appears to be approximately one in 25,000 in the general population. It is inherited as an autosomal dominant pattern with variable expression. However, approximately 25% of reported cases have no family history and represent a new mutation.

Clinical Features: Patients with Crouzon syndrome have very distinct facial features with craniofacial bone morphology similar to Apert syndrome. Premature fusion of the bicoronal suture is the most common type of craniosynostosis with a brachycephalic or oxycephalic appearance to the skull. The extent of the craniosynostosis may be variable as well as the age at onset. There is retrusion of both the forehead and brow, with midface hypoplasia and shallow orbits with bulging eyes (proptosis). Orbital hypertelorism is less commonly seen in Crouzon's than Apert's syndrome. The lateral canthi may be slanted downward with some degree of upper eyelid ptosis. The proptosis is usually more prominent in Crouzon's than Apert's; however, in Apert syndrome, the other craniofacial deformities are more complex and severe. In addition, hydrocephalus and developmental delay are less frequently seen in Crouzon's than Apert's. The nasomaxillary retrusion may cause some degree of nasal airway obstruction with mouth breath-

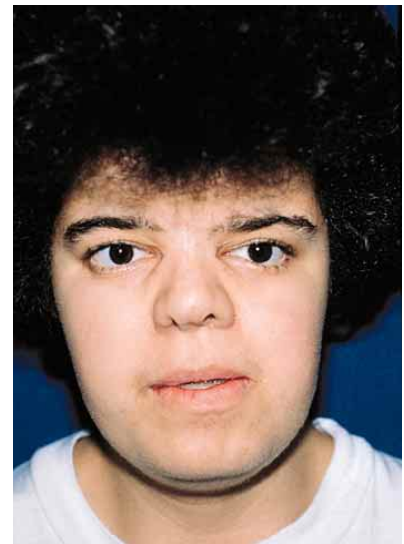
ing. The chin is usually large with increased vertical height but often retruded resulting in a paradoxical retrogenia. The maxillary teeth are retruded compared to the mandible with a class III malocclusion. Other possible abnormalities include conductive hearing loss, inverted V-shape to palate and exposure keratitis. Variations of this type of craniofacial dysostosis are seen in the syndromes of Carpenter, Pfeiffer and Saethre-Chotzens.

Treatment: Our approach to the treatment of Crouzon syndrome is similar to that described for Apert syndrome. The first stage involves treatment of the craniosynostosis with total calvarial reshaping as needed and frontal-orbital advancement. This procedure is usually performed at four to six months of age and is effective in increasing the intracranial space and enlarging the orbits. It is not unusual for a ventriculo-peritoneal shunt to be needed for treatment of a hydrocephalus. Occasionally, a repeat craniotomy will be needed in infancy to further reshape the calvarial vault and advance the orbits. The next stage of reconstruction is midface advancement performed at four to six years of age. This type of advancement can be accomplished with either a LeFort III or a monobloc (entire face and forehead) osteotomy. The position of the forehead and brow determines which procedure would be the best alternative. If necessary, the monobloc osteotomy can be further split in the midline to correct orbital hypertelorism (facial bipartition).

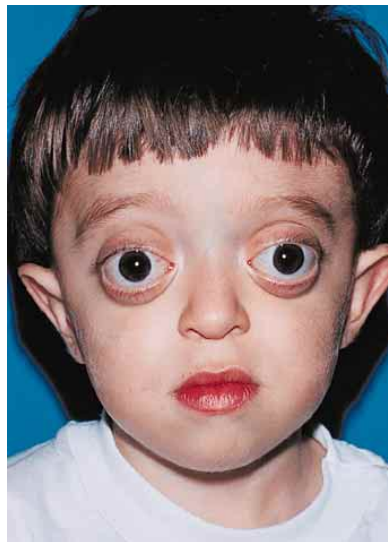The final stage of the reconstruction is management of the dental class III malocclusion. A LeFort I



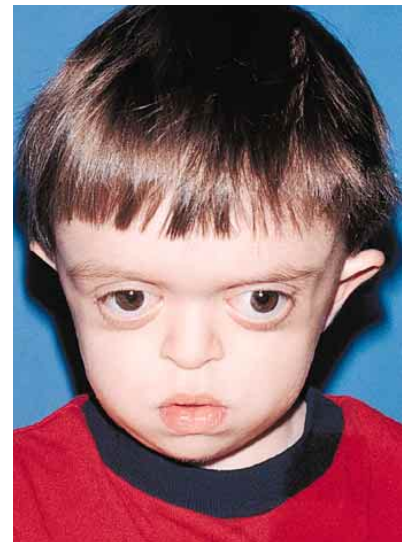Young woman with Crouzon's Syndrome.



Result after correction of orbital hypertelorism, maxillary advancement, mandibular setback and chin reduction.



Two year old boy with Crouzon's syndrome who exhibits severe proptosis.



Postoperative appearance after forehead-brow advancement. A Lefort III advancement will be needed in the future.

osteotomy is used to correct the dental discrepancies in combination with orthodontic intervention. This is usually performed after facial growth is completed and may be combined with a genioplasty (chin reduction/advancement). Additional procedures such as rhinoplasty may be needed.

fashion across the posterior aspect of the skull. Premature fusion or synostosis of this suture is rare but may be unilateral or bilateral.

Characteristically in unilateral synostosis the posterior skull is flattened on the involved side. Displacement of the ear with compensatory skull changes may be present in severe cases. Bilateral synostosis is characterized by extensive flattening across the posterior skull and increased vertical growth to accommodate brain enlargement. In mild cases the deformity can be covered by hair and surgical repair may not be indicated. When there is significant flattening or asymmetry, we recommend release of the fused sutures and posterior skull remodeling. Surgical treatment consists of extensive posterior skull craniectomies with remodeling of both sides of the occiput and posterior advancement of the affected side. Rigid fixation with microplates is used to hold the reconstructed bones in position and maintain the contour until healing takes place.

Occipital plagiocephaly without synostosis must be distinguished from lambdoid synostosis. Most patients referred to our center for posterior skull deformities are deformational or positional plagiocephaly. In these infants, the skull becomes misshaped from repeated pressure on the same position, without the premature fusion of the lambdoid suture. Positional plagiocephaly usually improves without surgery. Once the child's sleep patterns change and he spends more time awake, the brain's normal growth forces help to reshape the posterior skull. Some centers recommend a custom fitted helmet to mold the head back into position over a period of several months. However, in cases where the posterior skull deformity progresses or is severe, we recommend surgical remodeling as described, even though a true synostosis may not be present.

CRANIOFACIAL DYSOTOSIS

Craniofacial dysotosis (Crouzon's and Apert's diseases) are characterized by craniostenosis with cranial dysmorphism and facial deformities (hence, the term craniofacial dysotosis).

APERT SYNDROME

Apert syndrome or acrocephalosyndactyly syndromes are rare conditions. In 1906, Apert described the skull, facial, and hand deformities of several patients characteristic of this syndrome that now bears his name. The incidence of infants born with Apert syndrome is one for every 100,000 to 160,000 live births. Many of the infants born with this syndrome show a sporadic transmission, which means that a family may have a child with Apert's when no other members of the family are affected. The recurrent risk of having another child with Apert's for two unaffected parents is negligible. However, if the parent is affected there is a 50% chance of each offspring having Apert syndrome with both males and females affected equally.

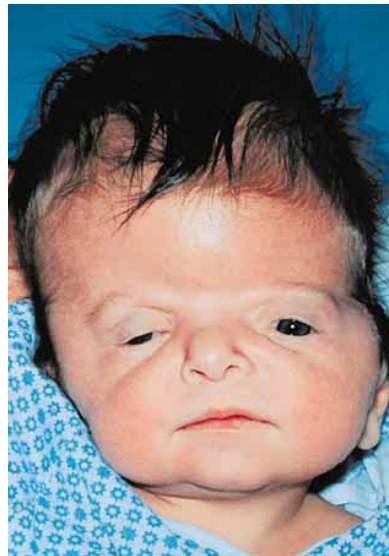Clinical Features: Patients with Apert syndrome have very distinct facial and extremity features. Abnormal skull shape is due to craniosynostosis or premature fusion of the sutures or soft spots. The skull usually demonstrates a short anteroposterior diameter (brachycephaly) and may be excessively tall (turriccephalic) or abnormally wide (euryprosopia). The forehead is generally always retruded, but this may not be obvious due to the hypoplasia of the midface. The orbits or bony sockets which contain the eyes are very shallow causing a bulging or proptosis. The orbits are usually rotated downward and lateral causing a downward shape to the lateral corners of the eyes. There may be a moderate increased distance between the eyes (hypertelorism) with muscle imbalance.

The middle of the face in Apert's is both retruded and very hypoplastic. This causes the central midface to have a characteristic sunken-

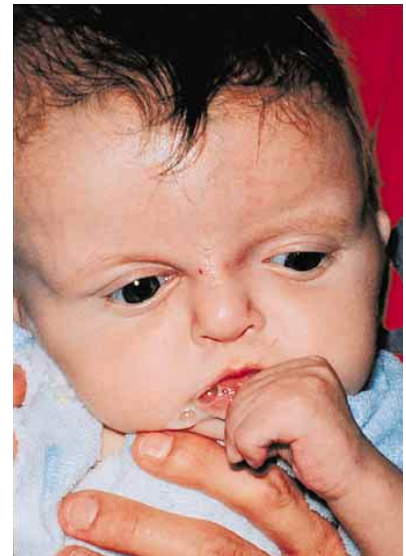
in appearance with the nose being thick and beaked. The upper jaw or maxilla characteristically shows a narrow arch with an open bite and dental crowding. The maxilla is significantly retruded compared to the mandible with the teeth of the lower jaw projecting in front of the upper teeth. Other possible clinical features include moderate hearing loss, speech impairment, acne, and decreased mental capability in some individuals. Intellectual potential may be difficult to evaluate due to communication problems. Some patients with Apert syndrome may have normal intelligence. All patients with Apert syndrome demonstrate a unique hand malformation. This is characterized by a complex syndactyly or fusion of the skin, soft tissue, and bones of the fingers. Both hands are affected equally, as are the feet. This unusual variation of syndactyly can be used to identify Apert's from other similar syndromes.

Treatment: The treatment of patients with Apert syndrome is not uniform due to significant variations in the facial anomalies, age of patients when first seen, and previous operations. Our primary concern of the infant born with this syndrome is: compression of the brain, breathing problems, protruding eyes with corneal exposure, and lack of facial growth. The surgical plan must be flexible and individualized to the patient. Multiple stages or operations at different ages are usually necessary.

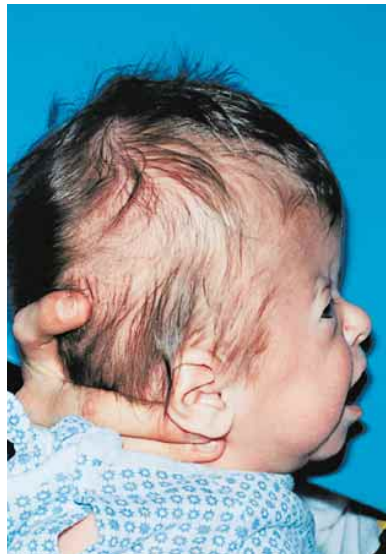When we see these patients as infants, the first stage is treatment of the craniosynostosis with total



Preoperative photo of infant with Apert syndrome.



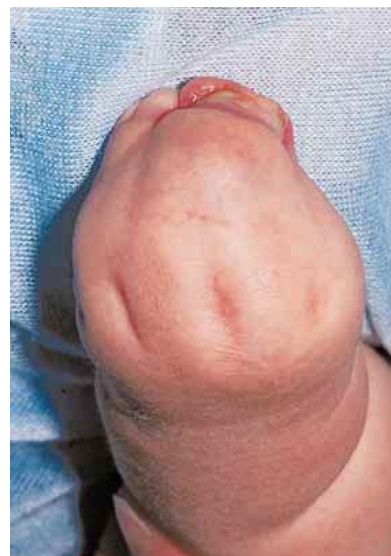Postoperative result after forehead and brow advancement.



Preoperative



Postoperative



Characteristic appearance of complex syndactyly of hand.

calvarial reshaping. We prefer to do this procedure at four to six months of age. A frontal-orbital advancement is performed which increases the intracranial space and size of both orbits. Total skull reshaping helps correct the tower skull problem which is not addressed by frontal-orbital advancement alone. A ventriculo-peritoneal shunt may be needed for treatment of a hydrocephalus. This is performed prior to skull remodeling. Occasionally a repeat craniotomy is needed to further reshape the calvarial vault and advance the orbits. The next stage of the reconstruction is midfacial advancement. We usually perform this procedure between the ages of four to six years old prior to starting school. If necessary, an intra/extracranial advancement of the entire face and forehead (monobloc) can be performed with correction of mild

hypertelorism or lateral rotation of the orbits. This procedure, as described by Tessier, is called a facial bipartition and corrects several deformities at once. It effectively widens the maxilla and derotates the orbits, and narrows the upper face. In milder cases an extracranial LeFort III advancement may be used.

The final steps in the reconstruction are maxillary/mandibular osteotomies to complete the correction of any further dental discrepancies. These procedures are usually performed after eruption of permanent dentition and completion of growth (teen years). Additional procedures such as rhinoplasty, genioplasty and eyelid surgery may be beneficial. Surgical separation of the fingers is usually started in the first year of life and completed by three to four years of age.

The patient with Apert syndrome represents a complex combination of multiple deformities. Our goal is to treat not only the function and physical problems but the psychosocial issues as

Apert Syndrome



This little girl has the characteristic facial appearance of Apert Syndrome which is also associated with complex syndactyly.



Preoperative



Postoperative result after facial advancement.



Four year old girl with Apert syndrome.



Postoperative result after monobloc facial advancement with facial bipartition (medial rotation of orbits).



Preoperative



Postoperative

well. We feel these individuals are best evaluated and treated by a craniofacial center that utilizes the multidisciplinary team approach providing a coordinated, comprehensive, long-term treatment plan with careful monitoring of growth and development.

CROUZON SYNDROME

This syndrome was originally described in 1912 by a French neurosurgeon. He described four essential characteristics: exorbitism, retromaxillism, inframaxillism and paradoxical retrogenia. The incidence of this syndrome appears to be approximately one in 25,000 in the general population. It is inherited as an autosomal dominant pattern with variable expression. However, approximately 25% of reported cases have no family history and represent a new mutation.

Clinical Features: Patients with Crouzon syndrome have very distinct facial features with craniofacial bone morphology similar to Apert syndrome. Premature fusion of the bicoronal suture is the most common type of craniosynostosis with a brachycephalic or oxycephalic appearance to the skull. The extent of the craniosynostosis may be variable as well as the age at onset. There is retrusion of both the forehead and brow, with midface hypoplasia and shallow orbits with bulging eyes (proptosis). Orbital hypertelorism is less commonly seen in Crouzon's than Apert's syndrome. The lateral canthi may be slanted downward with some degree of upper eyelid ptosis. The proptosis is usually more prominent in Crouzon's than Apert's; however, in Apert syndrome, the other craniofacial deformities are more complex and severe. In addition, hydrocephalus and developmental delay are less frequently seen in Crouzon's than Apert's. The nasomaxillary retrusion may cause some degree of nasal airway obstruction with mouth breath-



Four year old girl with Apert syndrome.



Postoperative result after monobloc facial advancement with facial bipartition (medial rotation of orbits).



Preoperative



Postoperative

well. We feel these individuals are best evaluated and treated by a craniofacial center that utilizes the multidisciplinary team approach providing a coordinated, comprehensive, long-term treatment plan with careful monitoring of growth and development.

CROUZON SYNDROME

This syndrome was originally described in 1912 by a French neurosurgeon. He described four essential characteristics: exorbitism, retromaxillism, inframaxillism and paradoxical retrogenia. The incidence of this syndrome appears to be approximately one in 25,000 in the general population. It is inherited as an autosomal dominant pattern with variable expression. However, approximately 25% of reported cases have no family history and represent a new mutation.

Clinical Features: Patients with Crouzon syndrome have very distinct facial features with craniofacial bone morphology similar to Apert syndrome. Premature fusion of the bicoronal suture is the most common type of craniosynostosis with a brachycephalic or oxycephalic appearance to the skull. The extent of the craniosynostosis may be variable as well as the age at onset. There is retrusion of both the forehead and brow, with midface hypoplasia and shallow orbits with bulging eyes (proptosis). Orbital hypertelorism is less commonly seen in Crouzon's than Apert's syndrome. The lateral canthi may be slanted downward with some degree of upper eyelid ptosis. The proptosis is usually more prominent in Crouzon's than Apert's; however, in Apert syndrome, the other craniofacial deformities are more complex and severe. In addition, hydrocephalus and developmental delay are less frequently seen in Crouzon's than Apert's. The nasomaxillary retrusion may cause some degree of nasal airway obstruction with mouth breath-

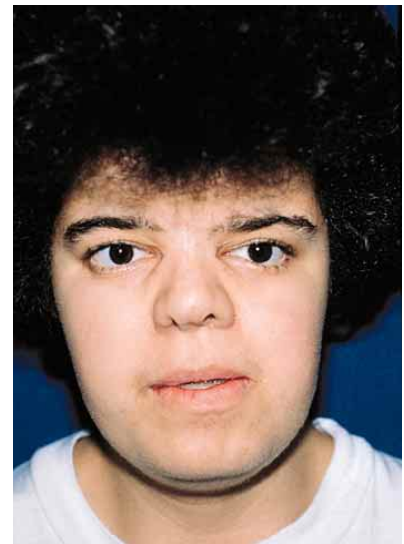
ing. The chin is usually large with increased vertical height but often retruded resulting in a paradoxical retrogenia. The maxillary teeth are retruded compared to the mandible with a class III malocclusion. Other possible abnormalities include conductive hearing loss, inverted V-shape to palate and exposure keratitis. Variations of this type of craniofacial dysostosis are seen in the syndromes of Carpenter, Pfeiffer and Saethre-Chotzens.

Treatment: Our approach to the treatment of Crouzon syndrome is similar to that described for Apert syndrome. The first stage involves treatment of the craniosynostosis with total calvarial reshaping as needed and frontal-orbital advancement. This procedure is usually performed at four to six months of age and is effective in increasing the intracranial space and enlarging the orbits. It is not unusual for a ventriculo-peritoneal shunt to be needed for treatment of a hydrocephalus. Occasionally, a repeat craniotomy will be needed in infancy to further reshape the calvarial vault and advance the orbits. The next stage of reconstruction is midface advancement performed at four to six years of age. This type of advancement can be accomplished with either a LeFort III or a monobloc (entire face and forehead) osteotomy. The position of the forehead and brow determines which procedure would be the best alternative. If necessary, the monobloc osteotomy can be further split in the midline to correct orbital hypertelorism (facial bipartition).

The final stage of the reconstruction is management of the dental class III malocclusion. A LeFort I



Young woman with Crouzon's Syndrome.



Result after correction of orbital hypertelorism, maxillary advancement, mandibular setback and chin reduction.



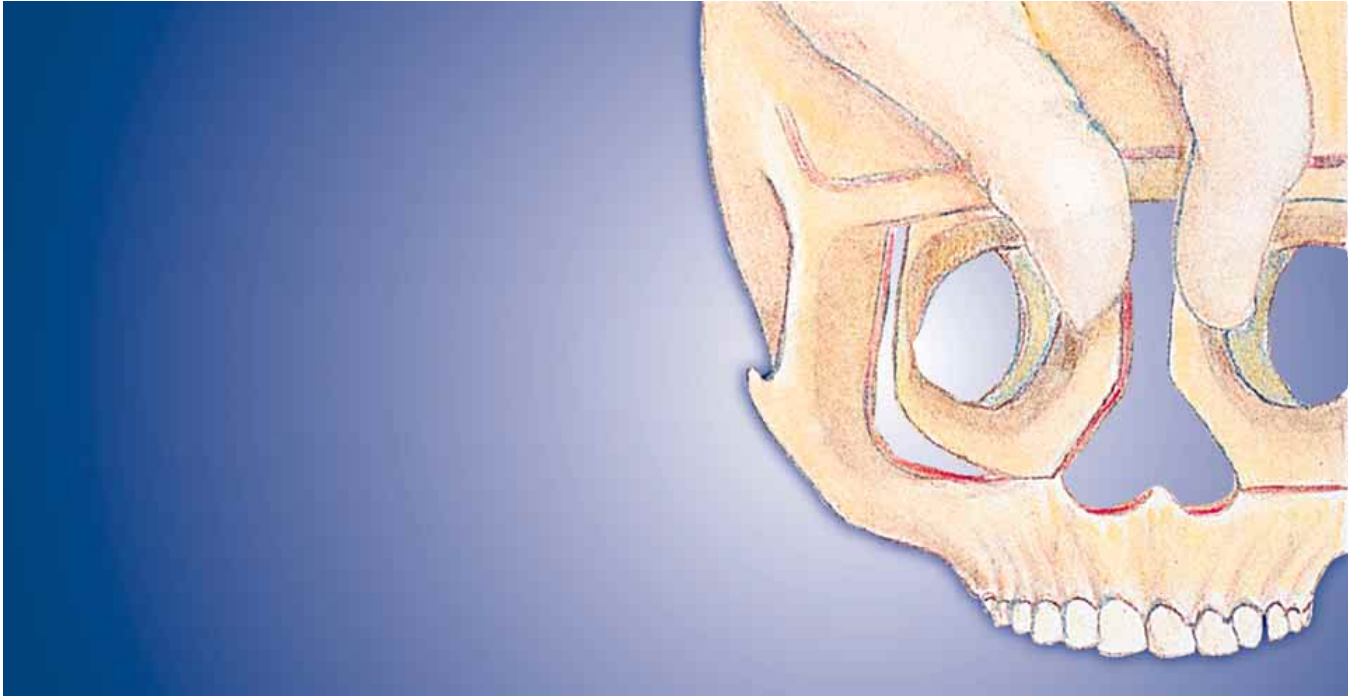
Two year old boy with Crouzon's syndrome who exhibits severe proptosis.



Postoperative appearance after forehead-brow advancement. A Lefort III advancement will be needed in the future.

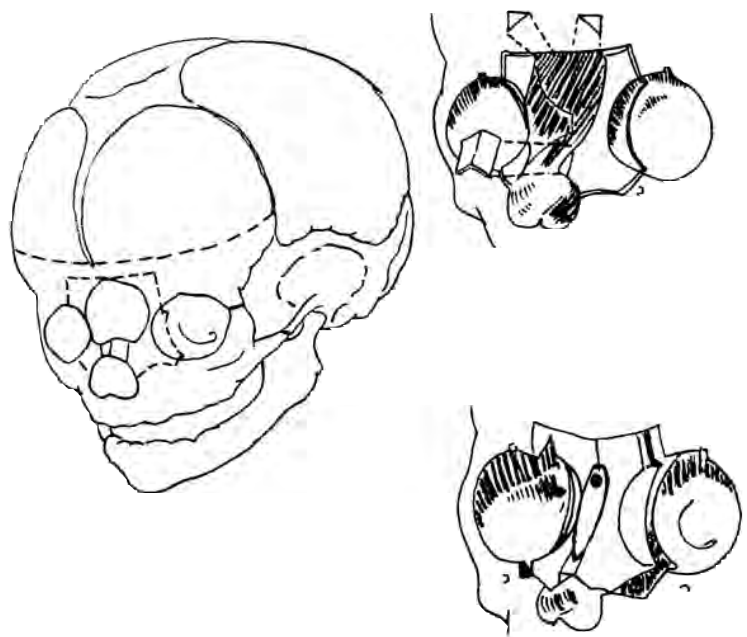
osteotomy is used to correct the dental discrepancies in combination with orthodontic intervention. This is usually performed after facial growth is completed and may be combined with a genioplasty (chin reduction/advancement). Additional procedures such as rhinoplasty may be needed.

Orbital Reconstruction



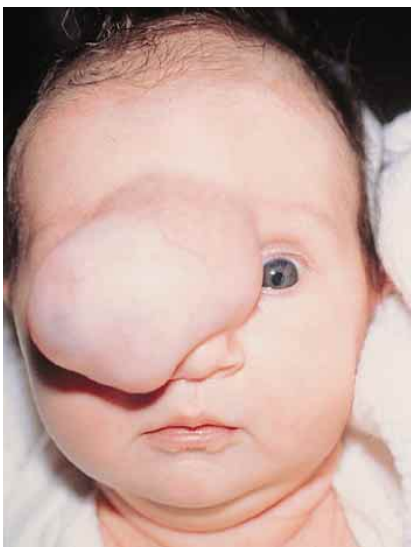ORBITAL RECONSTRUCTION

Encephalocele: Congenital nasal encephaloceles are complex problems that are best treated by the combined efforts of a neurosurgeon and a plastic surgeon. An encephalocele is the herniation of the brain through a congenital or traumatic opening in the cranium. Alterations and distortions of the surrounding facial structures, such as deformities of the naso-orbital skeleton due to an absence or separation of bone in the midline of the face, are complications of encephaloceles due to their position and size. Comprehensive treatment includes resecting the encephalocele, repairing the fibrous covering of the brain, repairing any bony defects, and reconstructing a more normal soft tissue facial appearance. With recent advances in diagnostic and surgical techniques, it is possible to perform a thorough preoperative evaluation and to treat the lesion with definitive one-stage reconstruction at the time of excision.

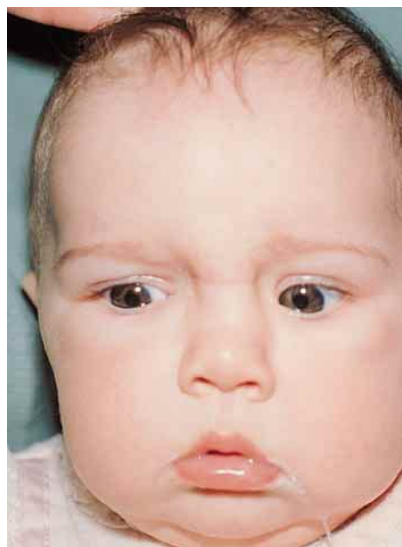

The nasofrontal encephalocele bone defect is shown with osteotomies for mobilization of the medial orbital walls illustrated. The orbital walls are centrally mobilized and then stabilized and the remaining defects bone grafted.

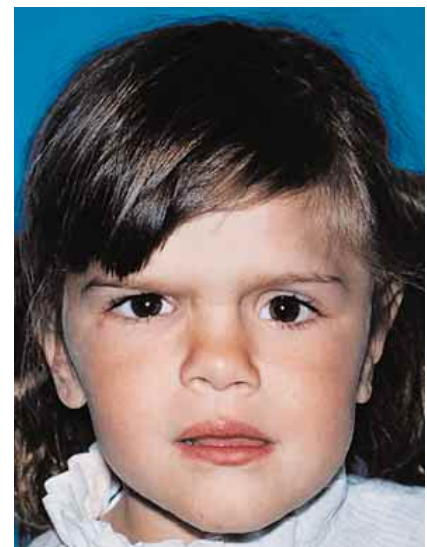Nasal Encephalocele



A one week old infant born with large nasal encephalocele.

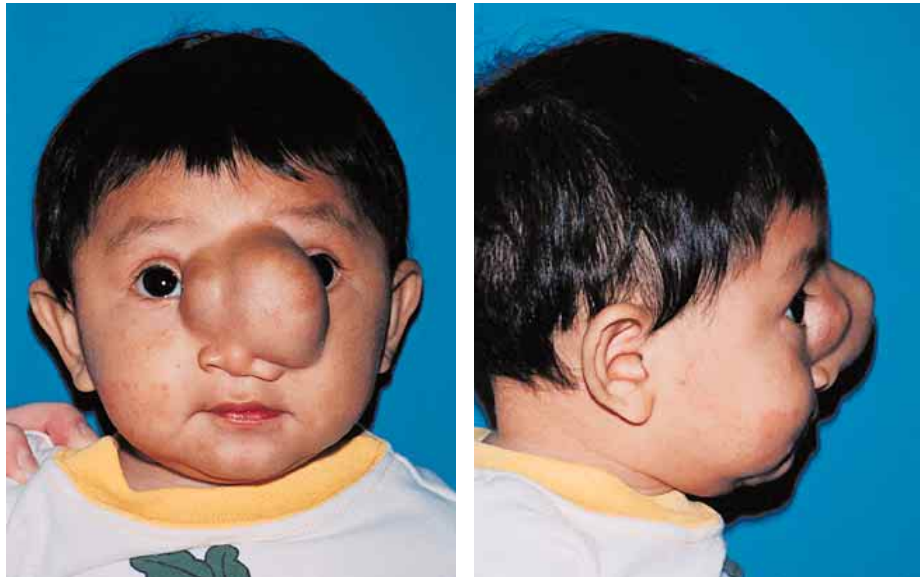

Postoperative result at eight months.

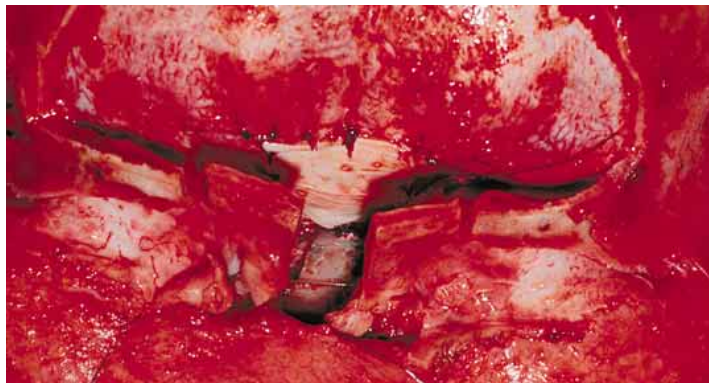


Postoperative result at five years after definitive one stage construction.

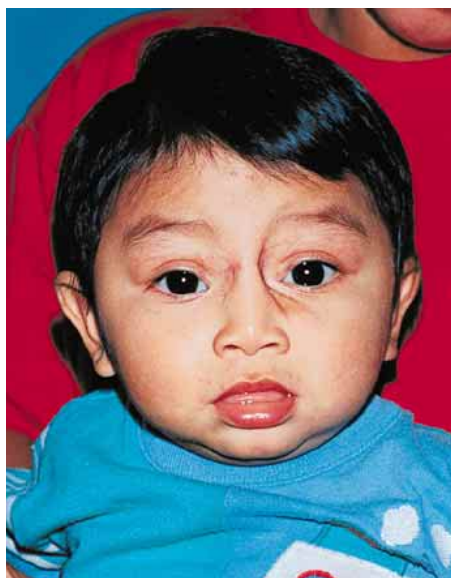Nasal Encephalocele



Seven month old boy born with large nasal encephalocele.



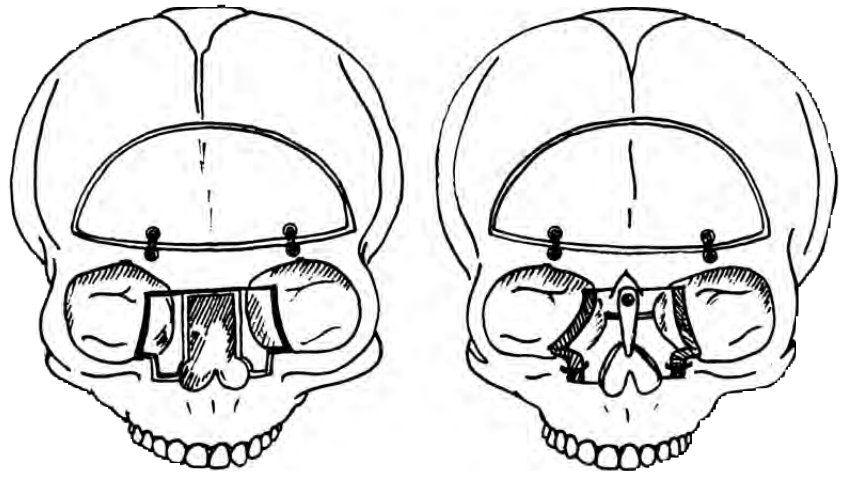
Intraoperative excision of encephalocele and bony reconstruction.



Postoperative result after definitive one stage reconstruction.

ORBITAL HYPERTELORISM

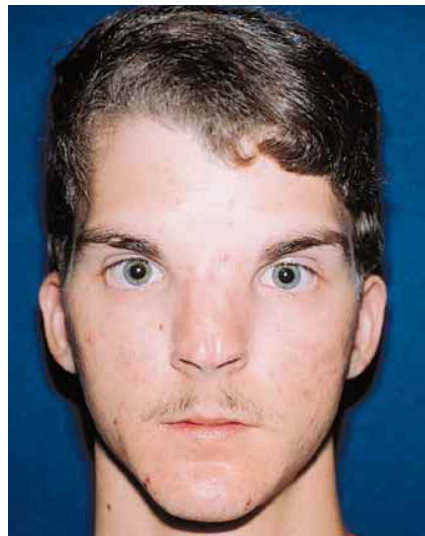
Orbital hypertelorism represents an increased interorbital distance and is most commonly associated with craniofacial dysostosis (Apert's and Crouzon's diseases), encephaloceles, facial clefts, and fronto-nasal dysplasias. The treatment of moderate to severe deformities involves surgery to reduce the interorbital distance and to correct any nasal abnormalities by way of an intracranial surgical approach that releases the bony orbits of the eyes and repositions them closer together. Inlay bone grafts, secured in place with mini-plate fixation, are then placed



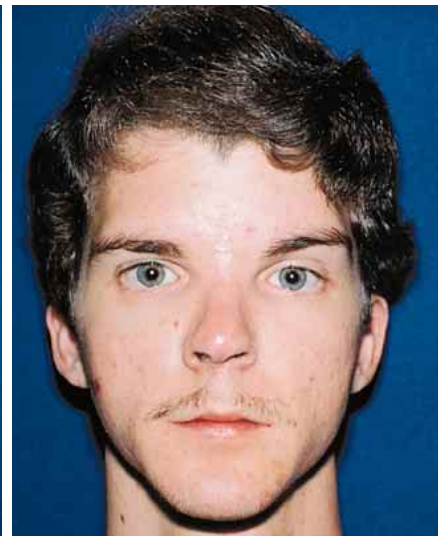Orbital Hypertelorism

Illustration Upper Right:

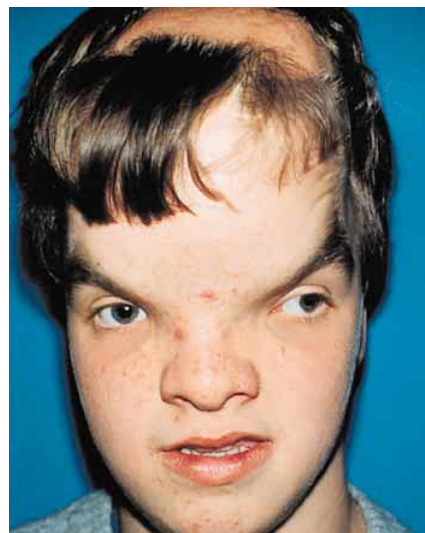Extracranial/Intracranial correction of orbital hypertelorism. Orbital wall osteotomies are illustrated with mobilization medially. The remaining defects are bone grafted. A frontal bone flap is usually not necessary using this technique.



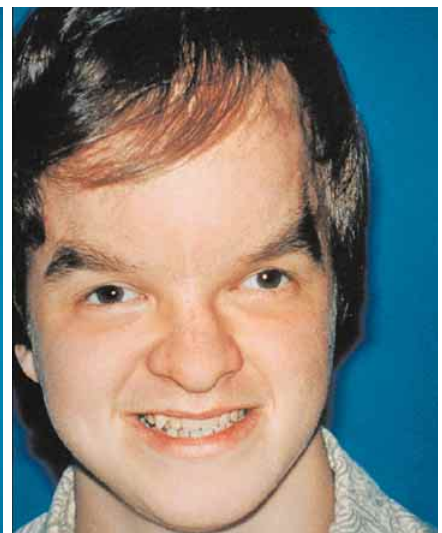
Fifteen year old male born with incomplete midline facial cleft causing increased distance between eyes.



Postoperative result after extracranial reconstruction of hypertelorism.

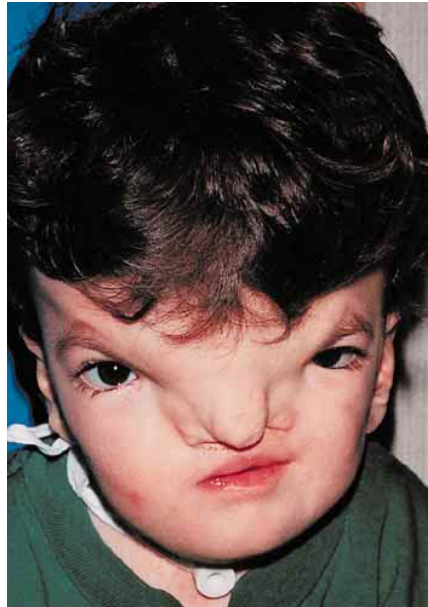


Thirteen year old male with severe orbital hypertelorism and abnormal forehead contour.

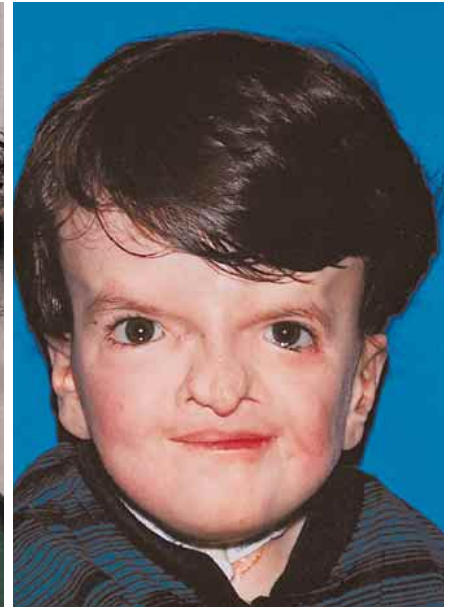

Postoperative result two years after intracranial reconstruction of orbital hypertelorism with forehead remodeling.

to provide structural support and to fill the spaces left by moving the orbits. The ideal timing for this surgery is between two and five years of age in order for the psychological trauma involved with the deformity to be minimized while maximizing the ophthalmological benefits. In cases where the deformity from hypertelorism is less severe, the surgery can be performed using an extracranial approach to achieve orbital rearrangement. However, it is generally agreed that using the intracranial technique constitutes a more consistent and safer method of correcting the malformation.

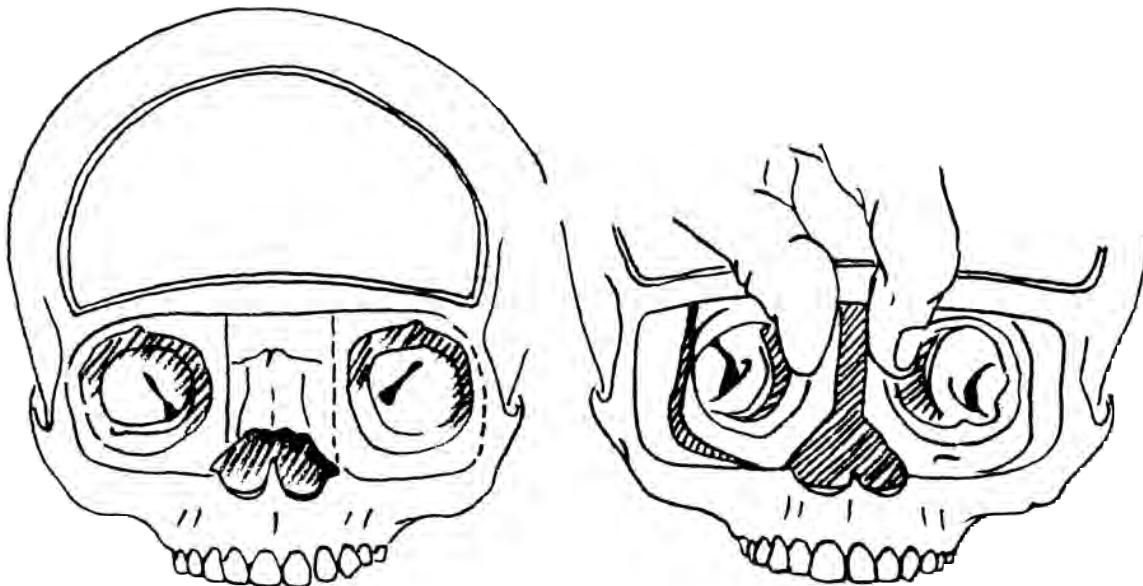


Four year old boy with the severest form of orbital hypertelorism.



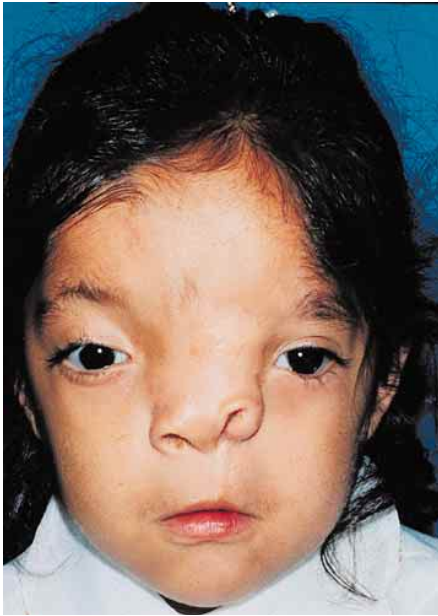Postoperative result

Intracranial correction of orbital hypertelorism

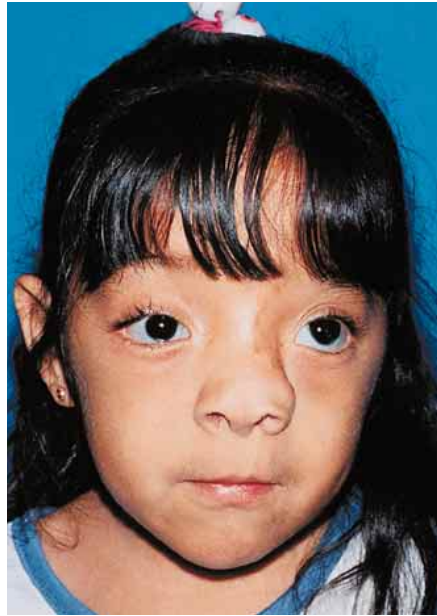

Intracranial correction of orbital hypertelorism. A frontal bone flap is raised and four wall block osteotomies illustrated. The central bony section is removed and the orbit is mobilized medially.

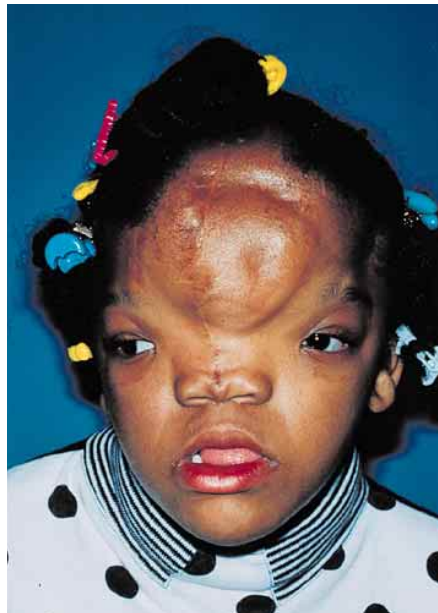Orbital Hypertelorism



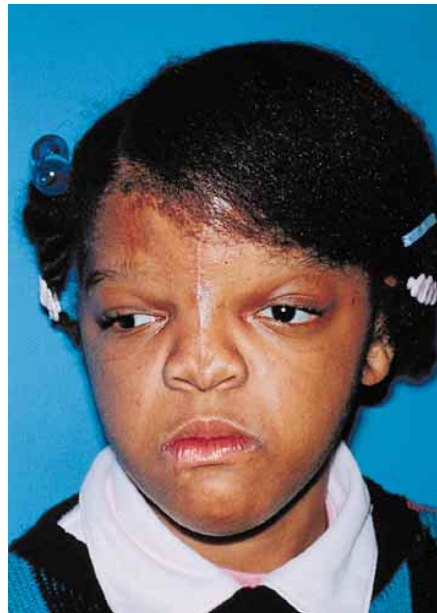Three year old girl with orbital hypertelorism and nasal clefts.



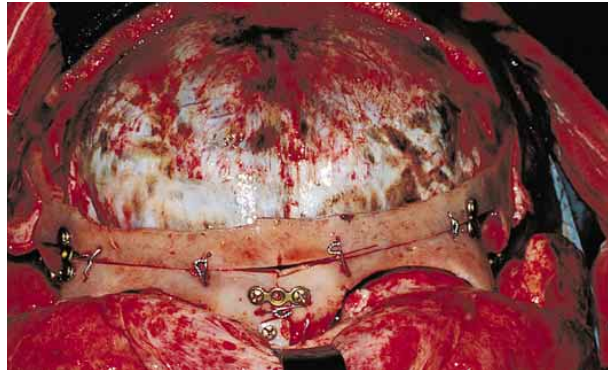
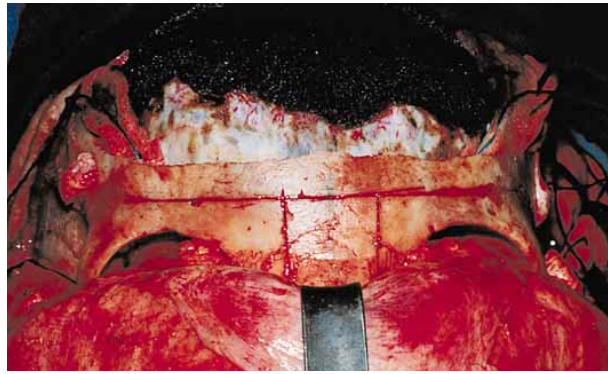
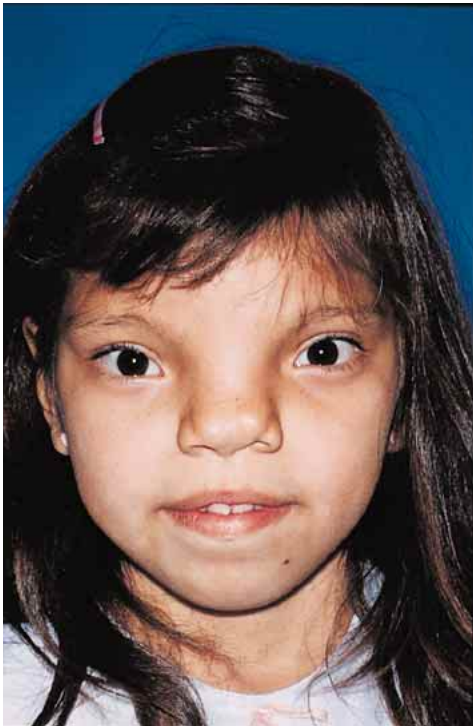Postoperative result



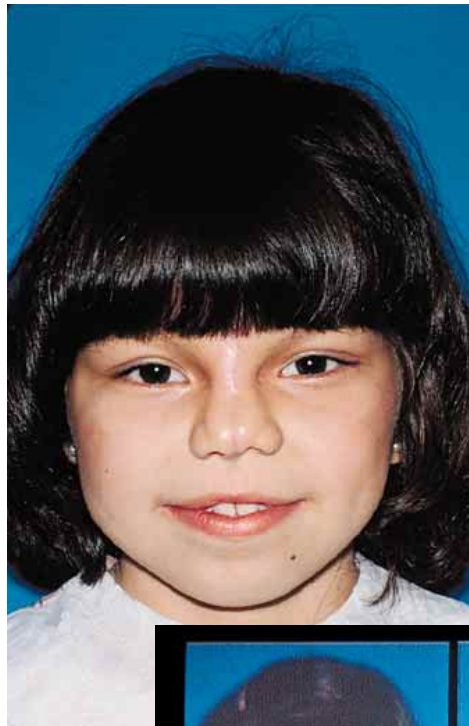Eight year old girl with encephalocele and severe orbital hypertelorism.



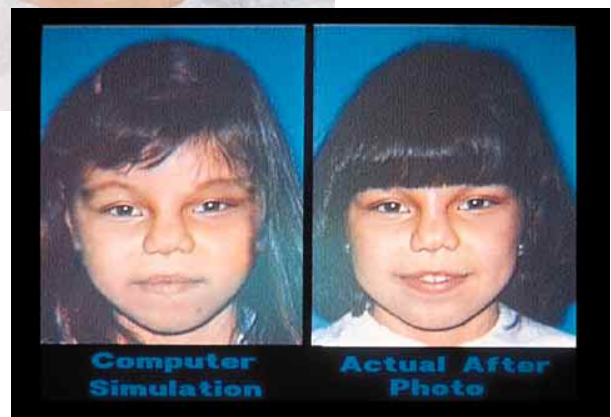Postoperative result after intracranial correction of orbital hypertelorism with forehead reconstruction.



Nine year old girl born with orbital hypertelorism- very wide set eyes with a broad flat nose. Intraoperative photos show cuts to be made in orbital bones. A midline segment of bone is removed and orbits advanced medially. Stabilization is obtained with mini-plates and wires.



Postoperative result after intracranial correction of orbital hypertelorism. Computer simulated result is compared to actual postoperative photograph.



ENOPHTHALMOS

Enophthalmos can be defined as the relative recession (backward or downward displacement) of the globe into the bony orbit. The three basic structures that determine globe position are the bony orbits, the ligament system and the orbital fat. Displacement of the orbital walls with enlargement of the bony orbit may be the major components in the production of enophthalmos in orbital fractures. Post-traumatic enophthalmos is frequently seen and is the result of disruption of the bony orbit and ligament system with displacement of the orbital soft tissue. This presents clinically as a sunken appearance to the eye with pseudoptosis and deepening of the supratarsal fold. Treatment involves reconstruction of the bony orbit with restoration of bony orbital volume and repositioning of the globe. The use of craniofacial techniques allows this to be accomplished with minimal complications.



This patient has severe displacement of the right eye caused by tumor.



Postoperative result after tumor resection and orbital reconstruction with repositioning of the right eye.

Enophthalmos



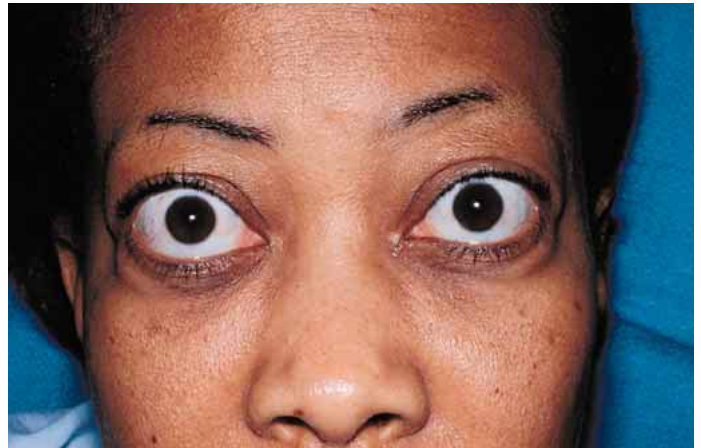This patient has traumatic enophthalmos of the left orbit. Note sunken-in appearance of the left eye due to unrepaired orbital fracture.



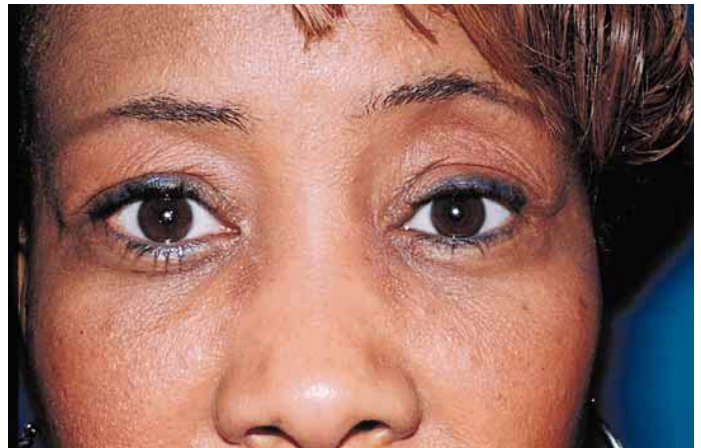Postoperative result after orbital reconstruction and repositioning of eye.

EXOPHTHALMOS

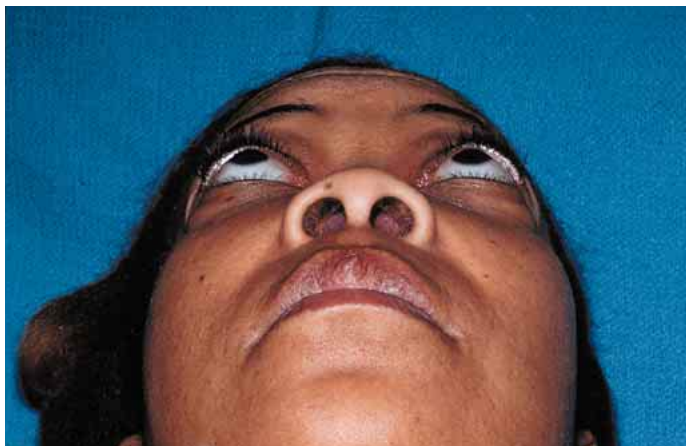
Exophthalmos is an abnormal prominence or protrusion of the eyeball, most frequently seen in patients with Grave's disease (hyperthyroidism). As with enophthalmos, surgical correction is frequently necessary to achieve the desired aesthetic result. The extent of the deformity dictates the surgeon's choice of treatment options. Although severe exophthalmos may present as a surgical emergency in which vision is threatened, moderate exophthalmos can also be distressing to the patient — the wide-eyed stare, lid retraction, and proptosis are at best unsightly and at worst psychologically handicapping. By utilizing craniofacial approaches and techniques, excellent aesthetic results can be safely obtained. Mild to moderate cases are repaired by removing the floor and lateral wall of the orbit to allow for tissue decompression (removing compressive pressure on the eyeball itself), while severe cases necessitate a more aggressive approach including multi-wall (lateral, medial, and inferior) orbital osteotomies. This functionally enlarges the bony orbit, allowing the globe to assume a more normal posterior position.



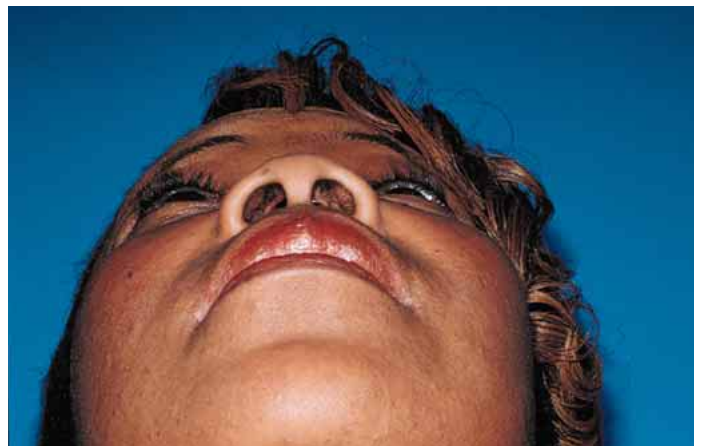This patient has severe exophthalmos caused by hyperthyroidism.



Postoperative result after enlargement of bony orbits.



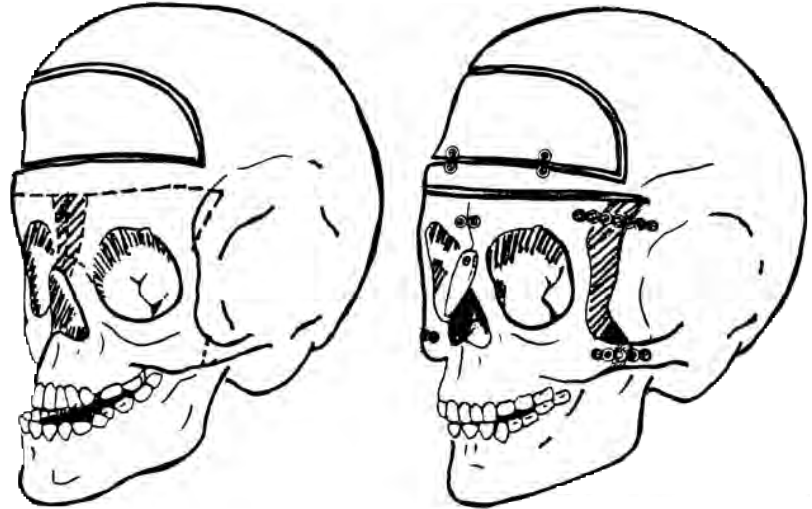
Preoperative



Postoperative

FACIAL BIPARTITION

The surgical technique of facial bipartition involves vertical splitting or separation of the facial skeleton into two segments. The procedure has been used to successfully correct hypertelorism with widening and leveling of the lower maxilla. The facial bipartition concept can also be designed to provide a facial advancement in addition to enlargement of the maxilla and medial rotation of the orbits. This procedure offers new possibilities and can be applied to correct a number of deformities in various syndromes in a one-stage procedure. With appropriate indications and careful technique, this procedure can produce dramatic results.



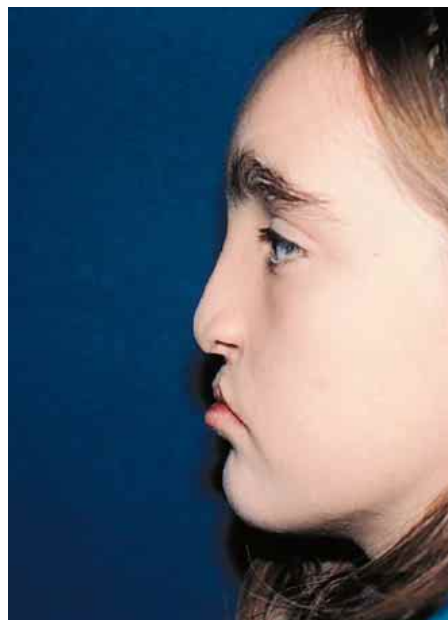Facial Bipartition

The osteotomies and bone resections are illustrated in a frontofacial monobloc advancement with correction of hypertelorism – the facial bipartition procedure. The frontofacial complex is stabilized with miniplates.

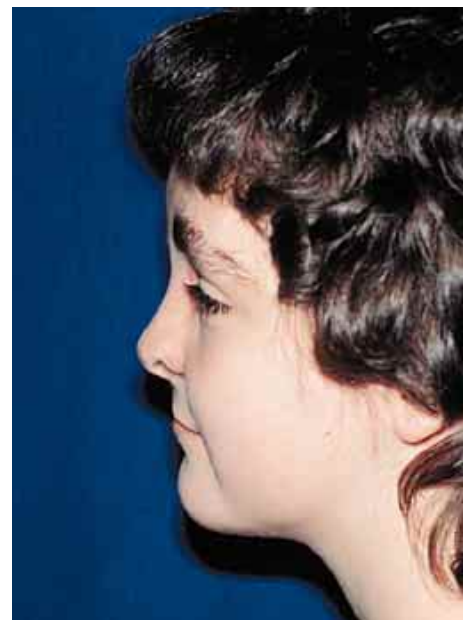Facial Bipartition

Dramatic changes can be made in the profile using the bipartition technique illustrated in drawing.

Facial Bipartition



Preoperative

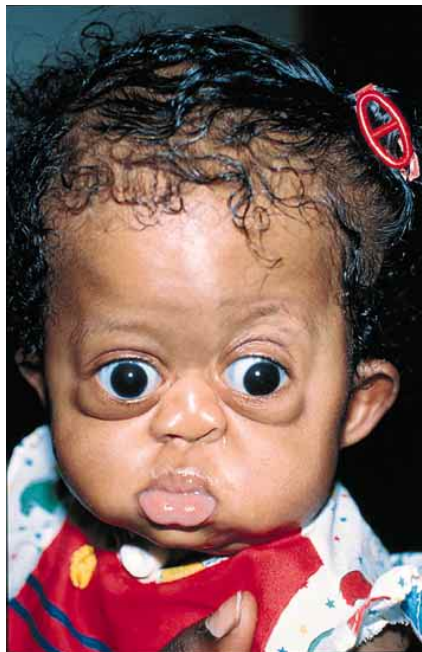

Postoperative

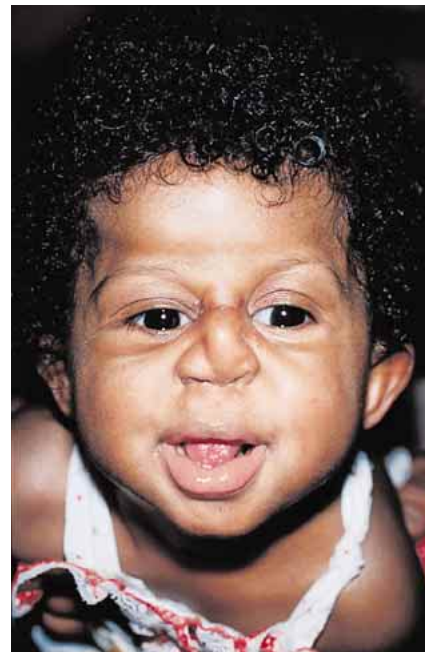MONOBLOC ADVANCEMENT

Infants born with faciocraniosynostosis may have severe airway problems, increased intracranial pressure, vision-threatening proptosis and a failure to thrive. Such life-threatening problems may be treated with a one-stage procedure known as a monobloc advancement. This single phase operation releases the stenosis and advances the forehead and facial bones en bloc to a more anterior position. This has the goal of establishing normal function and appearance as early as possible. We feel this procedure has increased risks of infection due to the likely communication between the nasal and intracranial cavities and therefore use it cautiously for such indications as airway compromise or vision-threatening proptosis.

Monobloc Advancement



Infant born with faciocraniosynostosis causing severe airway problems, proptosis and failure to thrive.



Postoperative result after a one-stage advancement of skull and face with marked improvement in airway, proptosis and overall health status.

ENOPHTHALMOS

Enophthalmos can be defined as the relative recession (backward or downward displacement) of the globe into the bony orbit. The three basic structures that determine globe position are the bony orbits, the ligament system and the orbital fat. Displacement of the orbital walls with enlargement of the bony orbit may be the major components in the production of enophthalmos in orbital fractures. Post-traumatic enophthalmos is frequently seen and is the result of disruption of the bony orbit and ligament system with displacement of the orbital soft tissue. This presents clinically as a sunken appearance to the eye with pseudoptosis and deepening of the supratarsal fold. Treatment involves reconstruction of the bony orbit with restoration of bony orbital volume and repositioning of the globe. The use of craniofacial techniques allows this to be accomplished with minimal complications.



This patient has severe displacement of the right eye caused by tumor.



Postoperative result after tumor resection and orbital reconstruction with repositioning of the right eye.

Enophthalmos



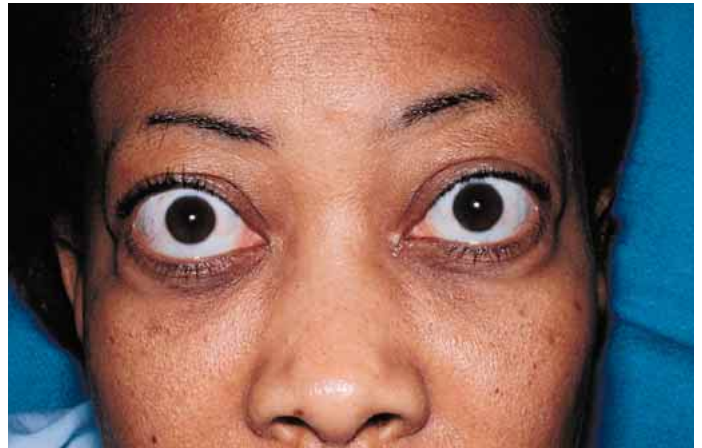This patient has traumatic enophthalmos of the left orbit. Note sunken-in appearance of the left eye due to unrepaired orbital fracture.



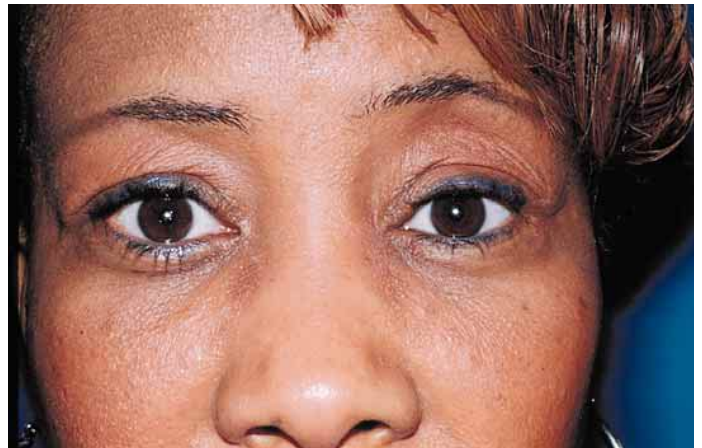Postoperative result after orbital reconstruction and repositioning of eye.

EXOPHTHALMOS

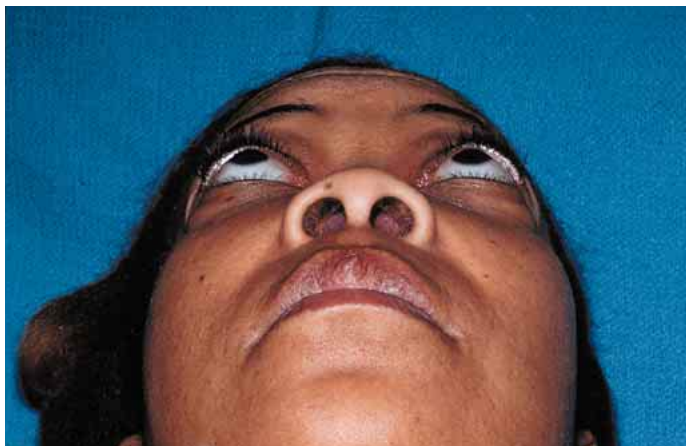
Exophthalmos is an abnormal prominence or protrusion of the eyeball, most frequently seen in patients with Grave's disease (hyperthyroidism). As with enophthalmos, surgical correction is frequently necessary to achieve the desired aesthetic result. The extent of the deformity dictates the surgeon's choice of treatment options. Although severe exophthalmos may present as a surgical emergency in which vision is threatened, moderate exophthalmos can also be distressing to the patient — the wide-eyed stare, lid retraction, and proptosis are at best unsightly and at worst psychologically handicapping. By utilizing craniofacial approaches and techniques, excellent aesthetic results can be safely obtained. Mild to moderate cases are repaired by removing the floor and lateral wall of the orbit to allow for tissue decompression (removing compressive pressure on the eyeball itself), while severe cases necessitate a more aggressive approach including multi-wall (lateral, medial, and inferior) orbital osteotomies. This functionally enlarges the bony orbit, allowing the globe to assume a more normal posterior position.



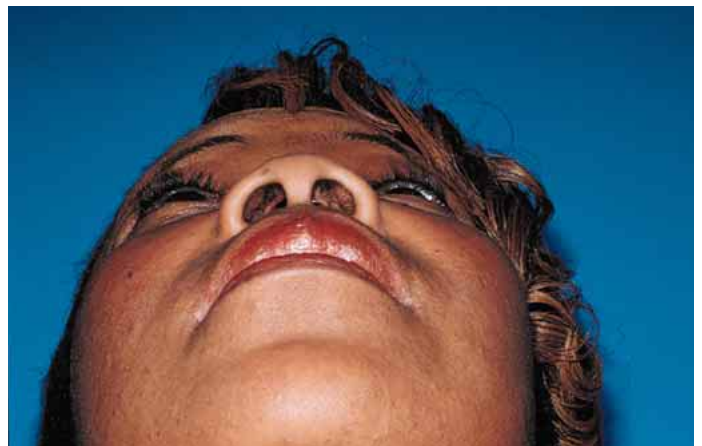This patient has severe exophthalmos caused by hyperthyroidism.



Postoperative result after enlargement of bony orbits.



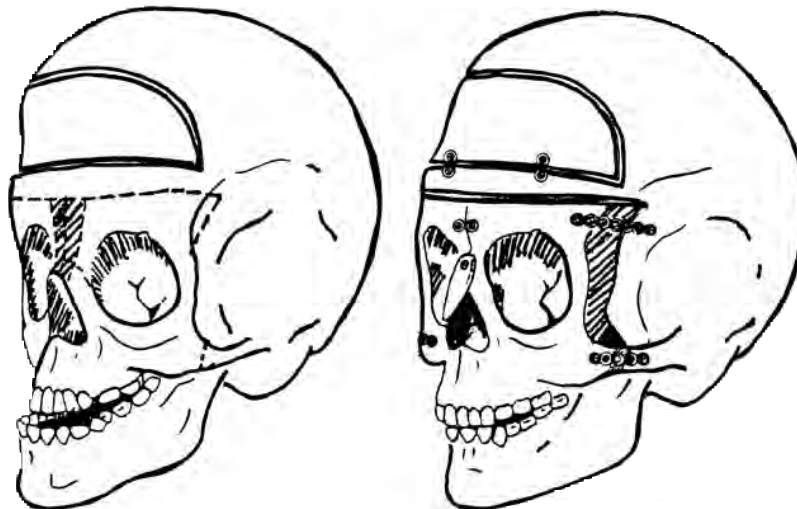
Preoperative



Postoperative

FACIAL BIPARTITION

The surgical technique of facial bipartition involves vertical splitting or separation of the facial skeleton into two segments. The procedure has been used to successfully correct hypertelorism with widening and leveling of the lower maxilla. The facial bipartition concept can also be designed to provide a facial advancement in addition to enlargement of the maxilla and medial rotation of the orbits. This procedure offers new possibilities and can be applied to correct a number of deformities in various syndromes in a one-stage procedure. With appropriate indications and careful technique, this procedure can produce dramatic results.



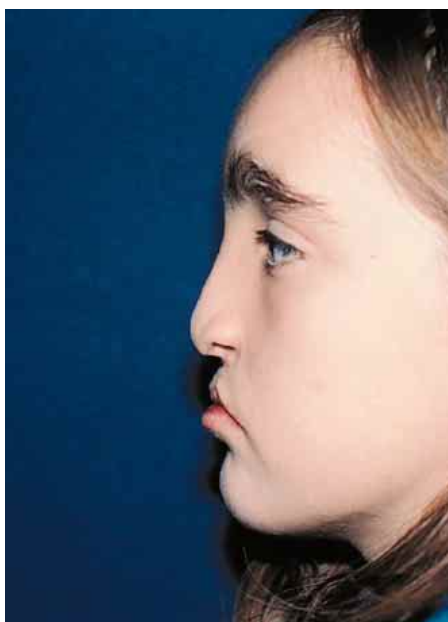Facial Bipartition

The osteotomies and bone resections are illustrated in a frontofacial monobloc advancement with correction of hypertelorism – the facial bipartition procedure. The frontofacial complex is stabilized with miniplates.

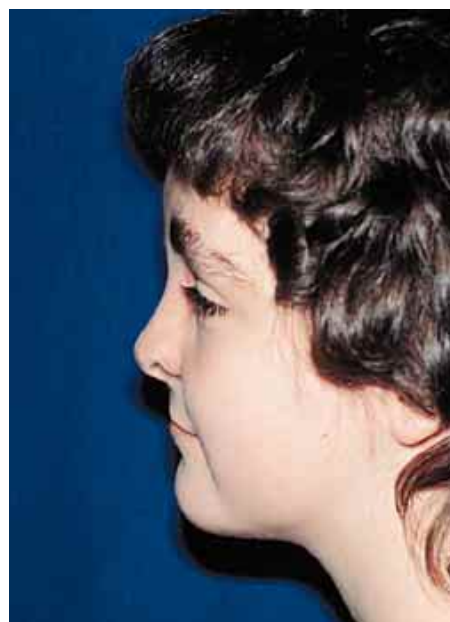Facial Bipartition

Dramatic changes can be made in the profile using the bipartition technique illustrated in drawing.

Facial Bipartition



Preoperative



Postoperative

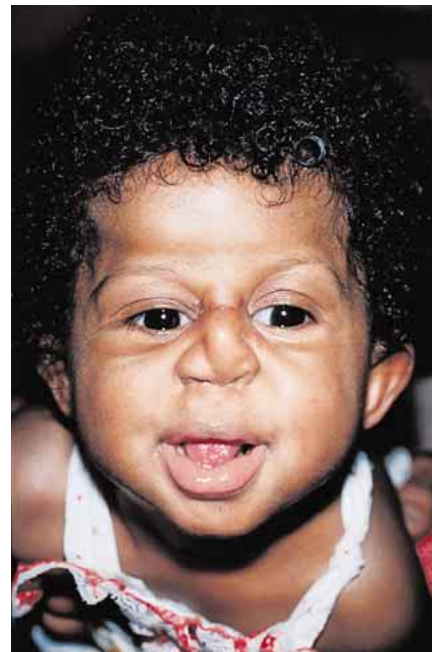MONOBLOC ADVANCEMENT

Infants born with faciocraniosynostosis may have severe airway problems, increased intracranial pressure, vision-threatening proptosis and a failure to thrive. Such life-threatening problems may be treated with a one-stage procedure known as a monobloc advancement. This single phase operation releases the stenosis and advances the forehead and facial bones en bloc to a more anterior position. This has the goal of establishing normal function and appearance as early as possible. We feel this procedure has increased risks of infection due to the likely communication between the nasal and intracranial cavities and therefore use it cautiously for such indications as airway compromise or vision-threatening proptosis.

Monobloc Advancement

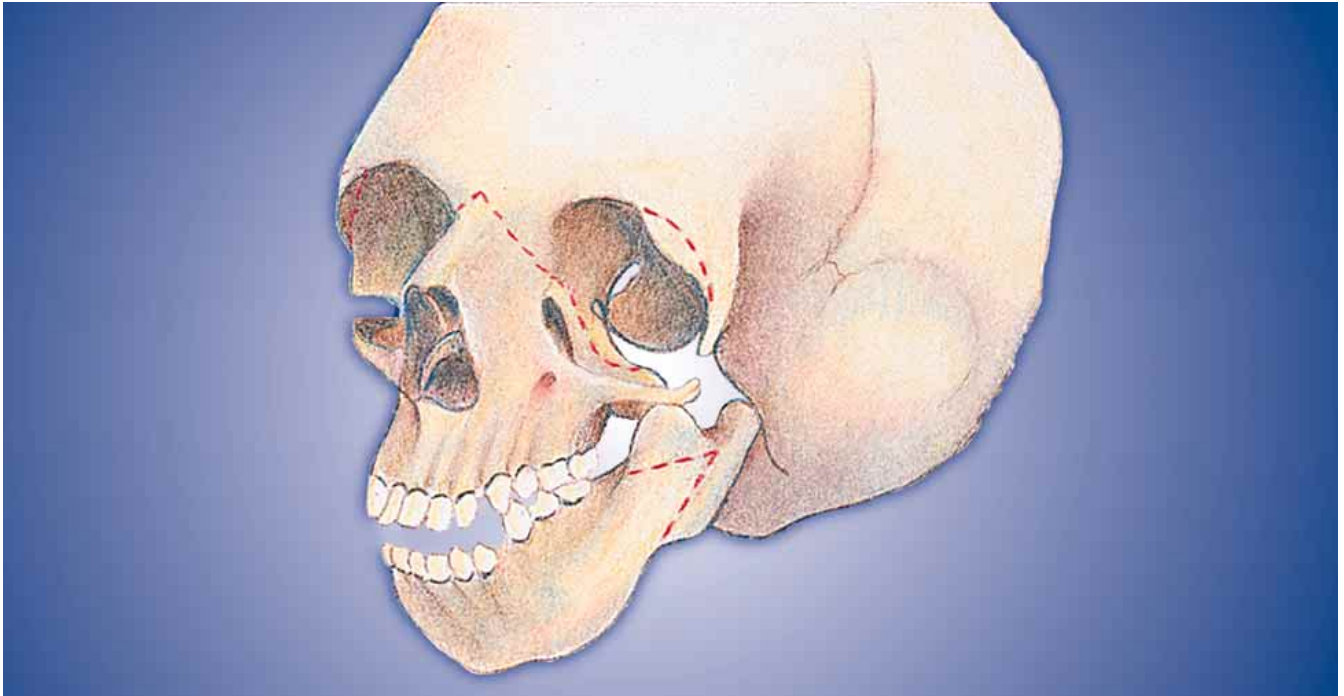


Infant born with faciocraniosynostosis causing severe airway problems, proptosis and failure to thrive.



Postoperative result after a one-stage advancement of skull and face with marked improvement in airway, proptosis and overall health status.

Treacher Collins Syndrome



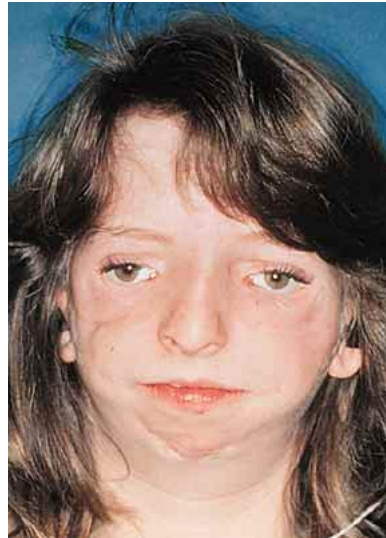TREACHER COLLINS SYNDROME

Treacher Collins syndrome (also called mandibulofacial dysostosis and Franceschetti Syndrome) is a highly complex disease process. The basic etiology is unknown, but it is generally thought to be inherited as an autosomal dominant trait with variable penetrance. It is characterized by hypoplasia of the facial bones, especially the zygoma and the mandible. Facial clefting causes this hypoplastic appearance, with possible deformities or deficiencies of the ear, orbital, midface, and lower jaw regions. The clinical appearance is a result of the zygoma (malar bone) failing to fuse with the maxilla, frontal, and temporal bones. Highly variant degrees of involvement (complete, incomplete, and abortive forms) can be seen, but common facial features may include:

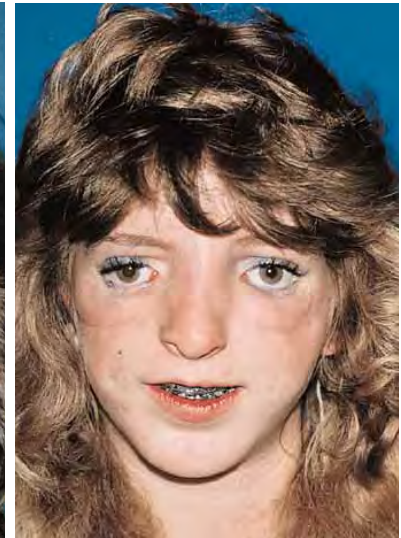- (1) Hypoplastic cheeks, zygomatic arches, and mandible;
- (2) Microtia with possible hearing loss;
- (3) High arched or cleft palate;
- (4) Macrostomia (abnormally large mouth);
- (5) Anti-mongoloid slant to the eyes;
- (6) Colobomas;
- (7) Increased anterior facial height;
- (8) Malocclusion (anterior open bite);
- (9) Small oral cavity and airway with a normal-sized tongue;
- (10) Pointed nasal prominence.

The craniofacial team's geneticist should evaluate all Treacher Collins

Treacher Collins Syndrome

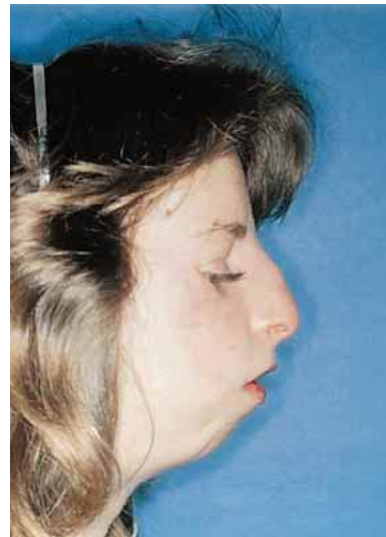

Preoperative

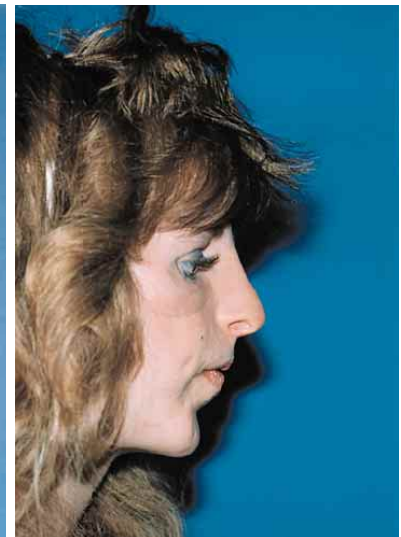

Postoperative

Severe mandibular hypoplasia in the patient with Treacher Collins syndrome.



Preoperative



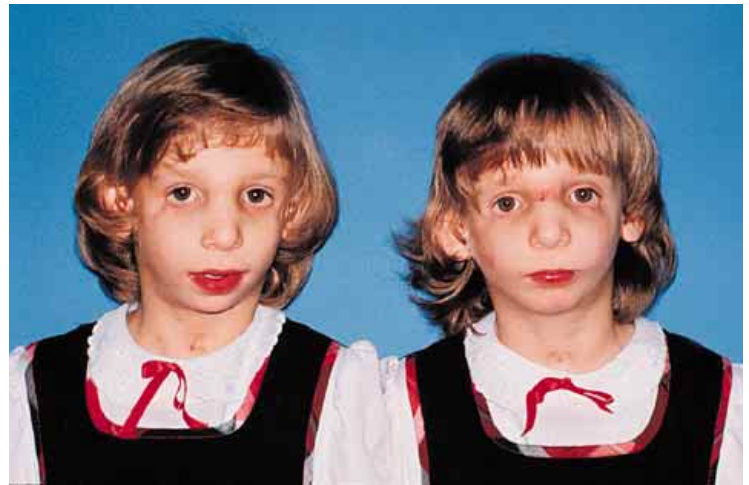Postoperative

Postoperative result after mandibular reconstruction and chin advancement to correct malocclusion and improve profile.

patients and their families to determine if the disease has been caused by inheritance of a family trait or as the result of a spontaneous gene mutation. If the disease has been inherited by one child in a family, there is a 50% chance that the parents will give birth to another involved child. If neither parents nor other family members are affected and a child is born with the condition, then a mutation has occurred. There is a 50% chance that this child will pass the trait on to future generations. Fortunately, genetic advances and careful prenatal screening have made Treacher Collins syndrome extremely rare.

An extensive array of complications can affect treatment. Because of the small jaw and airway, combined with the normal size of the tongue, breathing problems can occur at birth and during sleep for a child with Treacher Collins syndrome when the base of the tongue obstructs the small hypopharynx. This situation can cause serious problems during the induction of general anesthesia. Consequently, a tracheostomy may be required to adequately control the airway. Learning and speech difficulties can also occur depending on the degree of conductive hearing loss common in the syndrome. Learning disabilities can potentially create a significant social stigma for the child. As with other disfiguring conditions, assessing and treating the psychological needs of the Treacher Collins patient is a vital function of the true craniofacial center.

Treatment of the hard and soft tissues of the face can require a number of surgical interventions, the first being the correction of eyelid coloboma in the first years of life (depending on the severity). The next stage is orbital reconstruction with calvarial bone grafts and correction of the lateral canthal displacement.



Identical twins with Treacher Collins syndrome.

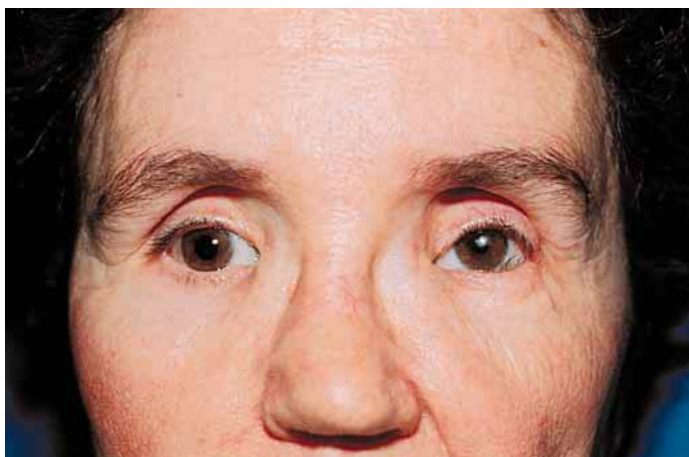
Multi-stage ear reconstruction follows at about 5-7 years of age. Correcting the lower face and jaws involves close coordination between the craniofacial surgeon and the pedodontist/orthodontist, with orthodontic intervention beginning with the eruption of the patient's permanent teeth. After the teeth are aligned to their proper axis (or as closely as is possible), treatment of the lower face then involves orthognathic surgery to reposition the mandible and the maxilla, usually done during the patient's teen years. This can be a one- or two-step procedure. The combined procedure involves rotating the midfacial segment around a transverse axis at the frontonasal angle (for severe maxillary hypoplasia) and lengthening the mandibular ramus. For less severe cases, a LeFort I type osteotomy technique is used to lower the maxillary tuberosities along with the ramus lengthening procedure for the mandible. As the child's face continues to grow, additional procedures may be required to correct any developing deformities. Complimentary procedures such as rib cartilage grafts on the zygoma, closure of macrostomia, and secondary genioplasties are performed according to individual cases. A well-planned treatment regimen can produce excellent results with the ultimate goal being the complete restoration of form and function, thus enabling the patient to adapt to a "normal" way of life.

CANTHAL SURGERY

Many congenital and acquired deformities are associated with medial and lateral canthal displacement. Patients with blepharophimosis (telecanthus, epicanthal folds, ptosis), hypertelorism, Down's Syndrome, craniofacial dysostosis, and acquired deformities may all have canthal deformities. Evaluation of the position and shape of the canthal area is a necessity in the planning of all orbital surgery. The contour and position of the canthi are important components in the aesthetic balance and symmetry of the face.

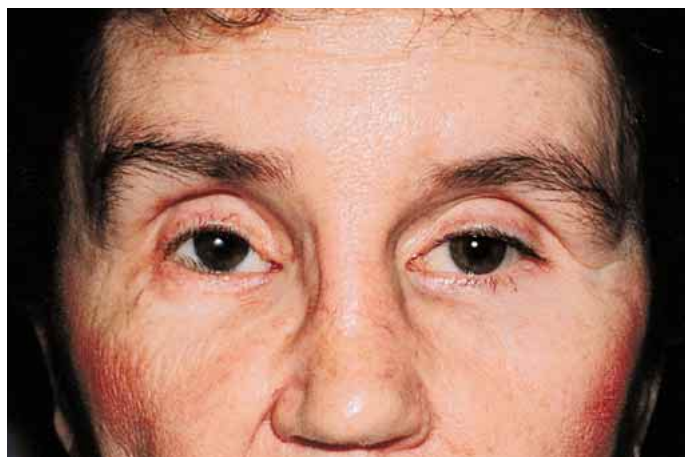Canthal surgery essentially consists of repositioning the involved canthal tendon to the desired position and securing it to the bone. This would seem to be a simple, straight-forward procedure. However, because of the complex anatomy of the medial canthal area and the difficulty in obtaining normal, symmetrical soft tissue contours, this procedure is neither as easy nor as predictable as it would appear to be. Attention to surgical technique, soft tissue tension and contour, bone mobilization and position, and healing of the tendon to bone — all are important in the ultimate results of canthal surgery.

Canthal Surgery



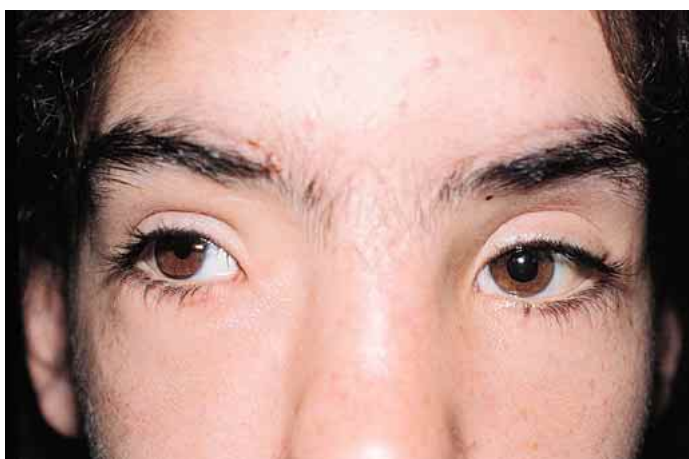Preoperative

Displacement of medial canthi and medial orbital walls due to facial trauma.



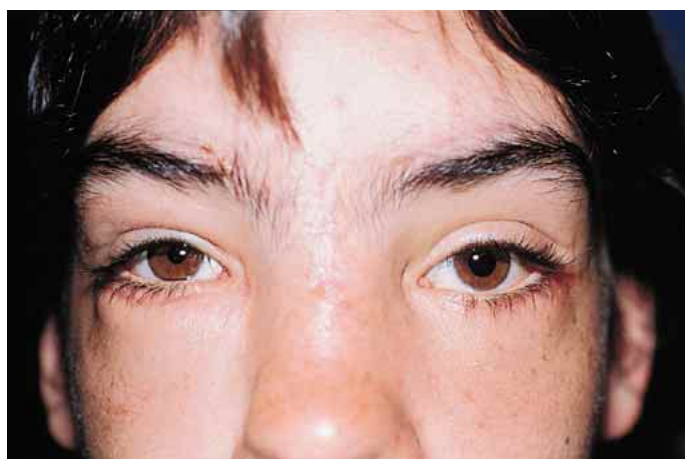Postoperative

Medial orbital wall osteotomies and medial canthopexies performed to correct deformity.



Preoperative

Displacement of both medial canthi is present in this patient due to facial trauma.



Postoperative

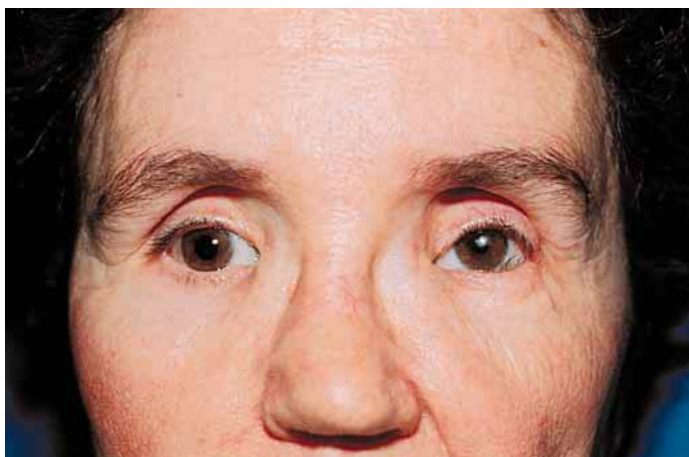
Medial canthopexies are performed to return the medial canthi to their normal position.

CANTHAL SURGERY

Many congenital and acquired deformities are associated with medial and lateral canthal displacement. Patients with blepharophimosis (telecanthus, epicanthal folds, ptosis), hypertelorism, Down's Syndrome, craniofacial dysostosis, and acquired deformities may all have canthal deformities. Evaluation of the position and shape of the canthal area is a necessity in the planning of all orbital surgery. The contour and position of the canthi are important components in the aesthetic balance and symmetry of the face.

Canthal surgery essentially consists of repositioning the involved canthal tendon to the desired position and securing it to the bone. This would seem to be a simple, straight-forward procedure. However, because of the complex anatomy of the medial canthal area and the difficulty in obtaining normal, symmetrical soft tissue contours, this procedure is neither as easy nor as predictable as it would appear to be. Attention to surgical technique, soft tissue tension and contour, bone mobilization and position, and healing of the tendon to bone — all are important in the ultimate results of canthal surgery.

Canthal Surgery



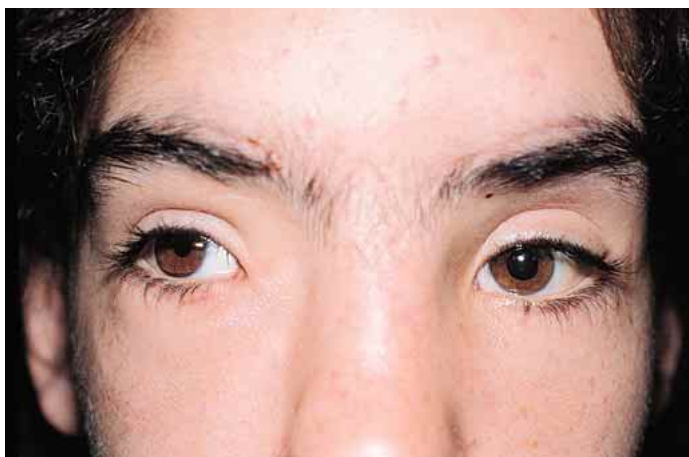Preoperative

Displacement of medial canthi and medial orbital walls due to facial trauma.



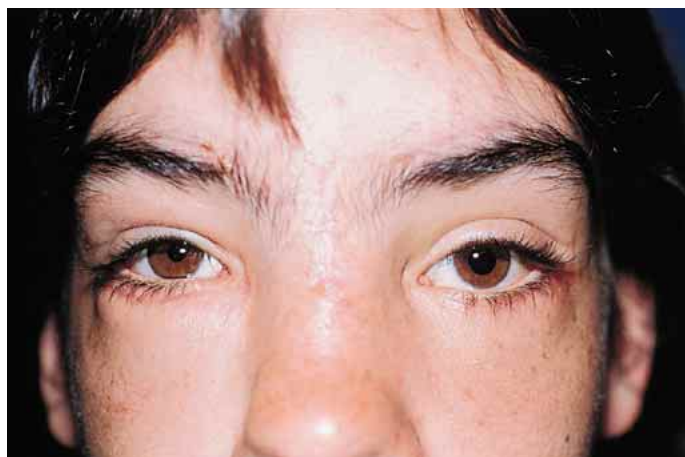Postoperative

Medial orbital wall osteotomies and medial canthopexies performed to correct deformity.



Preoperative

Displacement of both medial canthi is present in this patient due to facial trauma.



Postoperative

Medial canthopexies are performed to return the medial canthi to their normal position.

Nasal Reconstruction



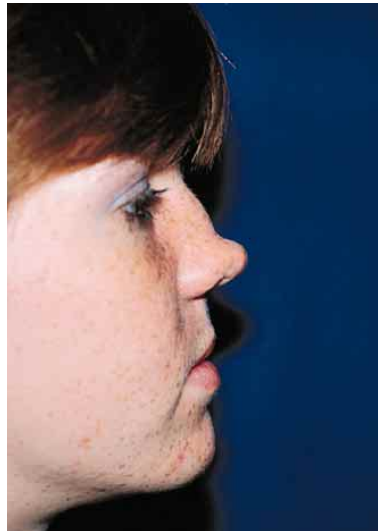NASAL RECONSTRUCTION

A properly proportioned, well placed nose can have a dramatic impact on one's facial appearance. Nasal surgery involves a wide spectrum of procedures ranging from cosmetic rhinoplasty to total nasal reconstruction. Basic rhinoplasty surgery involves the correction or reshaping of existing nasal structures, whereas more extensive cases will require that the craniofacial surgeon actually construct a part of the nose that may be missing or badly misshapened due to disease or trauma. Meticulous attention to detail when repairing or reconstructing the nasal lining, skeletal support, or skin covering is essential to obtain a structure that is fully functional as well as pleasing to the eye.

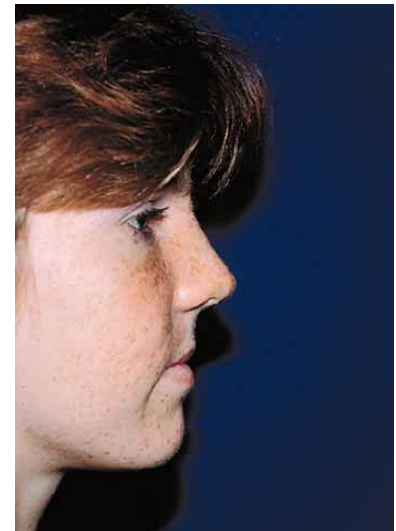When large defects of the nose are present from tumor resection or trauma, flap tissue provides the best aesthetic coverage. The most common flap used for major nasal reconstruction is the forehead flap. This reliable flap can supply a large area of skin with good color match making it suitable for partial or total nasal reconstruction.

Reconstruction of the nasal skeletal framework is frequently necessary in patients with congenital or traumatic deformities. This support is best obtained using bone or cartilage. Outer table calvarial bone grafts harvested from the parietal

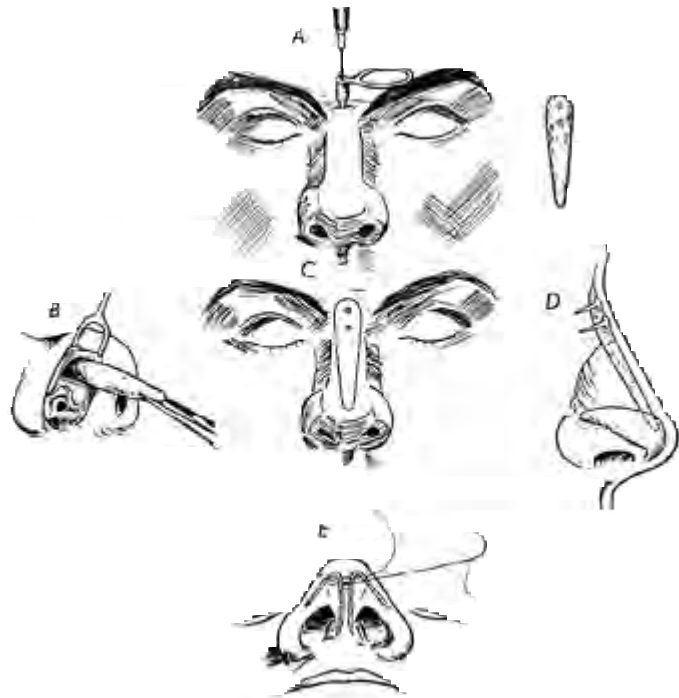
Nasal Reconstruction



Sixteen year old girl with deformity of the nose.



Result after reconstruction of nose with bone graft.

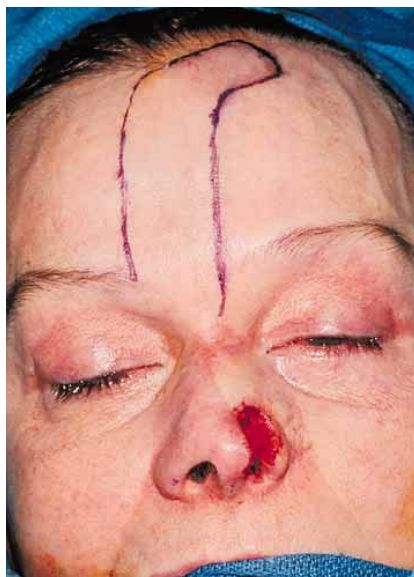

Technique of using a cantilever bone graft for reconstruction of the nose. Calvarial bone is most commonly used and is rigidly fixed with countersunk lag screws.

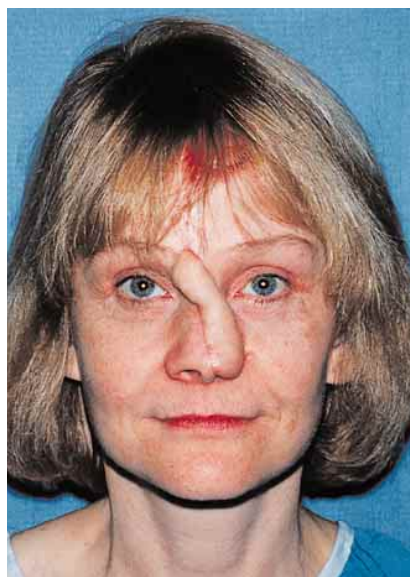area of the skull make excellent cantilever bone struts for support of the nasal dorsum. These grafts can be rigidly fixed with lag screws to provide good stability and dorsal contour. Additional techniques are available to provide nasal support such as the

L-shaped grafts and columella struts. The tip of the nose is best supported with cartilage grafts. Careful attention to detail and planning is necessary in these procedures to create a structure that is both functional and aesthetically pleasing.

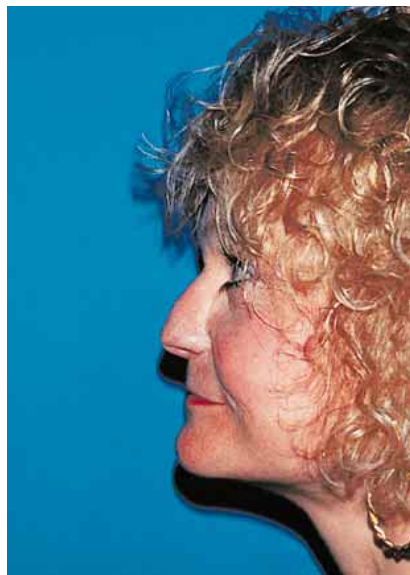Nasal Reconstruction



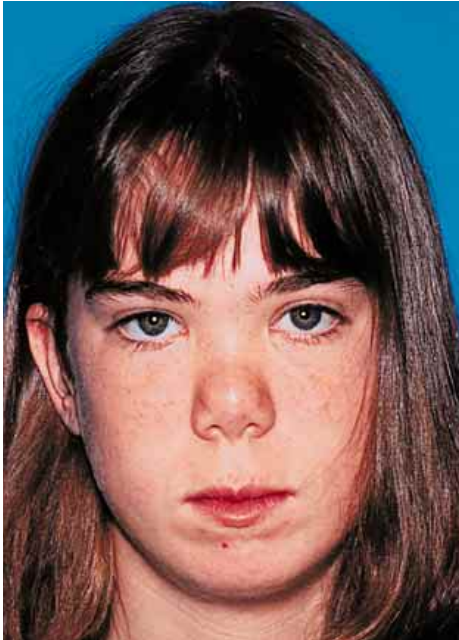Resection of basal cell carcinoma with full thickness defect on left side of nose. Forehead flap outlined.



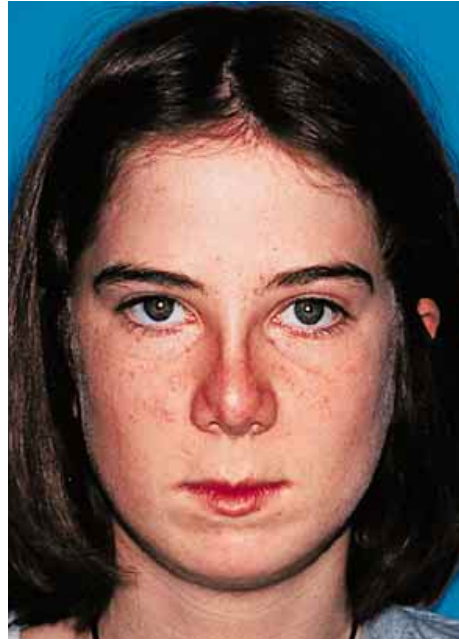Forehead flap rotated to close defect on left side of nose. Tip of flap lined with skin graft.



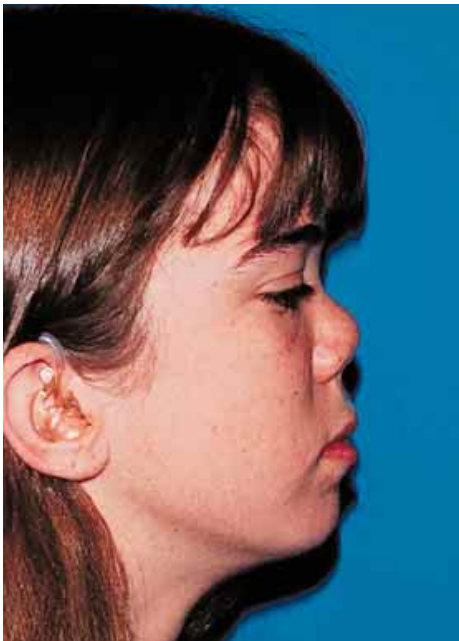Postoperative result after division and inset of forehead flap.



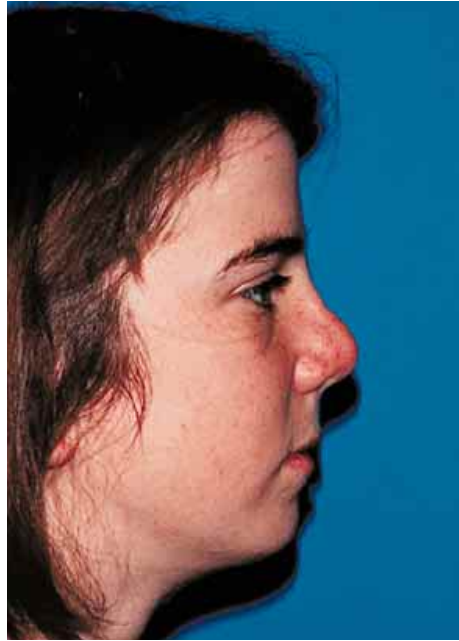Fifteen year old girl with severe nasomaxillary hypoplasia.



Postoperative result after nasomaxillary osteotomy with nasal lengthening and calvarial bone grafts.

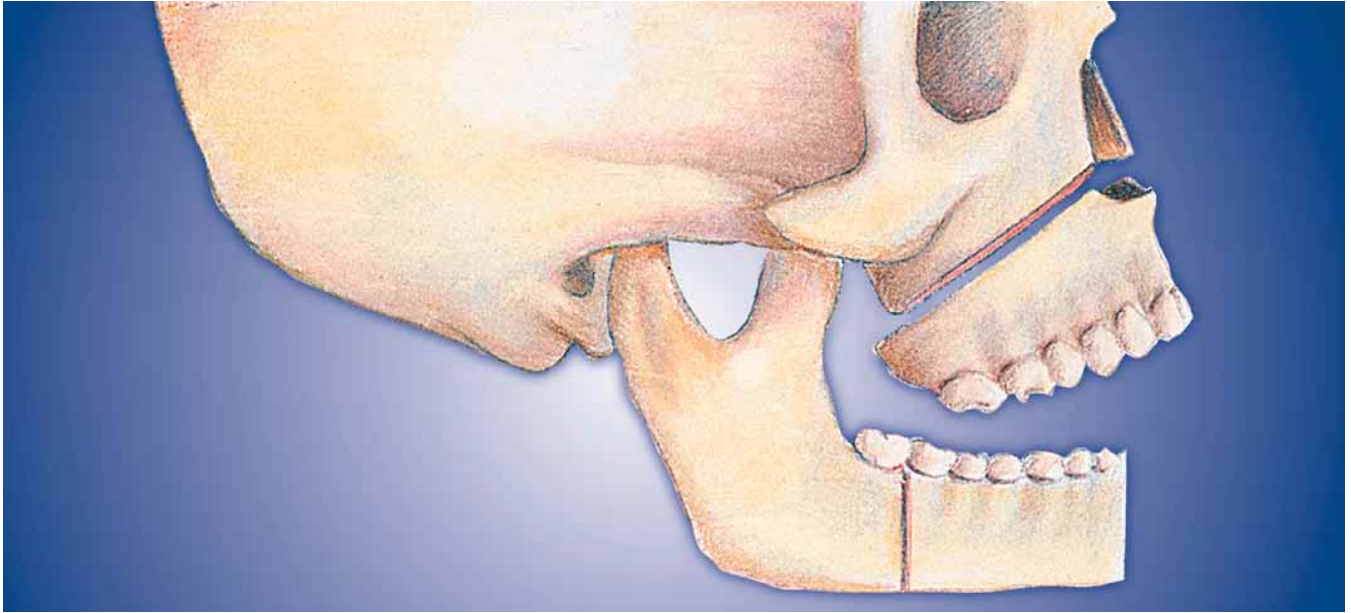


Preoperative



Postoperative

Orthognathic Surgery



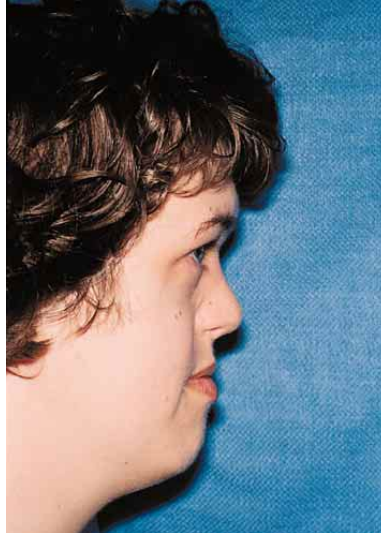ORTHOGNATHIC SURGERY

Oρθognathic surgery refers to the surgical repositioning of the maxilla, mandible, and the dentoalveolar segments to achieve facial and occlusal balance. One or more segments of the jaw(s) can be simultaneously repositioned to treat various types of malocclusions and jaw deformities.

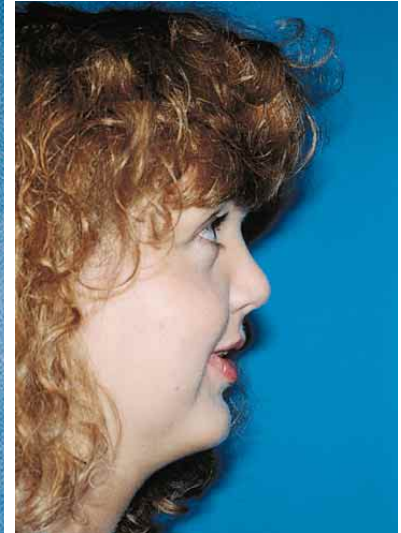Preoperative diagnosis and planning for patients with jaw asymmetries and deformities includes a photographic analysis and a complete orthognathic work-up involving cephalometric and panorex radiographs, dental impressions, and models. This is done by the Pedodontist/Orthodontist in coordination with the craniofacial surgeon. All findings are analyzed and pre-surgical model surgery performed to ascertain the feasibility of various treatment options. Additionally, computer analysis is done pre-surgically by the craniofacial surgeon to simulate surgical results, thereby facilitating proper planning of the case. Computer analysis provides the craniofacial team with visual information and numerical data that is a compilation of many time-consuming calculations such as those used in various cephalometric analyses (Steiner, Ricketts, or Jarabak-Bjork).

Usually, pre-surgical orthodontics are necessary to straighten the teeth and align the arches so that a stable occlusion can be obtained post-operatively, while orthodontics following surgery are frequently required to

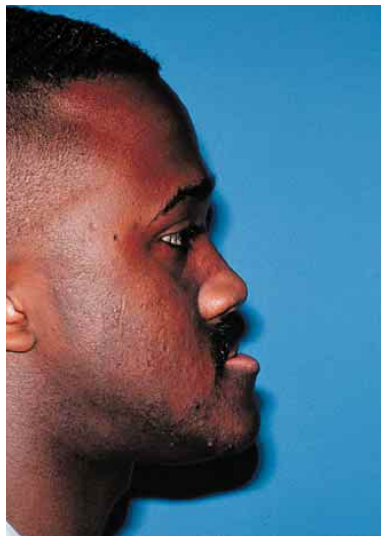
Orthognathic Surgery



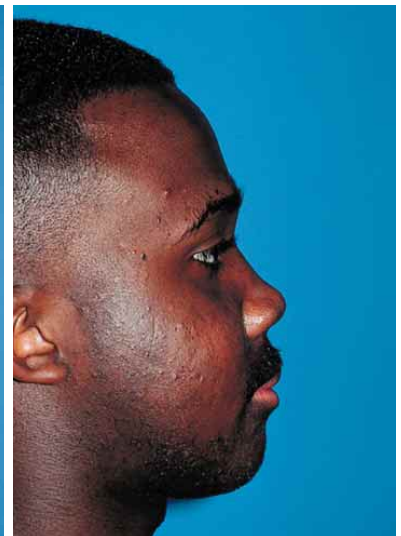
Nineteen year old female with maxillary hypoplasia, malocclusion and facial disharmony.



Postoperative result after combined maxillary/mandibular procedures to correct occlusion and improve facial balance.



Twenty year old male with prognathic mandible.



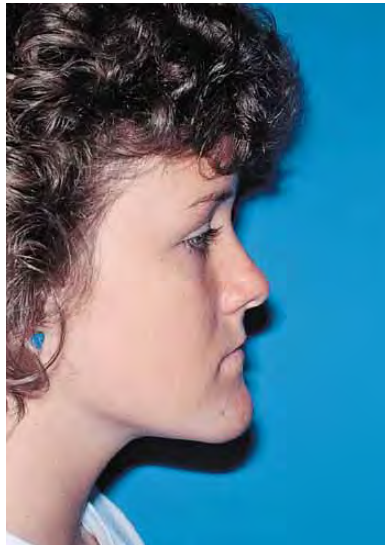Postoperative result after mandibular set back.

revise minor occlusal discrepancies. Orthognathic surgery is often delayed until after all of the permanent teeth have erupted unless medical conditions necessitate that the surgery be performed earlier. In adult

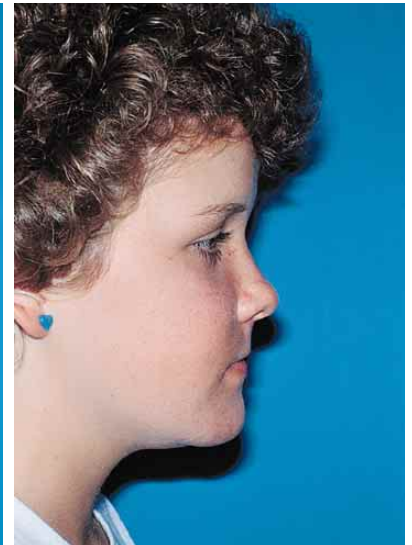
patients, orthognathic surgery can be combined with soft tissue contouring to improve the aesthetic results.

Maxillary advancement is a type of orthognathic surgery that may be necessary to improve the facial contour and normalize dental occlusion when there is a relative deficiency of the midface region. This is done by surgically moving the maxilla with sophisticated bone mobilization techniques and fixing it securely into place. For most patients, the use of screws and miniplates have replaced wiring of the bone and teeth required to hold the jaw stable. Inlay bone grafts can be utilized for space maintenance and secured with screw and plate fixation, while onlay bone grafting is used to augment the bony skeleton and improve facial soft tissue contour.

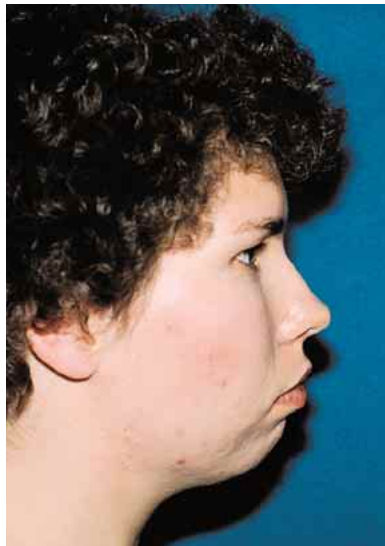Depending on the soft tissue profile of the face or the severity of an occlusal discrepancy, problems with the lower face may require surgery on the mandible. This can be done in conjunction with or separate from maxillary surgery. The mandible can be advanced, set back, tilted or augmented with bone grafts. A combination of these procedures may be necessary. Pre-operative planning is crucial to the success of the procedure and evaluates the surgical and orthodontic options. The surgeon chooses the type of mandibular surgery based on his experience, evaluation of the photographic and cephalometric analysis, and model surgery. Following any significant surgical movement of the mandible, fixation may be accomplished with miniplates and screws or with a combination of interosseous wires and intermaxillary fixation (IMF). Rigid fixation (screws and plates) has the advantage of needing



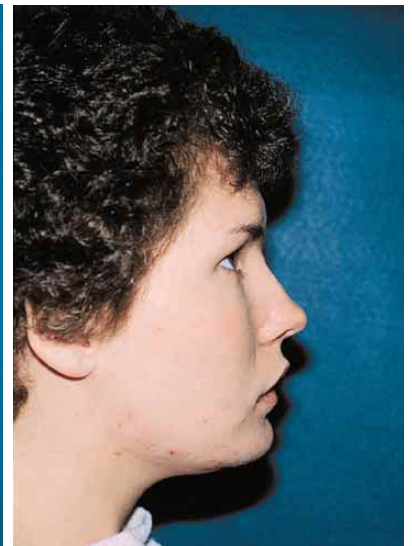A young woman with a prognathic mandible and hypoplastic maxilla.



Postoperative result after maxillary advancement and mandibular set back.



Twenty year old woman with microgenia.

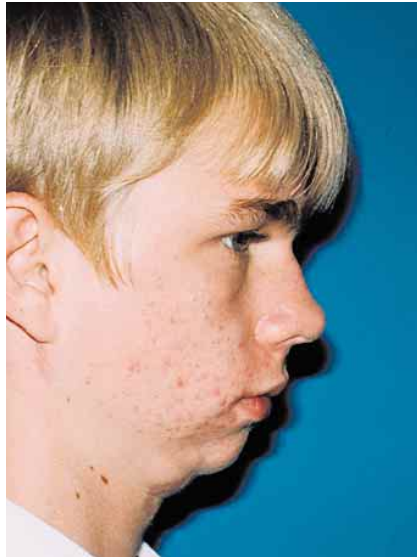

Postoperative result after orthognathic surgery and chin advancement showing improvement in lower facial profile.

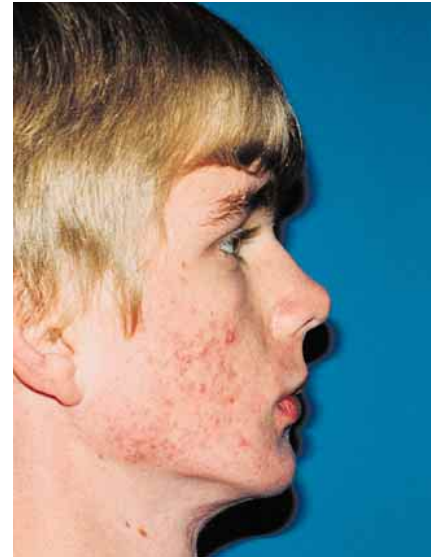
limited or no IMF. However, if interosseous wiring is used, IMF is maintained for approximately six weeks. Nutritionally balanced, blenderized diets are important for proper healing in the patient in IMF.

The chin is an important component of the facial profile as well as the aesthetic balance. The position and projection of the chin should be evaluated in patients

considering orthognathic and facial soft tissue contouring procedures. Photographic and cephalometric analysis help determine the amount of change necessary to obtain a well balanced face. The chin can be augmented with such alloplastic materials as silicone, polyethylene or hydroxyapatite. However, most craniofacial surgeons prefer a sliding horizontal osteotomy genioplasty. This procedure tends to give a more natural contour to the chin and avoids the risk of extrusion that goes along with alloplastic implants.

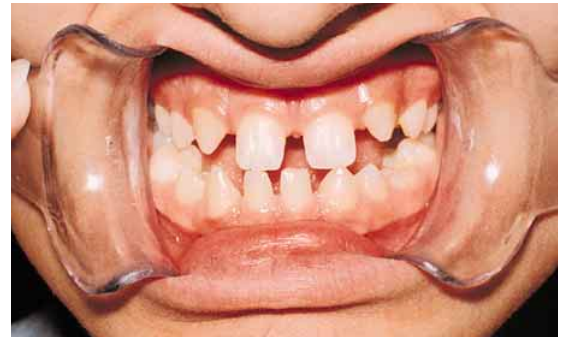
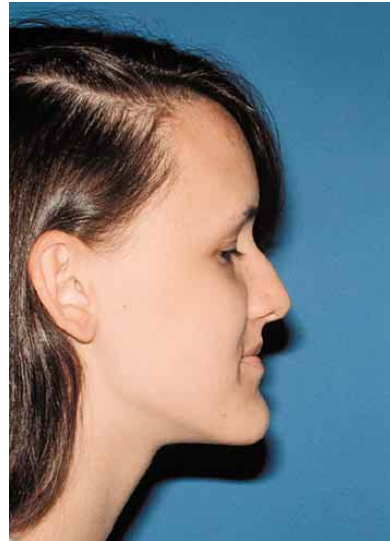
Seventeen year old patient with micrognathia (hypoplastic lower jaw).

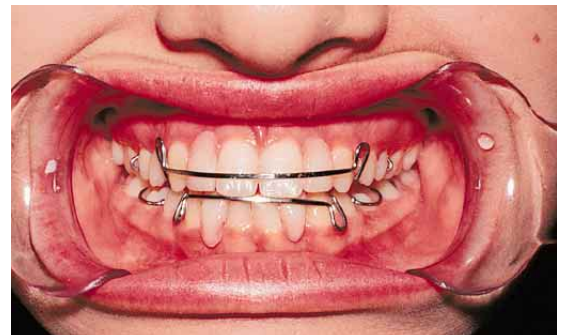
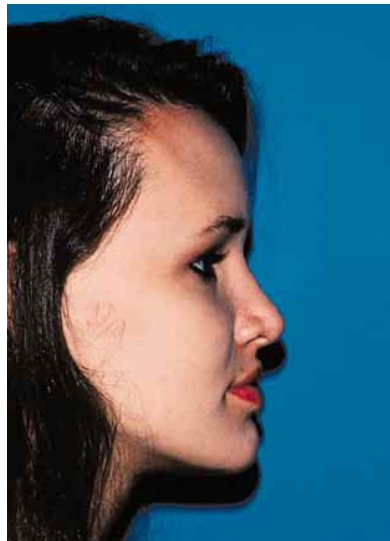
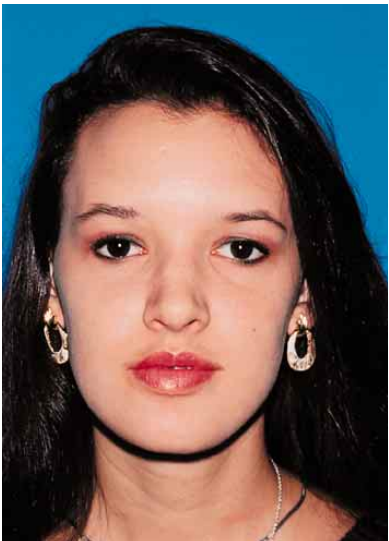
Postoperative result after mandibular advancement.

Orthognathic Surgery

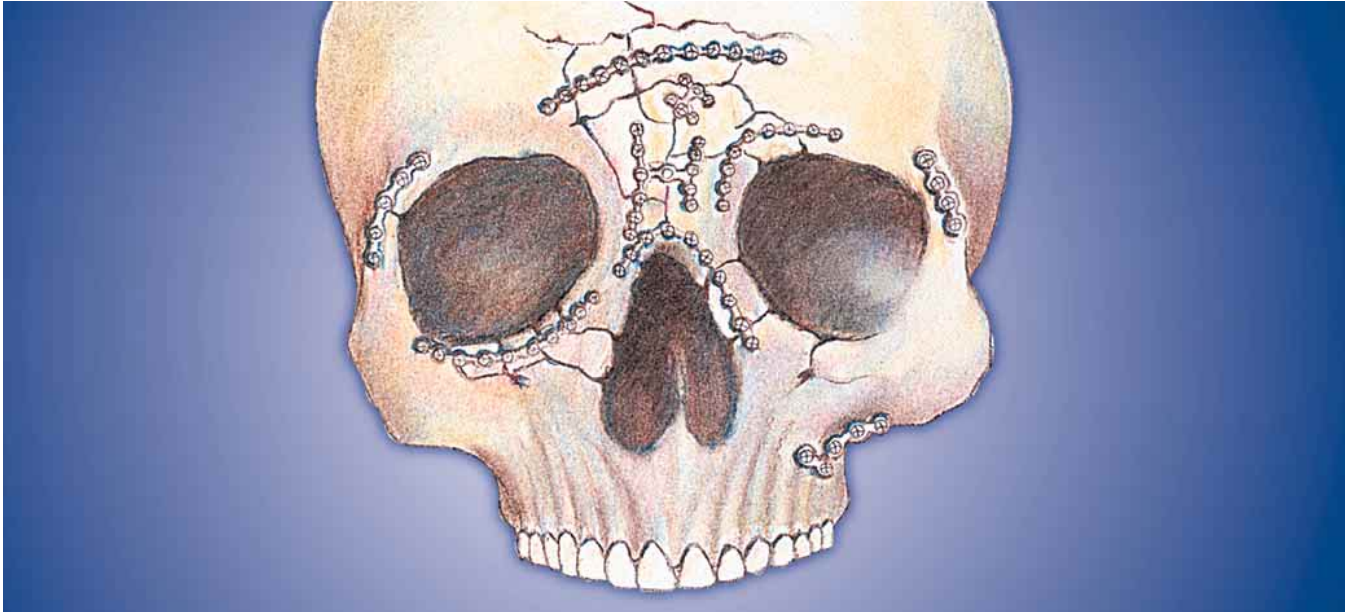


Nineteen year old girl with ectodermal dysplasia. She has a hypoplastic maxilla and an enlarged mandible.



Postoperative result after maxillary advancement, chin reduction and orthodontic treatment.

Trauma Reconstruction



TRAUMA RECONSTRUCTION

CRANIOMAXILLOFACIAL TRAUMA


Millions of people sustain trauma to the head and face resulting in complex fractures which, if not correctly diagnosed and treated, may cause permanent functional and cosmetic deformities. During the past decade, advances in radiographic procedures, the utilization of craniofacial surgical techniques, and the advent of rigid miniplate fixation have tremendously improved the functional and aesthetic results in facial fracture management.

The accurate diagnosis of facial fractures has been greatly improved by the addition of two- and three-dimensional CT scans which have replaced the plain radiographs for the diagnosis of many types of fractures. The three-dimensional reconstructions have enhanced pre-operative bone analysis and planning by providing a life-like simulation of the fractures.

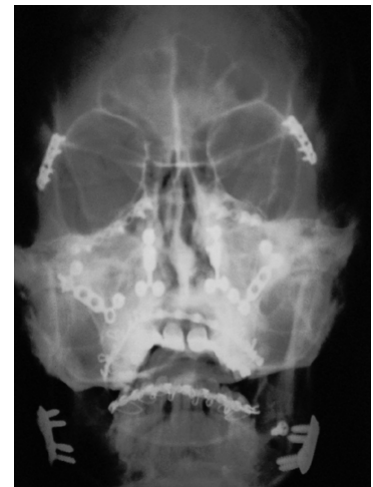In acute trauma cases, the goal of reconstruction is a one-stage repair which has been made possible by the application of craniofacial techniques. Delayed treatment has been replaced by early or immediate surgical treatment and stabilization of small bone fragments augmented by bone grafts and miniplate fixation. These recent advances have allowed surgeons to approach and often reach the goal of restoring preinjury facial appearance and function while at the same time minimizing revisional surgery.



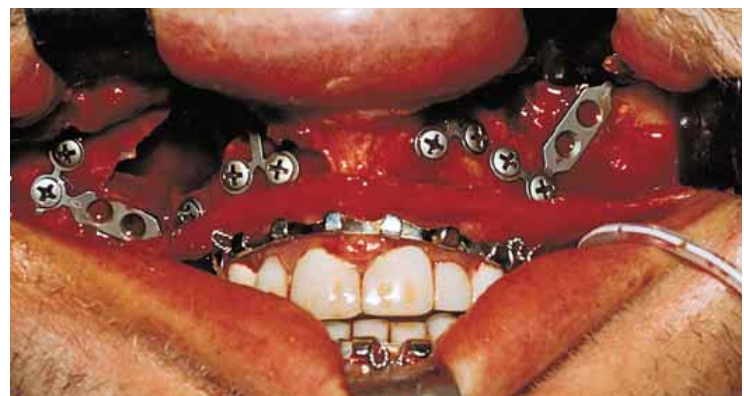A three-dimensional scan above shows extensive fractures of the face.



New miniplate and screw system.



Postoperative radiograph at right shows stabilization of facial buttresses with 10 miniplates.



The maxilla is stabilized with four miniplates.

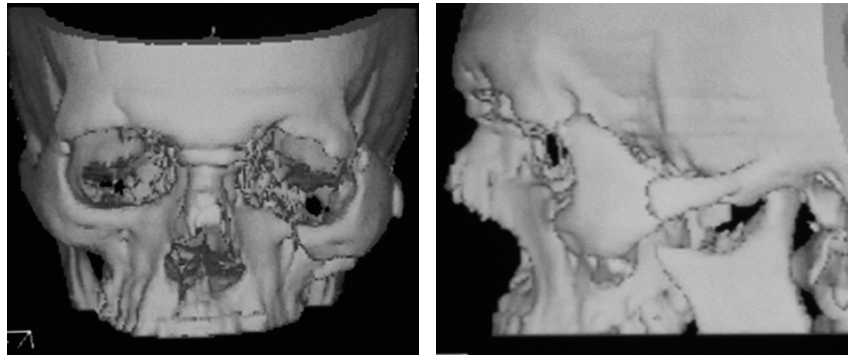
Without treatment in a timely manner, many individuals will develop future problems, the severity and consequences of which can be much greater than if the injury had been immediately repaired. However, modern craniofacial surgical techniques can now offer hope for patients with pre-existing post-traumatic facial deformities despite considerable delays between injury, diagnosis, and treatment. These innovative techniques establish a higher standard of care for the management of facial injuries.

The following sections describe the different areas and types of facial fractures:

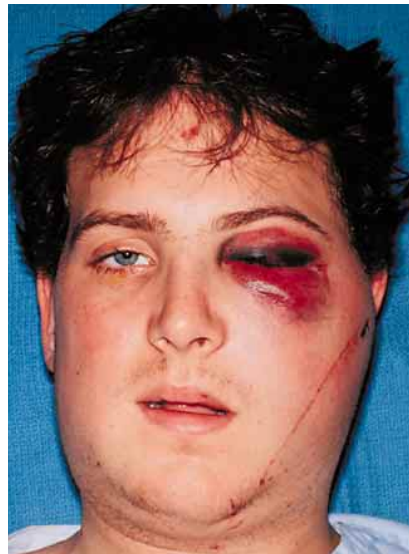ZYGOMATIC FRACTURES

The zygomatic bone occupies a prominent and important position in the facial skeleton. It plays a key role in determining facial width as well as acting as a major buttress of the midface. Its anterior projection forms the malar eminence and is often referred to as the malar bone. The zygoma has several important articulations in the midface. The zygoma forms a significant portion of the floor and lateral wall of the orbit. In addition, the zygoma meets the lateral skull to form the zygomatic arch.

The zygoma is the main buttress between the maxilla and the skull; but in spite of its sturdiness, its prominent location makes it prone to fracture. The mechanism of injury usually involves a blow to the side of the face from a fist,



Front and lateral three dimensional CT Scans demonstrate displaced fractures of all zygomatic buttresses.



Patient with a left displaced zygomatic fracture.



An open reduction with rigid miniplate fixation was performed with postoperative result shown.

object, or secondary to motor vehicle accidents. Moderate force may result in minimally or nondisplaced fractures at the suture lines. More severe blows frequently result in inferior, medial, and posterior displacement of the zygoma. Comminuted fractures of the body with separation at the suture lines are most often the result of high-velocity motor vehicle accidents. In general, displaced fractures will involve the inferior orbital rim and orbital floor, the zygomaticofrontal suture, the zygomaticomaxillary buttress, and the zygomatic arch. Occasionally, however, a direct blow to the arch will result in an isolated depressed fracture of the arch only.

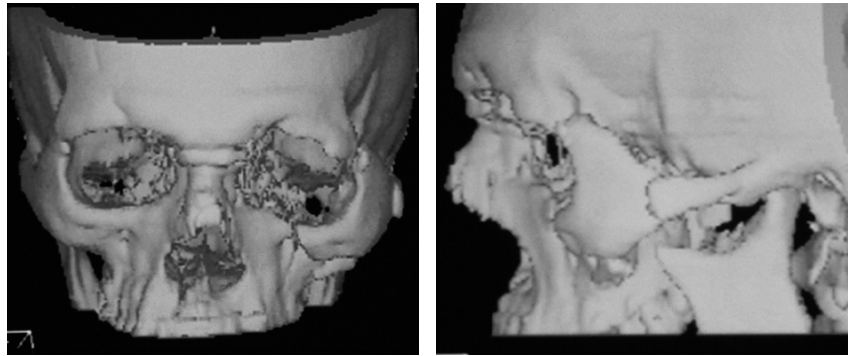
Without treatment in a timely manner, many individuals will develop future problems, the severity and consequences of which can be much greater than if the injury had been immediately repaired. However, modern craniofacial surgical techniques can now offer hope for patients with pre-existing post-traumatic facial deformities despite considerable delays between injury, diagnosis, and treatment. These innovative techniques establish a higher standard of care for the management of facial injuries.

The following sections describe the different areas and types of facial fractures:

ZYGOMATIC FRACTURES

The zygomatic bone occupies a prominent and important position in the facial skeleton. It plays a key role in determining facial width as well as acting as a major buttress of the midface. Its anterior projection forms the malar eminence and is often referred to as the malar bone. The zygoma has several important articulations in the midface. The zygoma forms a significant portion of the floor and lateral wall of the orbit. In addition, the zygoma meets the lateral skull to form the zygomatic arch.

The zygoma is the main buttress between the maxilla and the skull; but in spite of its sturdiness, its prominent location makes it prone to fracture. The mechanism of injury usually involves a blow to the side of the face from a fist,



Front and lateral three dimensional CT Scans demonstrate displaced fractures of all zygomatic buttresses.



Patient with a left displaced zygomatic fracture.



An open reduction with rigid miniplate fixation was performed with postoperative result shown.

object, or secondary to motor vehicle accidents. Moderate force may result in minimally or nondisplaced fractures at the suture lines. More severe blows frequently result in inferior, medial, and posterior displacement of the zygoma. Comminuted fractures of the body with separation at the suture lines are most often the result of high-velocity motor vehicle accidents. In general, displaced fractures will involve the inferior orbital rim and orbital floor, the zygomaticofrontal suture, the zygomaticomaxillary buttress, and the zygomatic arch. Occasionally, however, a direct blow to the arch will result in an isolated depressed fracture of the arch only.

Radiographic evaluation of the fracture is mandatory and may include both plain films and a computed tomographic (CT) scan. The CT scan has now essentially replaced plain films as the “gold standard” in both evaluation and treatment planning. If physical findings and plain films are not suggestive of a zygomatic fracture, the evaluation may end here. However, if they do suggest fracture, a coronal and axial CT scan should be obtained. The CT scan will accurately reveal the extent of orbital involvement, as well as degree of displacement of the fractures. This study is vital for planning the operative approach.

Historically, closed reduction was the method of choice for nearly all zygomatic fractures. Multiple methods were employed, but most involved simply exerting pressure underneath the malar eminence and popping the fragments back into alignment. Not only were these results frequently unsatisfactory, but they were fraught with complications including persistent diplopia, orbital dystopia, malunion, and significant residual deformity. In our own experience, closed reductions yield unpredictable results with significant chance of relapse. We feel that plate and screw fixation is now the standard of care.

The treatment of zygomatic fractures has dramatically progressed over the past several decades from an entirely closed approach to the more aggressive open reduction and rigid miniplate fixation of today. If a zygomatic fracture is displaced, we do an open reduction and rigid stabilization with mini- and microplates. The floor of the orbit is routinely explored and reconstructed, if needed, to restore orbital volume. The complications of an inadequately or unreduced zygomatic fracture are very difficult to correct secondarily and usually avoidable. We feel that early diagnosis combined with this aggressive surgical treatment yields the best results.

MAXILLARY FRACTURES

The maxilla forms the largest component of the middle third of the facial skeleton. The maxilla is a key bone in the midface that is closely associated with adjacent bones providing structural support between the cranial base and the occlusal plane. Fractures of the maxilla occur less frequently than those of the mandible or nose due to the strong structural support of this bone. The midface consists of alternating thick and thin sections of bone that are capable of resisting significant force. This structurally strong bone provides protection for the globes and brain, projection of the midface, and support for occlusion. Reestablishing continuity of these buttresses is the foundation on which maxillary fracture treatment is based.

Renee LeFort (1901) provided the earliest classification system of maxillary fractures. His model described “great lines of weakness in the face” using low-velocity impact forces directed against cadaver skulls. A discussion of fractures of the maxilla would not be complete without a description of LeFort’s work.

The Lefort I fracture, or transverse fracture, extends through the base of the maxillary sinuses above the teeth apices essentially separating the alveolar processes, palate, and pterygoid processes from the facial structures above. This transverse fracture across the entire lower maxilla separates the alveolus as a mobile unit from the rest of the midface. Fracture dislocations of segments of the alveolus may be associated with this fracture. With high-energy injuries, the palate may be split in the midline in addition to the LeFort I fracture.

A pyramidal fracture of the maxilla is synonymous with a LeFort II fracture. This fracture pattern begins laterally, similar to a LeFort I, but medially diverges in a superior direction to include part of the medial orbit as well as the nose. The fracture extending across the nose may be variable, involving only the nasal cartilage or as extensive as to separate the nasofrontal suture.

Radiographic evaluation of the fracture is mandatory and may include both plain films and a computed tomographic (CT) scan. The CT scan has now essentially replaced plain films as the “gold standard” in both evaluation and treatment planning. If physical findings and plain films are not suggestive of a zygomatic fracture, the evaluation may end here. However, if they do suggest fracture, a coronal and axial CT scan should be obtained. The CT scan will accurately reveal the extent of orbital involvement, as well as degree of displacement of the fractures. This study is vital for planning the operative approach.

Historically, closed reduction was the method of choice for nearly all zygomatic fractures. Multiple methods were employed, but most involved simply exerting pressure underneath the malar eminence and popping the fragments back into alignment. Not only were these results frequently unsatisfactory, but they were fraught with complications including persistent diplopia, orbital dystopia, malunion, and significant residual deformity. In our own experience, closed reductions yield unpredictable results with significant chance of relapse. We feel that plate and screw fixation is now the standard of care.

The treatment of zygomatic fractures has dramatically progressed over the past several decades from an entirely closed approach to the more aggressive open reduction and rigid miniplate fixation of today. If a zygomatic fracture is displaced, we do an open reduction and rigid stabilization with mini- and microplates. The floor of the orbit is routinely explored and reconstructed, if needed, to restore orbital volume. The complications of an inadequately or unreduced zygomatic fracture are very difficult to correct secondarily and usually avoidable. We feel that early diagnosis combined with this aggressive surgical treatment yields the best results.

MAXILLARY FRACTURES

The maxilla forms the largest component of the middle third of the facial skeleton. The maxilla is a key bone in the midface that is closely associated with adjacent bones providing structural support between the cranial base and the occlusal plane. Fractures of the maxilla occur less frequently than those of the mandible or nose due to the strong structural support of this bone. The midface consists of alternating thick and thin sections of bone that are capable of resisting significant force. This structurally strong bone provides protection for the globes and brain, projection of the midface, and support for occlusion. Reestablishing continuity of these buttresses is the foundation on which maxillary fracture treatment is based.

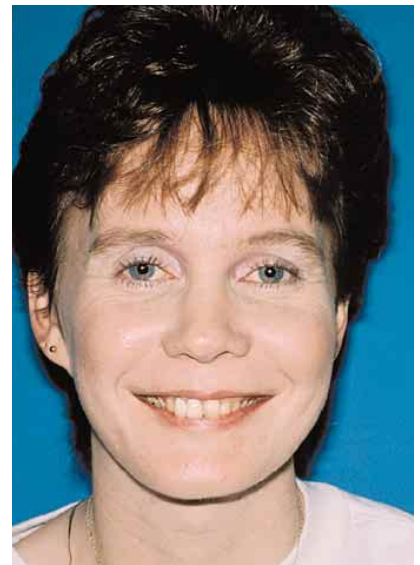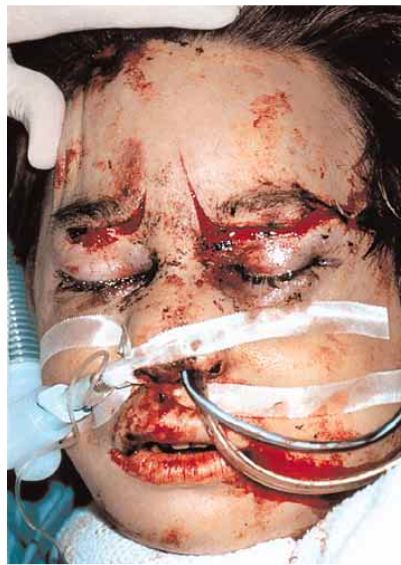Renee LeFort (1901) provided the earliest classification system of maxillary fractures. His model described “great lines of weakness in the face” using low-velocity impact forces directed against cadaver skulls. A discussion of fractures of the maxilla would not be complete without a description of LeFort’s work.

The Lefort I fracture, or transverse fracture, extends through the base of the maxillary sinuses above the teeth apices essentially separating the alveolar processes, palate, and pterygoid processes from the facial structures above. This transverse fracture across the entire lower maxilla separates the alveolus as a mobile unit from the rest of the midface. Fracture dislocations of segments of the alveolus may be associated with this fracture. With high-energy injuries, the palate may be split in the midline in addition to the LeFort I fracture.

A pyramidal fracture of the maxilla is synonymous with a LeFort II fracture. This fracture pattern begins laterally, similar to a LeFort I, but medially diverges in a superior direction to include part of the medial orbit as well as the nose. The fracture extending across the nose may be variable, involving only the nasal cartilage or as extensive as to separate the nasofrontal suture.

The fracture extends diagonally from the pterygoid plates through the maxilla to the inferior orbital rim and up the medial wall of the orbit to the nose. This separates the maxillary alveolus, medial wall of the orbit and nose as a separate piece.

A LeFort III fracture or craniofacial dysjunction denotes a complete separation of the midface or facial bones from the cranium. This fracture transverses the zygomaticofrontal suture, continues through the floor of the orbit, and finally through the nasofrontal suture. The bones of the orbit are separated through the lateral wall, floor, and medial wall. It is unusual to have this fracture as a single segment of bone; more commonly, it comminutes with varying combinations of

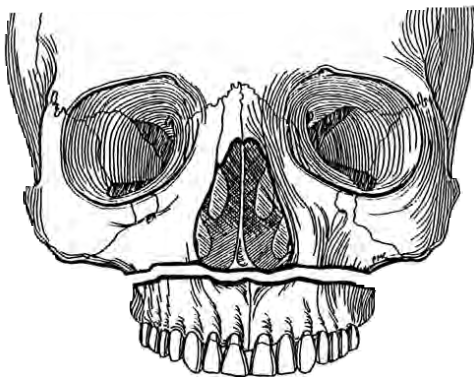


Twenty-four year old woman involved in motor vehicle accident sustaining panfacial fractures.

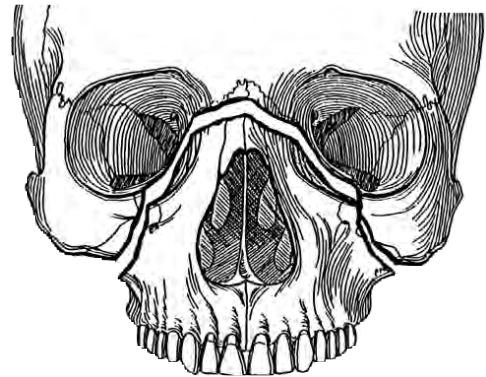
Postoperative photo after one stage repair using craniofacial techniques.

LeFort classification of midfacial fractures.

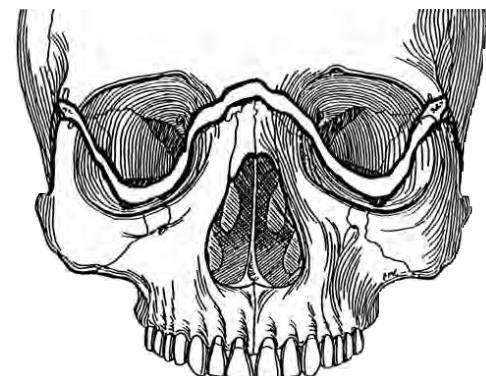A.



B.



C.



LeFort classification of midfacial fractures.

- (A) *LeFort I or transverse fracture of the maxilla.*
- (B) *LeFort II or pyramidal fracture of the maxilla.*
- (C) *LeFort III or craniofacial dysjunction.*

zygomatic, nasoethmoid, and orbital fractures. The fractures may not be symmetric on both sides and minimal mobility may be present.

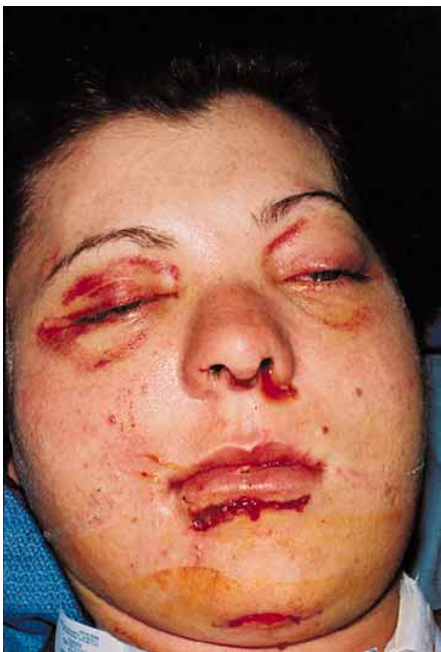Maxillary fractures today are often the result of motor vehicle accidents. These high-velocity injuries many times produce fracture patterns not classified by the standard LeFort system, but are described simply by the anatomic structure fractured and the degree of comminution present. Computerized tomographic (CT) scans and the more recent development of three-dimensional reconstructions have aided greatly in the diagnosis, classification, and preoperative planning of these complex maxillary fractures.

Maxillary fractures are treated by reduction and immobilization. Establishment of preinjury occlusion and midface buttress alignment provides the foundation for this treatment. The goals of treatment of LeFort

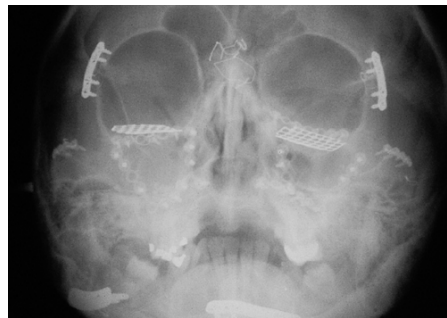

fractures are to reestablish preinjury occlusion with normal height and projection of the face. To accomplish this, the structural buttress of the maxilla must be aligned and stabilized to provide the necessary support and contour to the midface. The proper occlusal relationship between the dental arches is established with intermaxillary fixation (IMF), or more appropriately termed maxillomandibular fixation. Early placement of the patient in IMF can eliminate some of the secondary deformities caused by LeFort fractures. IMF is established by securing arch bars to the upper and lower dental arches with individual wire ligatures around the teeth. The appropriate occlusion is then determined by wear facets, and the maxillary and mandibular arch bar are secured together. This is one of the simplest and most effective forms of treatment. However, IMF is more commonly used in conjunction with other immobilization and stabilization techniques.

Recent advances in the treatment of maxillary fractures have been the use of extended open-

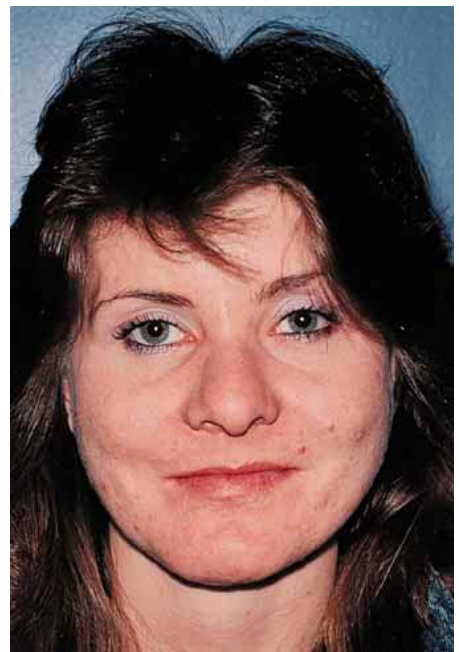Maxillary Fractures



Twenty-eight year old patient with panfacial fractures.



(Top photo) Three Dimensional CT Scan shows comminuted maxillary fractures. (Lower photo) Postoperative radiograph shows rigid fixation of all four buttresses.



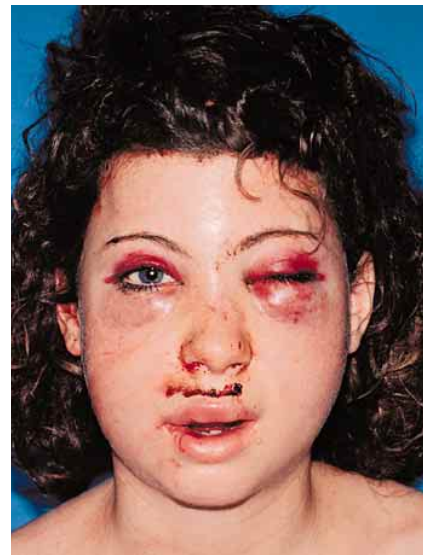Postoperative result with restoration of preinjury appearance.

reduction techniques with rigid plate and screw fixation of the facial buttresses. Bone grafts have been used to replace missing or comminuted bone with early treatment of these injuries. This more aggressive surgical approach has dramatically improved the aesthetic results now obtainable with fewer secondary deformities.

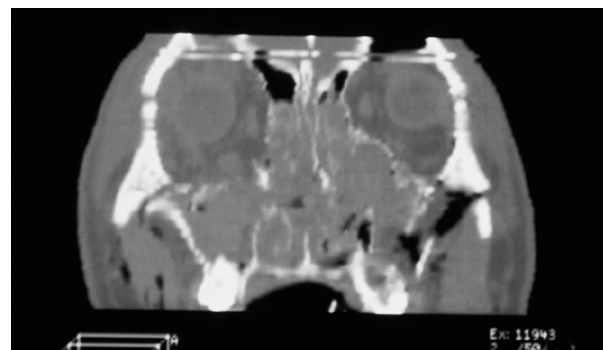
NASOETHMOID ORBITAL FRACTURES

Trauma to the central midface frequently results in fractures of the nasoethmoid orbital (NOE) skeleton. This complex area consists of a union of bones from the nose, orbits, maxilla, and cranium. These fractures may be the most difficult and challenging of all facial fractures to diagnose and treat. To the inexperienced examiner, NOE fractures may be misdiagnosed as simple nasal fractures, and a high degree of suspicion is necessary to make the diagnosis. These fractures may occur as isolated injuries or as part of more complex (LeFort) facial fractures. Swelling of the nose and medial canthal areas may mask the fractures and make the physical findings obscure. Failure to diagnose these injuries or inadequate treatment will result in both functional and cosmetic deformities that are very difficult to correct secondarily.

The successful surgical treatment of these complex injuries consist of early open repair with precise reduction and stabilization of bone fragments. Bone grafts are used to restore contour and support to areas of extremely comminuted or missing bone. Soft tissue management of the naso-orbital area is crucial to restoration of preinjury appearance. The application of craniofacial techniques in recent years has greatly enhanced the results now obtainable.



Twenty year old female with Lefort I maxillary fracture and malocclusion.



CT scan shows fractures of all maxillary buttresses.



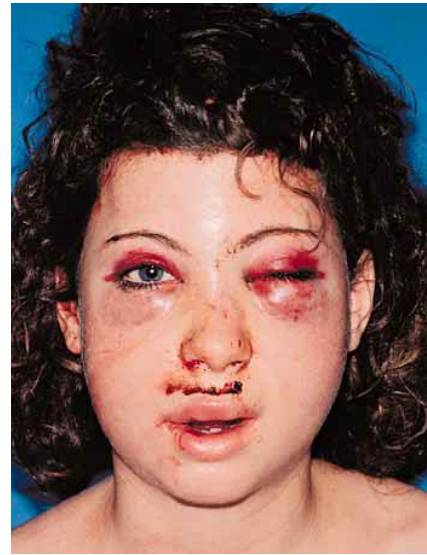Postoperative result after open reduction and rigid fixation.

reduction techniques with rigid plate and screw fixation of the facial buttresses. Bone grafts have been used to replace missing or comminuted bone with early treatment of these injuries. This more aggressive surgical approach has dramatically improved the aesthetic results now obtainable with fewer secondary deformities.

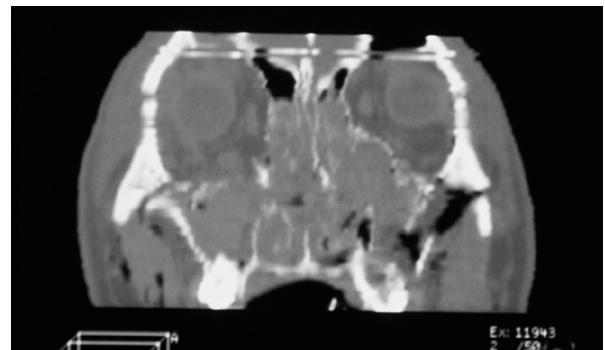
NASOETHMOID ORBITAL FRACTURES

Trauma to the central midface frequently results in fractures of the nasoethmoid orbital (NOE) skeleton. This complex area consists of a union of bones from the nose, orbits, maxilla, and cranium. These fractures may be the most difficult and challenging of all facial fractures to diagnose and treat. To the inexperienced examiner, NOE fractures may be misdiagnosed as simple nasal fractures, and a high degree of suspicion is necessary to make the diagnosis. These fractures may occur as isolated injuries or as part of more complex (LeFort) facial fractures. Swelling of the nose and medial canthal areas may mask the fractures and make the physical findings obscure. Failure to diagnose these injuries or inadequate treatment will result in both functional and cosmetic deformities that are very difficult to correct secondarily.

The successful surgical treatment of these complex injuries consist of early open repair with precise reduction and stabilization of bone fragments. Bone grafts are used to restore contour and support to areas of extremely comminuted or missing bone. Soft tissue management of the naso-orbital area is crucial to restoration of preinjury appearance. The application of craniofacial techniques in recent years has greatly enhanced the results now obtainable.



Twenty year old female with Lefort I maxillary fracture and malocclusion.



CT scan shows fractures of all maxillary buttresses.



Postoperative result after open reduction and rigid fixation.

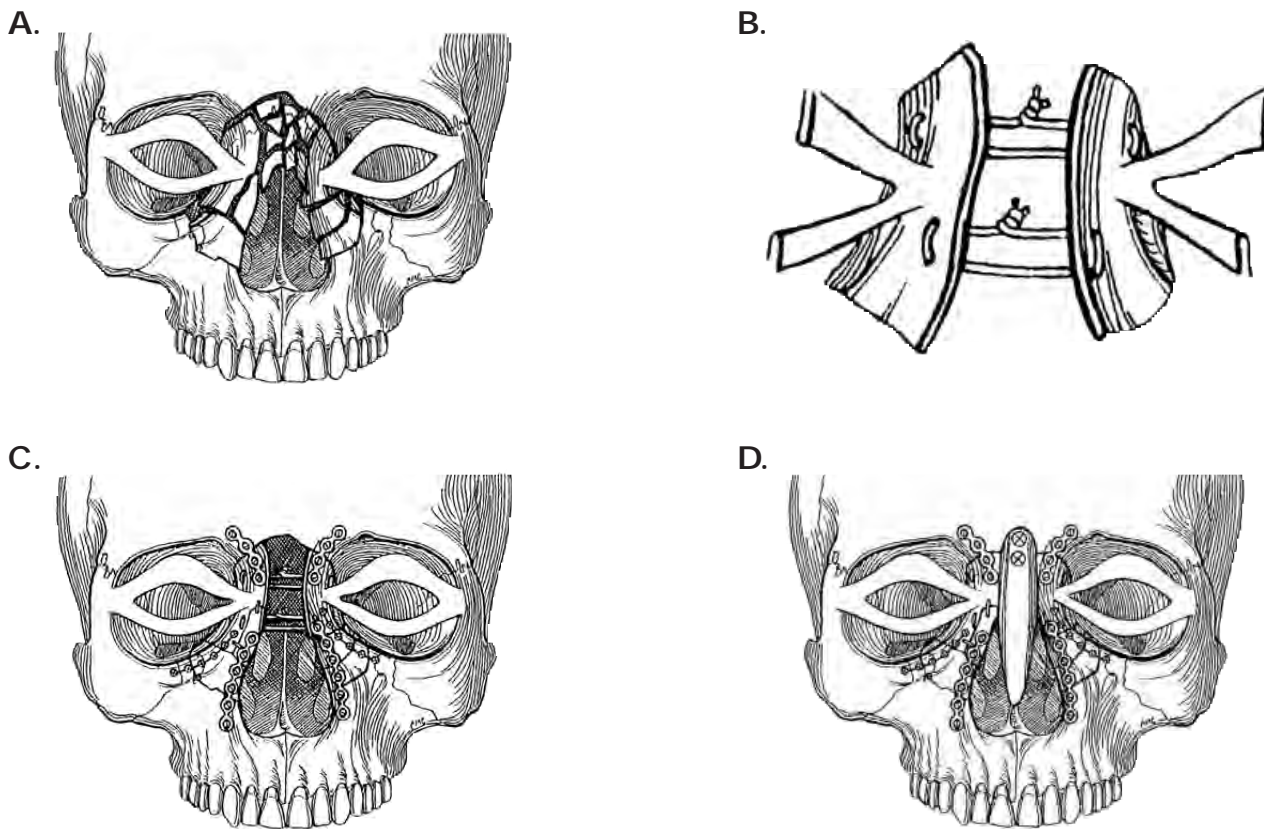
The nasoethmoid region is an intricate confluence of bones that makes up the complex anatomy of the central-upper midface. Identifying and understanding the structural buttresses are crucial to restoring the normal anatomy and appearance of the region. By definition, the nasoethmoid fracture involves disruption of the inferior orbital rim, lateral nasal bones, medial orbital wall, and frontal process of the maxilla. Essentially the medial orbital rim buttress to which the medial canthal tendon is attached is dislocated. It is the operative reduction and stabilization of this central segment of bone that is the key to successful treatment of this injury.

There are a number of potential pitfalls in

the surgical treatment of NOE fractures. Once this injury has been diagnosed, the extent of the fracture is determined by physical exam and the CT scan. A definitive early open reduction with stabilization of the fractures utilizing the techniques of craniofacial surgery is then accomplished.

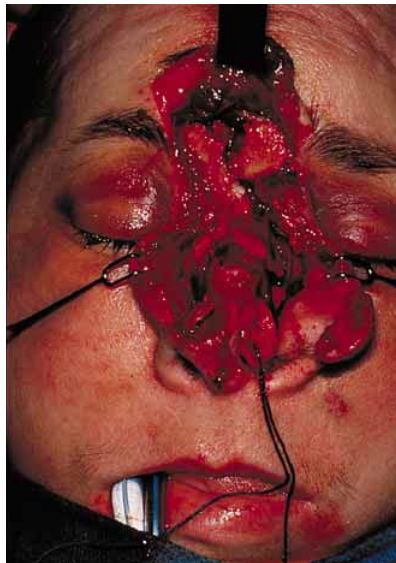The best results of the NOE fracture are obtained with early diagnosis and aggressive surgical treatment. Complications result when this injury has been misdiagnosed or inadequately treated. Unstable or displaced fractures that are left untreated result in permanent deformities once healed. Late reconstruction is a difficult task that requires repositioning of both bone and soft tissue.

Nasoethmoid Fracture and Repair

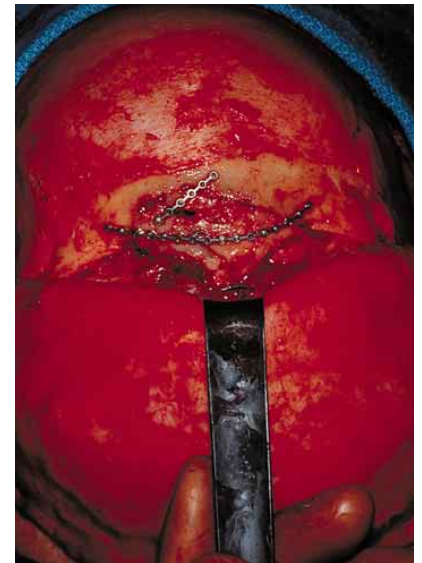


(A) Diagram illustrates a bilateral comminuted NOE fracture. **(B)** Closeup showing reduction of central bone fragments and stabilization with wires. Comminuted midline nasal bone fragments have been temporarily removed providing exposure to nasal side of medial orbital wall fractures. Two circular transnasal wires are used: (1) one posterior and superior to the tendon insertion, and (2) one anterior and inferior to the tendon insertion. **(C)** Superior and inferior orbital rim fragments are reduced and stabilized with miniplates as illustrated. **(D)** Nasal bones are frequently reconstructed with a cantilever bone graft secured with lag screws or a miniplate.

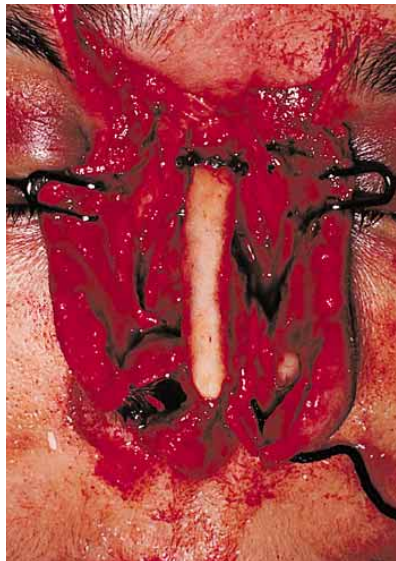Incomplete reduction of the medial orbital rim fragment, which contains the canthal tendon, can result in a widening of the interorbital distance or a telecanthus. Asymmetric repair, inadequate stabilization, and inadvertent stripping of the medial canthal tendon can all contribute to this problem. Inaccurate assessment of the nasal bones and septal support can lead to contour deformity of the nose with inadequate tip projection. Close attention is needed for reconstruction of the orbital wall fracture to avoid the enlargement of the orbital volume and resultant enophthalmos and vertical orbital dystopia. Although late reconstruction of these deformities is possible, in general, the best aesthetic results are obtained with definitive repair at the time of injury, avoiding the common pitfalls.



A.



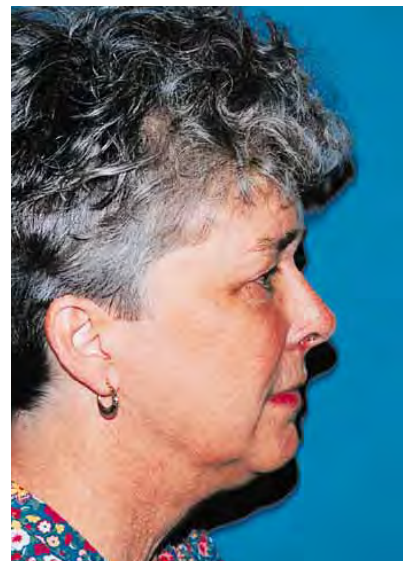B.



C.



D.



E.

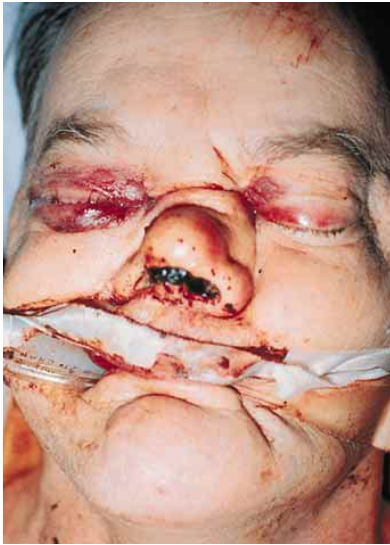Nasoethmoid Fracture

- (A) Fifty-four year old woman involved in a motor vehicle accident sustained extensive soft tissue injuries and comminuted bilateral nasoethmoid fractures.
- (B) Fractures were reduced and stabilized with miniplates and transnasal wires.
- (C) Septal Support was destroyed and reconstruction with a cantilever calvarial bone graft was required.
- (D,E) Postoperative appearance after acute one stage repair.

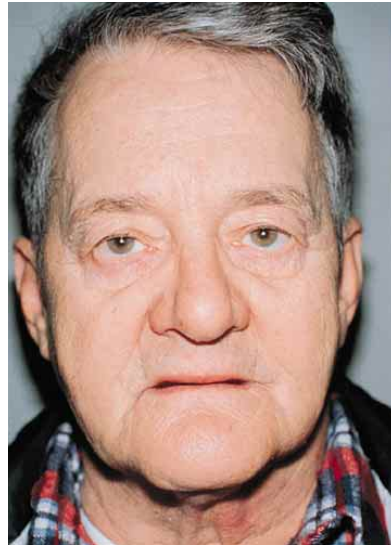INTERNAL ORBITAL FRACTURES

Trauma to the upper face frequently results in fractures of the internal orbit. These may occur as isolated blowouts or associated with more complex adjacent facial fractures. The range of potential injuries to the internal orbit may vary from a small orbital floor defect to destruction of all four walls. Despite this potential for wide variation of internal orbital fractures, there are basic principles that can be applied to aid in diagnosis and treatment. The bony orbits play a vital role in maintaining normal function and aesthetics of the eyes. Accurate realignment or anatomic reconstruction of the bony orbit is essential to maintain normal function and appearance.

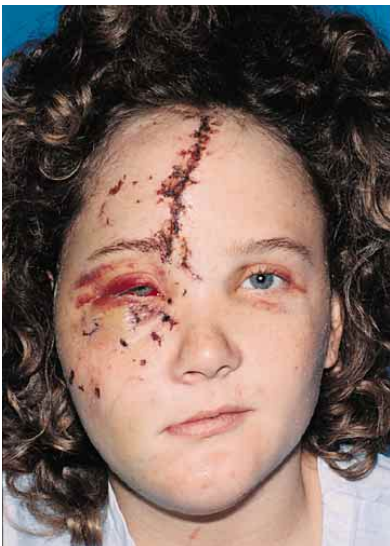A number of advances have been made in the past 10 to 15 years in the diagnosis and treatment of internal orbital fractures. The computerized tomographic (CT) scan has dramatically enhanced the surgeon's ability to diagnose and determine the extent of the internal orbital fractures. Three-dimensional scans may even further enhance this radiographic evaluation. With the development of the field of craniofacial surgery, surgical techniques have also significantly improved in this area. These techniques have allowed extended exposure of the fractures, which greatly facilitates assessment and treatment of orbital injuries. Better exposure allows more precise reduction and rigid stabilization of the fractures. The other major advancement in orbital surgery has been the use of rigid fixation to provide a stable internal orbital reconstruction.



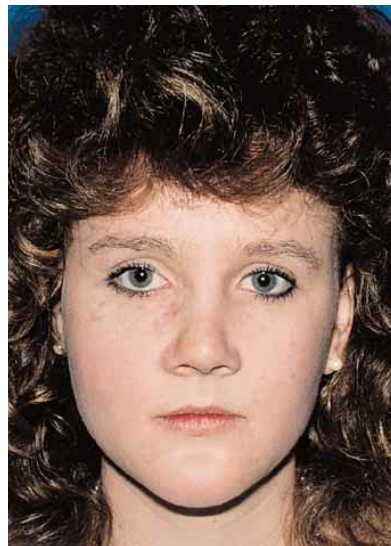Elderly man in motor vehicle accident with telescoping in of nasoethmoid complex.



Postoperative result following immediate repair of fractures and reconstruction of nose.



Twenty year old female with comminuted nasoethmoid orbital fractures.



Postoperative result after open reduction and rigid fixation of all fractures.

The use of mini- or microplates and metal meshes in combination with bone grafts has also improved stabilization and enhanced the healing of orbital fractures.

The recommended treatment of these injuries varies greatly in the literature with the best method of reconstruction remaining controversial. Surgical treatment has ranged from packing of the maxillary antrum to total orbital reconstruction with autogenous or synthetic materials. Accurate anatomic reconstruction is essential to restore function and appearance of the eye.

Because most of the bone of the internal orbit is thin and weak, it is frequently difficult to reduce and adequately stabilize without the use of autogenous or alloplastic materials.

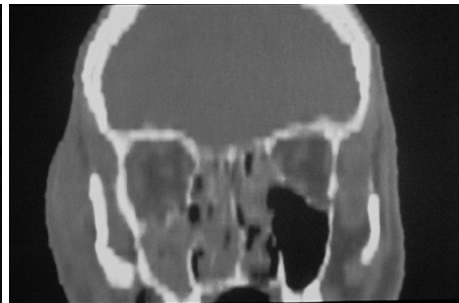
Autogenous bone grafts have been the material most often used by craniomaxillofacial surgeons for reconstruction of the internal orbit. Split calvarial bone has gained popularity because of its low rate of infection and decreased resorption. Other autogenous materials that have been used include iliac bone, split rib, and cartilage. Resorption may be a problem with the use of autogenous bone. Each of these materials also requires a donor area, although donor site morbidity is usually very small.

A variety of alloplastic material such as silicone, teflon, tantalum mesh, polyethylene, and methyl methacrylate have been used for orbital reconstruction. The primary concern with the use of alloplastic material has been the risk of infection with extrusion. The metal miniplates systems have been very successful in the treat-

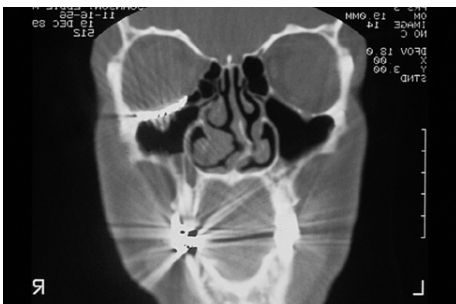Internal Orbital Fractures



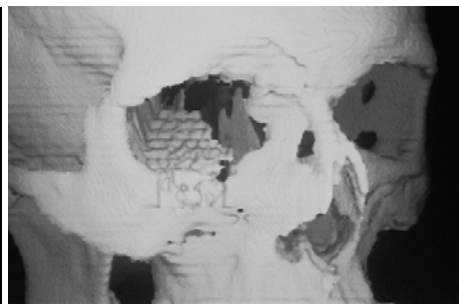
Titanium micromesh used to reconstruct internal orbit.




Preoperative CT Scan demonstrates right orbital blowout fracture in thirty-three year old patient that clinically exhibited enophthalmos.



Postoperative CT Scan shows reconstruction of orbital floor with metal mesh.



Postoperative three dimensional scan shows mesh extending into posterior third of orbit, reconstructing almost entire orbital floor.

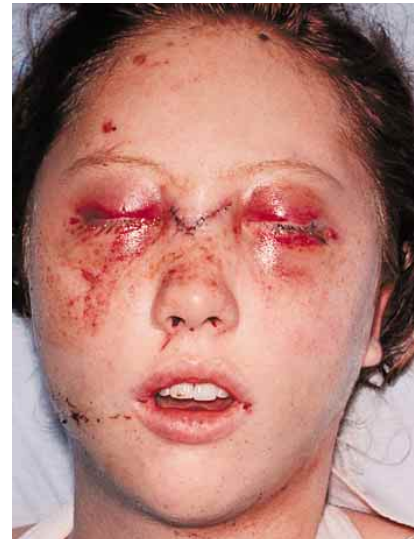

Postoperative result with normal position and function of eye.

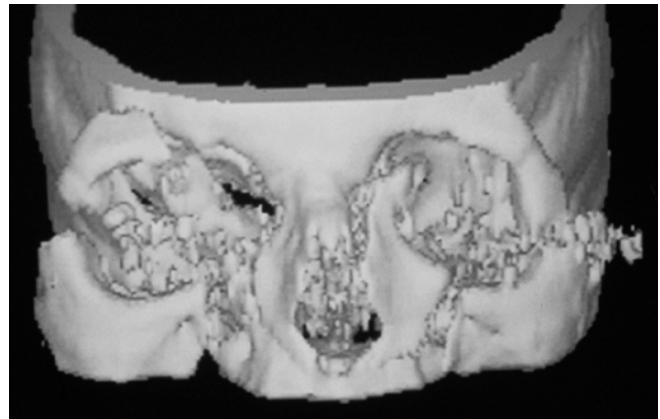
ment of facial fractures. These techniques of rigid fixation using metal meshes have also been applied successfully to the treatment of internal orbital fractures. In our experience of reconstructing over 300 internal orbital fractures with metal mesh, we have found this technique to be both safe and effective with no infections as a result of using metal mesh.

The goal of surgical treatment of blowout fractures is to replace orbital contents back into the bony orbit and to restore normal orbital volume and shape. The best method of reconstruction of internal orbital fractures remains controversial. A number of techniques have been described using autogenous grafts or alloplastic materials. We have had good success with the use of metal mesh alone, without bone grafts, for the reconstruction in internal orbital defects. This micromesh is our preference when alloplastic material is used. It is rigid yet malleable and can provide excellent orbital support for large defects, particularly in the posterior aspect of the orbit. This is important, since accurate anatomic reconstruction of both orbital shape and volume is crucial to obtain the best possible results.

Significant advancements have been made in the evaluation and treatment of internal orbital fractures. CT has greatly enhanced our ability to identify the exact location and extent of destruction of internal orbital fractures. Early operative intervention combined with wide exposure, meticulous reduction, and rigid fixation has significantly enhanced the treatment of internal orbital fractures.



This patient sustained blunt trauma to the face.



Three dimensional scan shows complex orbital fractures.

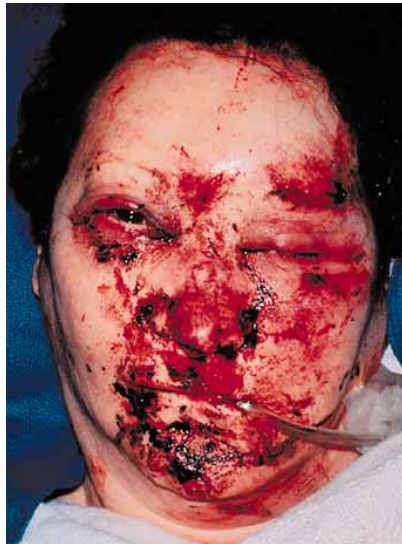

Postoperative result after extensive open reduction and rigid fixation.

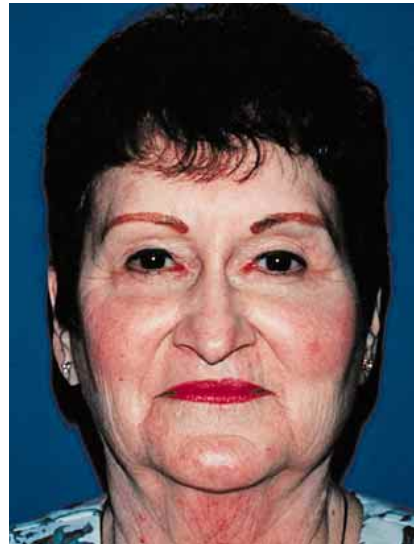MANDIBULAR FRACTURES

The mandible is a unique bone having a complex role in both aesthetics of the face and functional occlusion. Because of the prominent position of the lower jaw, mandible fractures are the most common fracture of the facial skeleton.

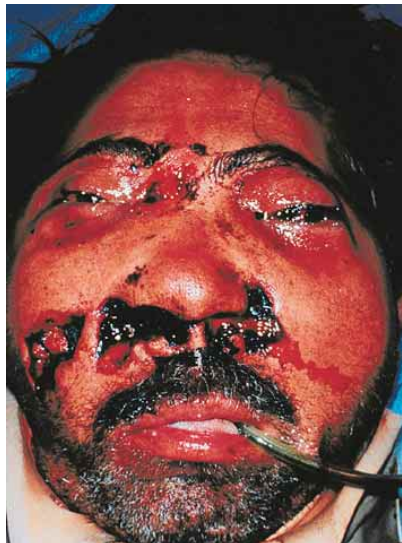Fractures of the mandible should be classified according to the site of the fracture, degree of displacement, presence of comminution and status of the dentition. Physical examination will typically reveal a malocclusion, pain at fracture site, mucosal ecchymosis or laceration with bleeding between teeth at the fracture site. Plain radiographs can help further define the fractures of the mandible. In a patient with an isolated jaw injury, a Panorex is the ideal radiograph to visualize the fracture and condition of the teeth. In the multisystem injured patient a computerized tomographic scan with three dimensional reconstruction provides good visualization of the frac-



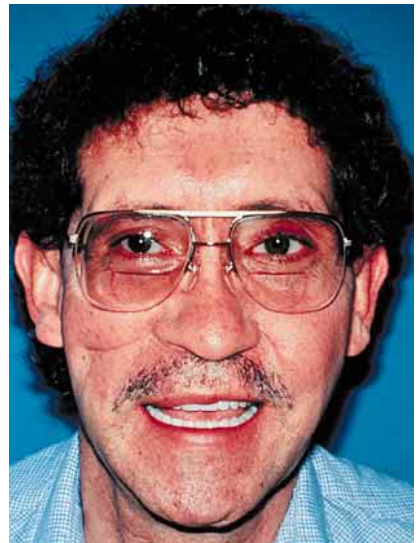Sixty-six year old female sustaining complex comminuted fractures to all bones of face.



Postoperative result after one stage repair.

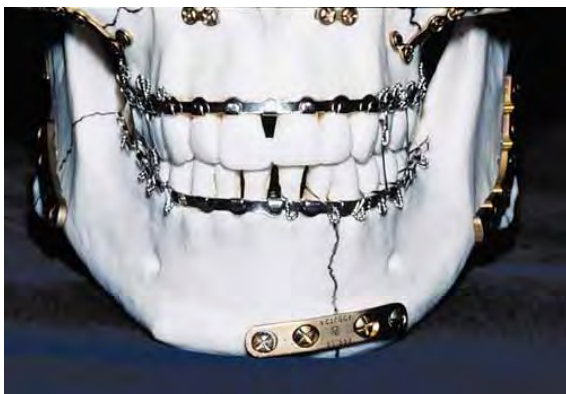

This patient sustained severe complex fractures of all facial bones with loss of right eye.



Postoperative result after one stage repair.

Mandibular Fractures



Skull with mandibular plates.



Rigid fixation of mandibular fractures shown on skull using titanium plates.

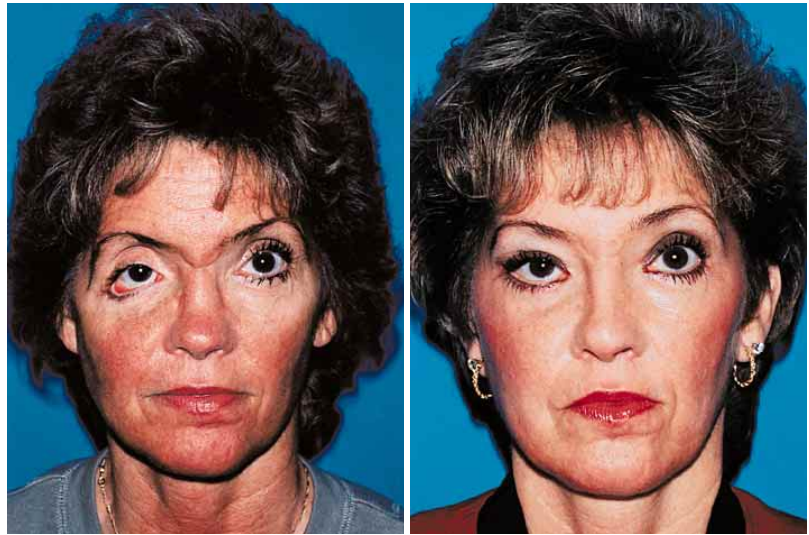tures.

Reduction and stabilization of the mandible fracture is the key to successful treatment. The method of management may vary based on the severity, location of the fracture and presence or absence of teeth. Mandible fractures are usually treated by closed reduction with wiring of the teeth or open reduction with internal rigid fixation using plates. Nonoperative management of a mandible fracture with a soft diet is rarely indicated. The technique of closed reduction involves wiring of arch bars on the teeth and intermaxillary fixation for 4 to 6 weeks. Internal rigid fixation requires exposure of the fracture sites and stabilization with plates and/or screws. This technique can frequently avoid postoperative intermaxillary fixation (wiring teeth together) and the problems associated with this such as weight loss and joint stiffness.

Following the principles of accurate reduction with good stabilization can frequently avoid complications and help to restore the patients primary occlusion and facial appearance.

POST-TRAUMATIC FACIAL DEFORMITIES

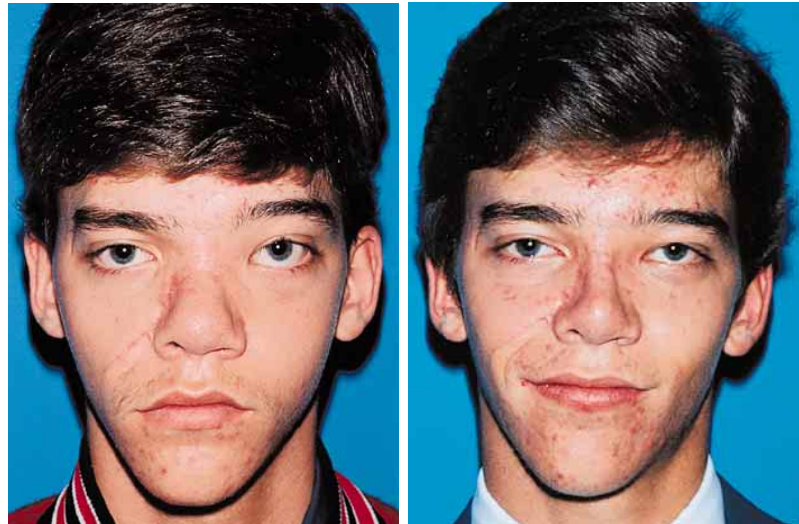The best way to prevent post-traumatic facial deformities is to obtain the appropriate treatment at the time of the injury. Applying the latest craniofacial techniques can in many cases make major secondary revisions unnecessary. However, despite the many advances that have come from the field of craniofacial surgery, there are still patients that end up with significant deformities. These are patients that for whatever reason are treated



Preoperative

Postoperative

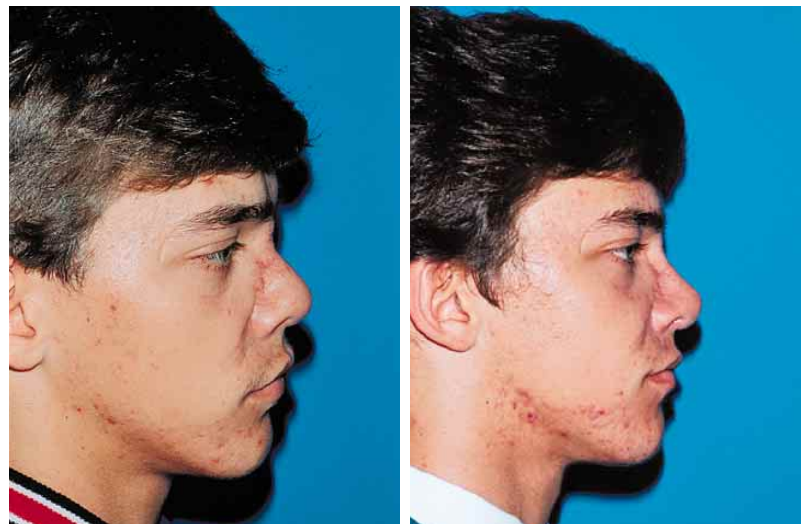This patient has longstanding post-traumatic right enophthalmos and ectropion.



Preoperative

Postoperative

Post-traumatic facial deformity with displaced nasoethmoid complex.



Preoperative

Postoperative

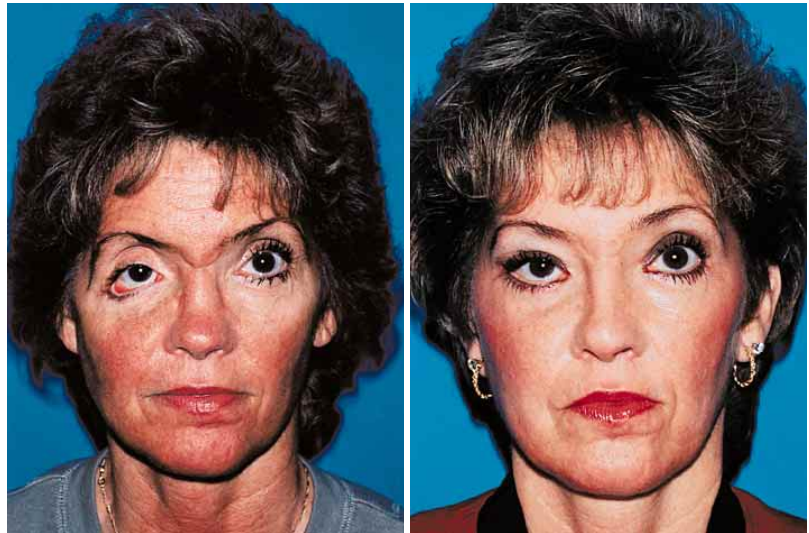tures.

Reduction and stabilization of the mandible fracture is the key to successful treatment. The method of management may vary based on the severity, location of the fracture and presence or absence of teeth. Mandible fractures are usually treated by closed reduction with wiring of the teeth or open reduction with internal rigid fixation using plates. Nonoperative management of a mandible fracture with a soft diet is rarely indicated. The technique of closed reduction involves wiring of arch bars on the teeth and intermaxillary fixation for 4 to 6 weeks. Internal rigid fixation requires exposure of the fracture sites and stabilization with plates and/or screws. This technique can frequently avoid postoperative intermaxillary fixation (wiring teeth together) and the problems associated with this such as weight loss and joint stiffness.

Following the principles of accurate reduction with good stabilization can frequently avoid complications and help to restore the patients primary occlusion and facial appearance.

POST-TRAUMATIC FACIAL DEFORMITIES

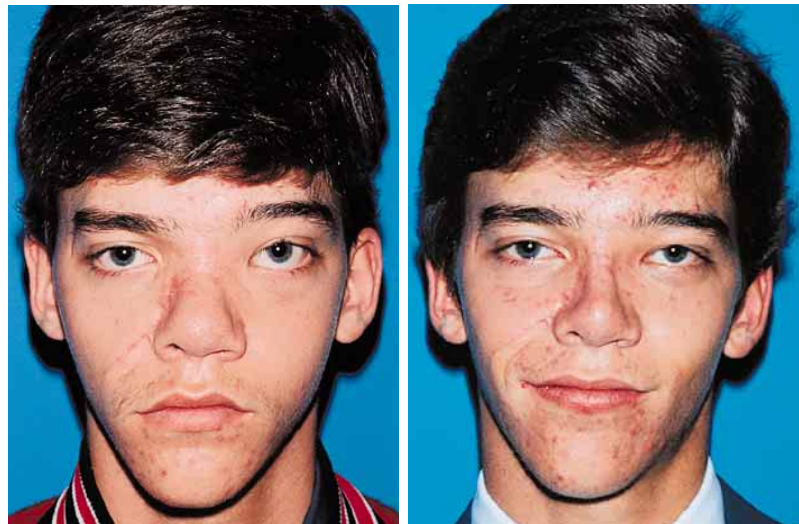The best way to prevent post-traumatic facial deformities is to obtain the appropriate treatment at the time of the injury. Applying the latest craniofacial techniques can in many cases make major secondary revisions unnecessary. However, despite the many advances that have come from the field of craniofacial surgery, there are still patients that end up with significant deformities. These are patients that for whatever reason are treated



Preoperative

Postoperative

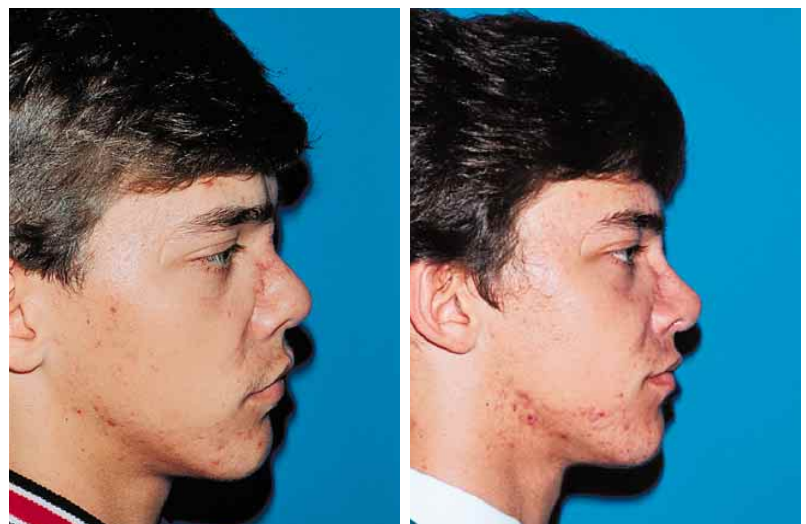This patient has longstanding post-traumatic right enophthalmos and ectropion.



Preoperative

Postoperative

Post-traumatic facial deformity with displaced nasoethmoid complex.



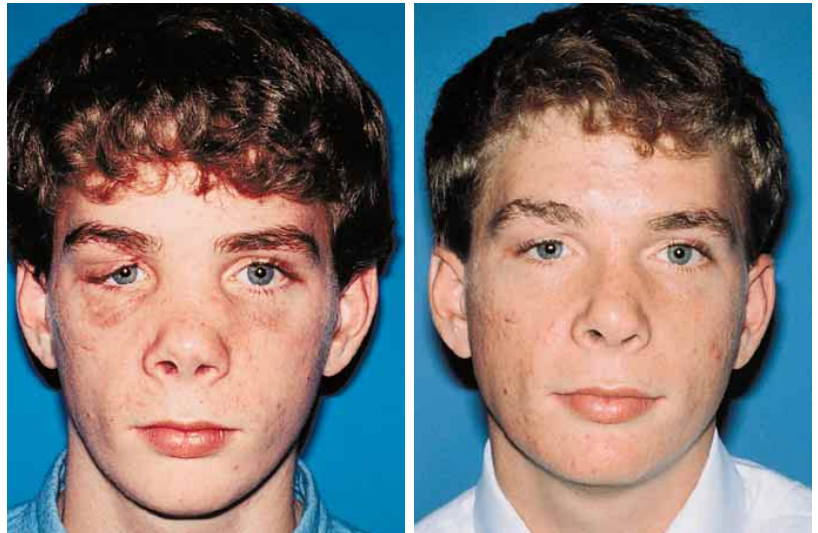Preoperative

Postoperative

inadequately or because of life-threatening other injuries, do not receive any treatment of their facial injuries.

Unrepaired or inadequately reduced facial fractures can result in a wide range of severe cosmetic and functional deformities. Unrepaired fractures around the orbits can cause a sunken-in appearance of the eyes, nasal deformities, as well as functional problems with vision (double vision). Unrepaired injuries of the middle and lower face can cause contour deformities, flattening of the cheeks, or malocclusion of the teeth with difficulty chewing. These are but a few of the many problems associated with post-traumatic facial deformities.

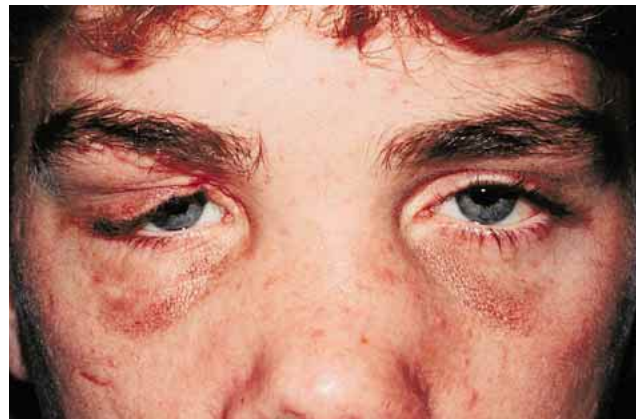Late repair or reconstruction after the soft tissue and bones have healed is much more difficult than repair at the time of initial injury. Reconstruction requires wide exposure which enables the surgeon to have direct visualization of the bony deformities. Bone cuts are then made to reposition the displaced bone and reattach the soft tissue back into its normal position. Missing or severely deformed bone may require replacement with bone grafts. These operative procedures all use the standard techniques of craniofacial surgery.



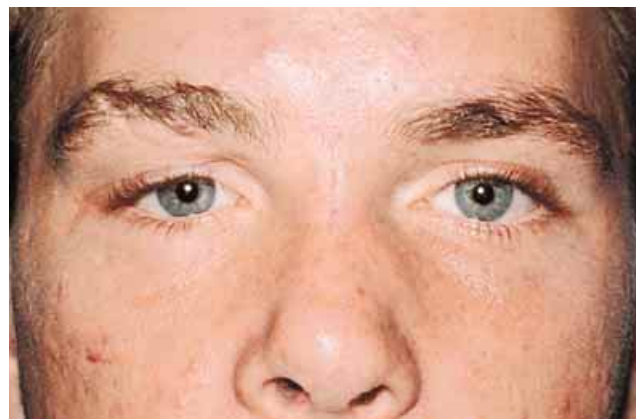Preoperative

Postoperative

A seventeen year old patient with inadequately treated nasoethmoid orbital fractures.



Preoperative



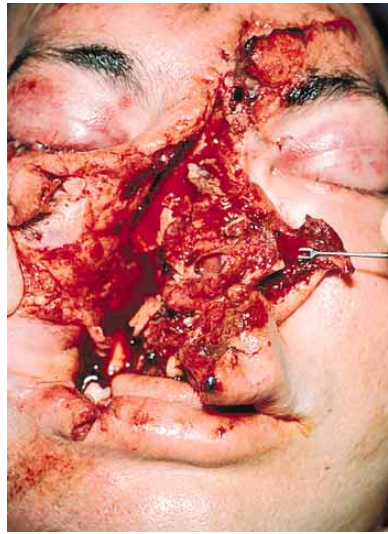Postoperative result one year after late reconstruction.

SOFT TISSUE DEFORMITIES

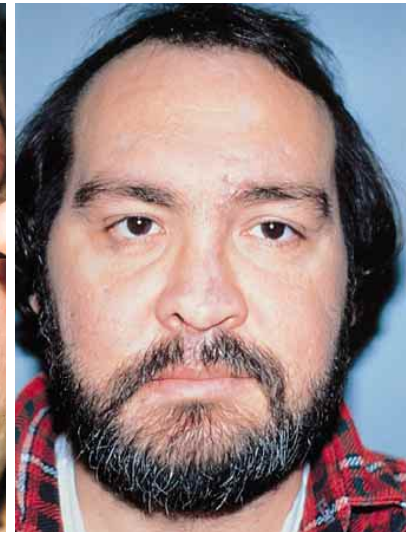
Soft tissue deformities may involve the skin, subcutaneous tissue, underlying muscle or a combination of any of these elements. There are a number of syndromes such as hemifacial microsomia in which asymmetry of the soft tissue may be a component. However, the number one cause of facial soft tissue deformities is trauma. Traumatic facial injuries may be blunt, penetrating and/or avulsive in nature. An avulsion or loss of soft tissue may create a significant deformity which requires reconstruction. Generally the facial skeletal deformities are reconstructed first followed by correction of soft tissue problems.

One example of a severely deforming and psychologically crippling injury is the scalp avulsion. This presents a very challenging problem particularly if the avulsed portion is very large and cannot be replanted by microvascular technique. A new and innovative approach to this type of problem has been the use of the tissue expander. These expanders are much like deflated balloons placed beneath adjacent normal tissue. Over a period of weeks these expanders are gradually inflated, stretching the normal skin for use in reconstruction. An example of this technique is shown for reconstruction of the scalp.

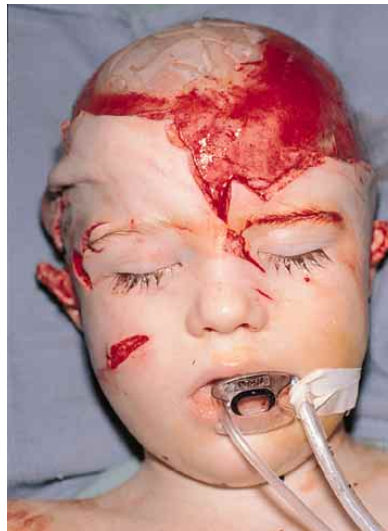Soft tissue tumors are another cause of facial deformities. Resection of either benign or malignant facial tumors can result in a significant cosmetic deformity. Craniofacial techniques can be used to help reconstruct these defects and restore facial appearance.



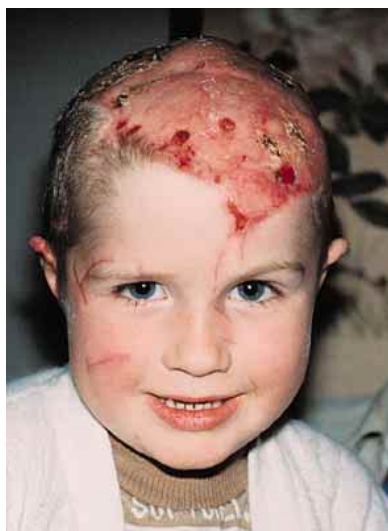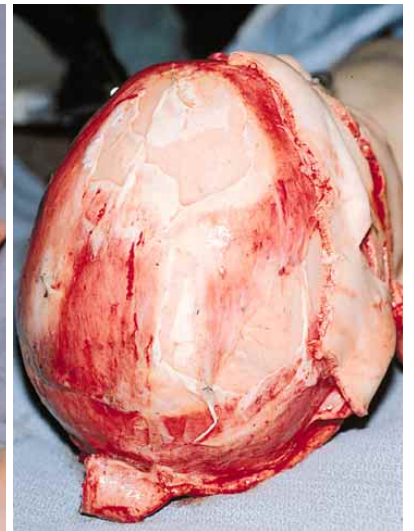
Thirty-five year old male with soft tissue injuries and complex facial fractures.



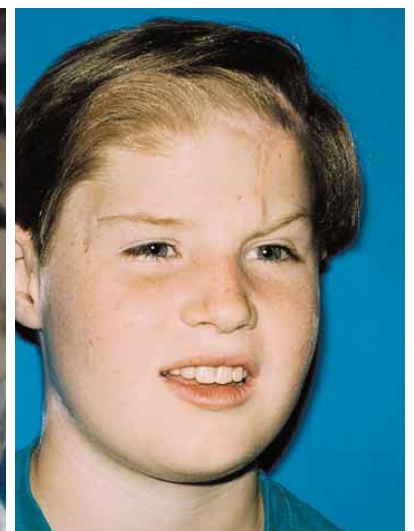
Postoperative result after one-stage reconstruction of soft tissue and bone.



Five year old boy was attacked by a pit bulldog and lost almost all of his scalp and forehead.



This injury was initially repaired with skin grafts.



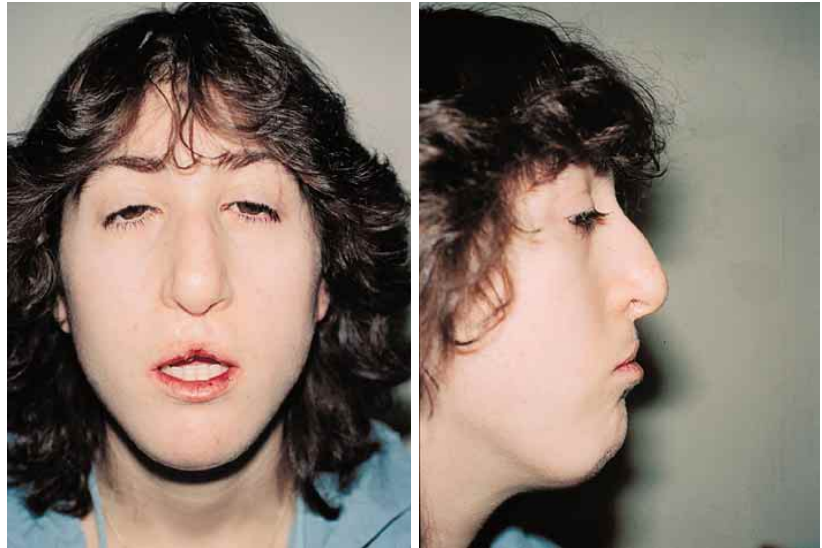Using tissue expanders his entire hair-bearing scalp has been restored.

FACIAL BONE CONTOURING

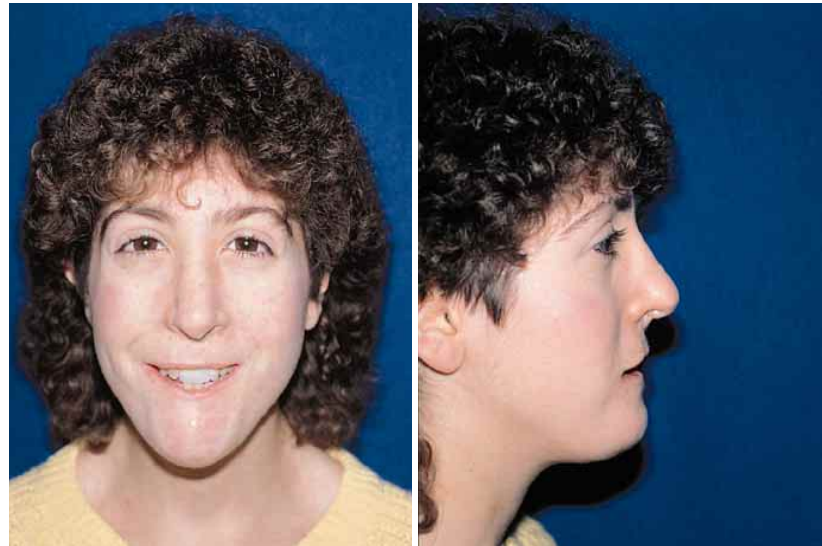The face is basically a soft tissue representation of the underlying skeletal structure. Facial bone contouring is the surgical change in this bony support to produce a more aesthetic appearance. It is not only desirable to correct a particular deformity, but also to improve the entire aesthetic facial harmony. Correction in contour of the facial skeleton can be achieved by osteotomies or by augmenting the skeleton with bone or other materials. After a maxillary or mandibular repositioning, additional bone contouring is often necessary to correct slight asymmetries. Augmentation of such areas as the cheek, chin, or nose can be done in combination with osteotomies or alone.

Stereotypical appearances associated with particular disease processes can often be markedly improved by bony contouring. Patients with facial clefts commonly have a flat maxillary profile due to the deficiency of the facial skeleton over the front of the maxilla and the lower bony rims of the orbits. Contouring with graft materials can give a more normal appearance, thus removing some of the psychological stigmas associated with such deformities.

In many cases, however, facial contouring is requested by patients whose appearance falls well within the normal range. These individuals seek surgery to enhance their appearance, not



Seventeen year old female with facial imbalance and notching of upper lip secondary to bilateral cleft lip and palate.



Postoperative result after Abbe Flap (lip switch) upper lip reconstruction, advancement of maxilla, chin, and rhinoplasty.

to radically change it. Cheek augmentation is a good example. The aesthetic refinements of bony contouring used in combination with osteotomies when necessary allow the craniofacial surgeon to obtain the optimum aesthetic results.

FACIAL BONE CONTOURING

The face is basically a soft tissue representation of the underlying skeletal structure. Facial bone contouring is the surgical change in this bony support to produce a more aesthetic appearance. It is not only desirable to correct a particular deformity, but also to improve the entire aesthetic facial harmony. Correction in contour of the facial skeleton can be achieved by osteotomies or by augmenting the skeleton with bone or other materials. After a maxillary or mandibular repositioning, additional bone contouring is often necessary to correct slight asymmetries. Augmentation of such areas as the cheek, chin, or nose can be done in combination with osteotomies or alone.

Stereotypical appearances associated with particular disease processes can often be markedly improved by bony contouring. Patients with facial clefts commonly have a flat maxillary profile due to the deficiency of the facial skeleton over the front of the maxilla and the lower bony rims of the orbits. Contouring with graft materials can give a more normal appearance, thus removing some of the psychological stigmas associated with such deformities.

In many cases, however, facial contouring is requested by patients whose appearance falls well within the normal range. These individuals seek surgery to enhance their appearance, not



Seventeen year old female with facial imbalance and notching of upper lip secondary to bilateral cleft lip and palate.



Postoperative result after Abbe Flap (lip switch) upper lip reconstruction, advancement of maxilla, chin, and rhinoplasty.

to radically change it. Cheek augmentation is a good example. The aesthetic refinements of bony contouring used in combination with osteotomies when necessary allow the craniofacial surgeon to obtain the optimum aesthetic results.

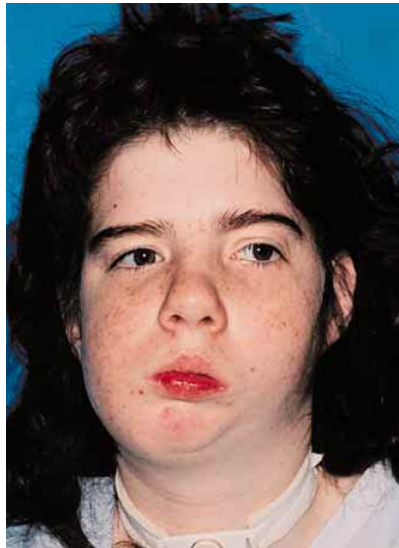HEMIFACIAL MICROSOMIA

The term hemifacial microsomia (HFM) is used to describe a spectrum of complex anomalies characterized by underdevelopment of one side of the face. A variety of terms have been used to identify these facial deformities that result from a developmental malformation of the first and second branchial arches. Such names as craniofacial microsomia, lateral facial dysplasia, first and second branchial arch syndrome, and oculoauriculovertebral dysplasia (Goldenhar's syndrome) have been used to describe this syndrome.

The incidence of HFM is in the range of 1 in 3500 to 4500. The cause of this deformity has not been satisfactorily identified to date. Transmission is usually sporadic, however, reports do exist of the syndrome being inherited. HFM may occur by itself or in association with other anomalies such as Goldenhar's syndrome (oculoauriculovertebral dysplasia). Goldenhar's includes, in addition to a HFM, a bony malformation of the spine and superficial eye lesions called epibulbar dermoids.

The collected group of deformities that make up this syndrome may vary greatly in extent and degree covering a wide spectrum ranging from mild underdevelopment of the lower jaw to severe deformity of the skull and face. Characteristically this deformity, as the name implies (hemifacial), involves one side of the face, however involvement of both sides to

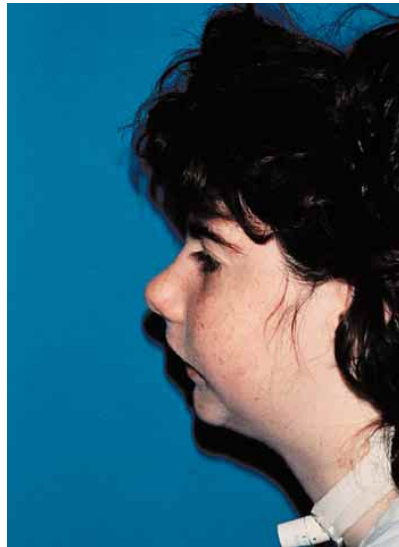Hemifacial Microsomia



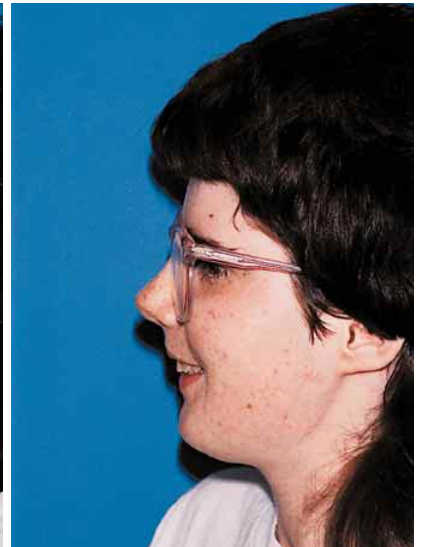Young girl with a left hemifacial microsomia. Microsomia resulted in airway obstruction requiring tracheostomy.



Postoperative result after mandibular lengthening. Tracheostomy was able to be removed due to improved position of mandible.



Preoperative

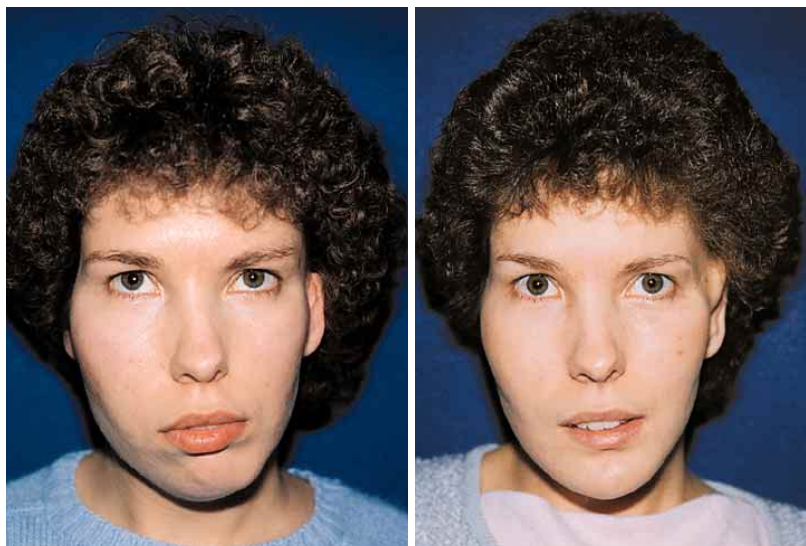

Postoperative

some degree can be observed in as high as 15% of all cases. The most obvious deformity involves the lower jaw and ear, but soft tissue deficiency, maxillary hypoplasia and even orbit and skull anomalies may also be present. Lack of development of the external ear is a common feature with the severity of the ear deformity proportional to the jaw deformity.

These complex problems require a thorough evaluation by the craniofacial team. When we see these patients as infants they are classified according to the severity of the mandibular deformity. Subsequent treatment is individualized being based on this classification and their age at time of evaluation. The goals of treatment are to re-establish facial symmetry (bony and soft tissue), normal occlusion, and hopefully normal joint function. There is some controversy concerning the age in which surgical intervention should be started, however we recommend early surgical correction. In patients born with absent structures, reconstruction of the jaw joint is begun early (before age 6). Children with mild deformities may benefit from the use of an orthodontic device (activator) that attempts to stimulate mandibular growth.

Soft tissue augmentation is performed when necessary after bony skeletal symmetry has been obtained. Ear construction is usually performed at 5-6 years of age. However, in cases of HFM with marked asymmetry of the lower face, ear construction is delayed



Twenty year old woman with left hemifacial microsomia.

Result after surgical correction of jaw and chin deformity and augmentation of cheek.

until bony symmetry is obtained so that the appropriate position of the new ear can be determined.

It is important to remember that HFM is a progressive bony and soft tissue deformity with the earliest and most consistent abnormalities noted in the mandible. In general, we recommend early surgical intervention in an attempt to maximize normal growth forces, minimize secondary deformities, and give the patient the psychological benefits that result from early improved appearance and self esteem.

MÖBIUS SYNDROME: CONGENITAL FACIAL PARALYSIS

Möbius syndrome or congenital facial paralysis is a rare deformity. The exact frequency of occurrence is not known, with only several hundred cases being reported in the literature. This type of facial paralysis has been classically described as bilateral, complete, and permanent. However, the paralysis occasionally may be asymmetric, in which the upper face is effected and the lower lip movement spared. Although uncommon, this syndrome is very distinct.

Bilateral congenital facial paralysis has traditionally been associated with Paul Julius Möbius. In 1888, Möbius described a clinical entity involving bilateral paralysis of the sixth and seventh cranial nerves. He was the first to single out these particular palsies as a separate entity. Hence, the hallmark clinical features of Möbius syndrome are paralysis of the sixth and seventh cranial nerves. The seventh cranial nerve or facial nerve innervates the muscles of facial expression. Paralysis of this nerve results in the mask-like facies and the inability to smile. The paralysis of the sixth cranial nerve results in the inability to abduct the eyes or simply to look to the side by just moving the eyes. Because of this inability to move the eyes laterally, the child follows objects by turning his head from side to side. Patients with Möbius syndrome may also have additional problems. The paralysis may involve other cranial nerves such as the nerve that innervates the tongue. Limb anomalies have been reported in 25% of cases with the most common problem being the club foot. Additional problems can be lack of development of chest musculature such as the pectoral muscles which was present in 15% of the reported cases.

The etiology of this syndrome remains unclear. One hypothesis is that nuclear

hypoplasia or agenesis of the sixth and seventh facial nerves causes the anomaly. Another hypothesis is primary aplasia or lack of development of the muscles leading to atrophy of the nerve. Also in doubt is the role that heredity plays. While many feel heredity plays no role, there have been reports of a small number of cases occurring in families indicating a possible hereditary tendency.

The diagnosis of Möbius syndrome is not always made in the newborn nursery and is often not recognized as Möbius syndrome for several months. The parents usually show the most concern over the mask-like facies which is due to the paralysis of the facial nerve. The sixth nerve paralysis becomes obvious when the child follows objects by turning his head from side to side. The child may experience eating problems when food becomes lodged in the cheeks requiring manual removal. However, in the congenital form of facial paralysis, functional problems are often not as significant as might be expected. Corneal protection which is related to the ability to close the eyes is usually adequate with problems related to corneal exposure uncommon. It is the lack of facial expression or inability to smile that poses the major problem. This can severely inhibit psychosocial development as the child approaches school age and thus becomes aware that they are different. We feel this obstacle to interpersonal relationships and social development should play a role in the timing of surgical intervention.

The timing of recommended surgical correction is of course influenced by the age of the patient at referral. Ideally, one would want to evaluate Möbius syndrome patients as infants. Due to the psychosocial problems that can result from bilateral facial paralysis, we recommend early surgical intervention if possible. It

is preferable to have the child's reconstruction complete before he starts school. This would mean starting the reconstruction at four to five years of age. However, the age of the patient does not effect the operative outcome; successful reconstruction can be performed in adults as well.

The treatment of patients with Möbius syndrome is directed toward restoration of facial motion. Acquired facial paralysis differs from the congenital type found in Möbius syndrome, and its treatment will not be discussed in this article. In the congenital cases, corneal exposure is seldom a problem and therefore does not require surgical treatment. However, in acquired cases eye problems are frequent and generally require surgical intervention. In bilateral congenital facial paralysis the major goal is to restore motion in the appropriate direction to the upper lip and commissure. In unilateral cases, a nerve graft from the functioning facial nerve to the effected side can be performed. However, in bilateral cases such as Möbius syndrome, there is no functioning facial nerve available. The surgical options in these cases are a local muscle transfer procedure or free muscle transplantation. Local regional muscles such as the temporalis or masseter can be used to restore facial movement. Either of these muscles of mastication can be moved maintaining their innervation to restore movement of the upper lip and commissure. Retraining and practice is necessary to get the maximum benefit.

A newer procedure is microvascular muscle transplantation. This involves mov-

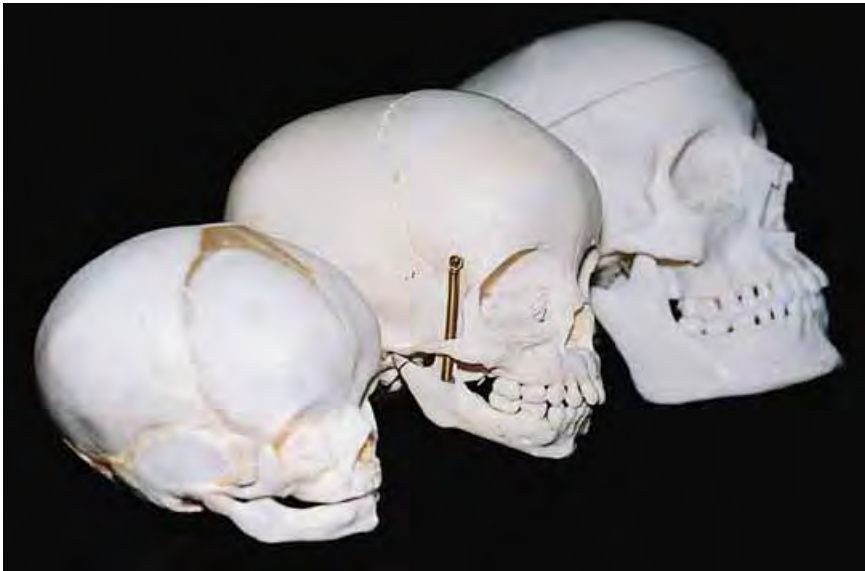ing a muscle from another part of the body along with its nerve and blood supply. The nerve and vessels to the muscle are reconnected with the aid of a microscope. The muscle is oriented in such a fashion to provide motion to the upper lip and commissure.

In each of these procedures the family needs to have realistic expectations of what can be accomplished. If successful, these procedures can provide tone to the upper lip and commissure at rest, with muscle action that can produce a smile. Fine movements or variation in expression are usually not possible. However, these procedures can make dramatic improvements in the mask-like facies of Möbius syndrome. They provide the potential benefits of facial animation with improved social interaction.

SUMMARY

CRANIOFACIAL SURGERY encompasses the reconstruction of a broad spectrum of facial deformities. This field is in its infancy and continues to develop and grow rapidly. The functions of a craniofacial center have been described and a variety of examples used to demonstrate the type of reconstructive procedures routinely performed at our center. This book is not meant to be comprehensive in describing the multitude of craniofacial deformities that occur or every surgical option available. We have described the more common deformities and syndromes with our current approach to treatment. However, it is important to remember that treatment plans vary and must be individualized for each patient depending on the type and severity of the particular deformities present. We feel this customized approach is a crucial step in obtaining the best results possible.

Such centers offer great potential and hope to many deformed patients. We feel that providing informative material about the treatment of these disorders results in better patient education and ultimately better care. We hope this book has answered many of the questions asked by both health professionals and parents concerning the evaluation and treatment of craniofacial deformities.



T. C. THOMPSON CHILDREN'S HOSPITAL

T. C. Thompson Children's Hospital is a full service teaching hospital affiliated with the University of Tennessee College of Medicine. It provides the most comprehensive pediatric care available, featuring the state's only Level I Pediatric Trauma Center, one of five Perinatal Centers of Excellence, and a Level III Neonatal Intensive Care Unit. State of the art facilities are available to meet the special needs of children. Additional subspecialties include cardiology, neurophysiology, genetics, physical therapy, allergy/immunology, endocrinology, hematology, oncology, infectious disease, neonatology, neurology, nephrology, gastroenterology, pulmonology, pediatric intensive care, pediatric surgery, and pediatric anesthesiology.

CRANIOFACIAL FOUNDATION OF AMERICA

The Craniofacial Foundation of America (CFA) is a non-profit organization dedicated to helping people with facial deformities lead normal lives. Established in 1989, the CFA provides support for the Tennessee Craniofacial Center.

The foundation provides financial assistance for food, travel, and lodging expenses to qualified families traveling to the Tennessee Craniofacial Center for evaluation and treatment. It also provides networking opportunities for craniofacial patients and their families for the rights of those with facial disfigurement, and as a source for educational material on craniofacial anomalies.

For information, call **(423)778-9192** or **(800)418-3223**

ABOUT THE ERLANGER HEALTH SYSTEM

Erlanger Health System is owned and operated by the Chattanooga-Hamilton County Hospital Authority and governed by its 11-person Board of Trustees. Today, Erlanger is the only comprehensive health system in the region, recognized as providing the highest quality of care with a commitment to the communities it serves.

Erlanger features:

- Erlanger Medical Center, the oldest, largest and most comprehensive hospital in the region.
- T. C. Thompson Children's Hospital, the only healthcare facility dedicated to complete care for children in the region.
- Erlanger North, a 57-bed community hospital located in Red Bank; and Erlanger East, a state-of-the-art ambulatory care center.
- The James L. Fowle Regional Cancer Center.
- The Regional Kidney Transplant Center, the region's only organ transplant program.
- The Regional Trauma Center, the region's only Level I trauma center.
- LIFE FORCE, the region's only air ambulance program.
- The Willie E. Miller Eye Center, the first hospital in Tennessee dedicated solely to eye care.
- The Regional Heart Center, site of the first open-heart surgery ever performed in Chattanooga.
- The region's only Level III Neonatal Intensive Care Unit.
- The Chattanooga Unit of the University of Tennessee College of Medicine, training the next generation of physicians.
- The Erlanger Community Partnership, a philanthropic program aimed at meeting needs in the community served by Erlanger Health System.
- Membership in the Galaxy Health Alliance, a partnership of hospitals aimed at reducing healthcare costs.
- LifeForce Health Plans, an affiliate of Cariten Healthcare, a provider-owned insurance company.

For answers to health questions or for help in locating an Erlanger physician, call **The Professionals**, 24 hours a day, at **778-8181** or **1-800-333-8181**.